

RESULTS OF ULNAR NERVE NEUROTIZATION TO BICEPS BRACHII MUSCLE IN BRACHIAL PLEXUS INJURY

MARCELO ROSA DE REZENDE, NEYLOR TEOFILO ARAÚJO RABELO, CLÓVIS CASTANHO SILVEIRA JÚNIOR, PEDRO ARAÚJO PETERSEN, EMYGDIO JOSÉ LEOMIL DE PAULA, RAMES MATTAR JÚNIOR

ABSTRACT

Objective: To evaluate the factors influencing the results of ulnar nerve neurotization at the motor branch of the brachii biceps muscle, aiming at the restoration of elbow flexion in patients with brachial plexus injury. **Methods:** 19 patients, with 18 men and 1 woman, mean age 28.7 years. Eight patients had injury to roots C5-C6 and 11, to roots C5-C6-C7. The average time interval between injury and surgery was 7.5 months. Four patients had cervical fractures associated with brachial plexus injury. The postoperative follow-up was 15.7 months. **Results:** Eight patients recovered elbow flexion strength MRC grade 4; two, MRC grade 3 and nine, MRC <3. There was no

impairment of the previous ulnar nerve function. **Conclusion:** The surgical results of ulnar nerve neurotization at the motor branch of brachii biceps muscle are dependent on the interval between brachial plexus injury and surgical treatment, the presence of associated fractures of the cervical spine and occipital condyle, residual function of the C8-T1 roots after the injury and the involvement of the C7 root. Signs of reinnervation manifested up to 3 months after surgery showed better results in the long term. **Level of Evidence: IV, Case Series.**

Keywords: Brachial plexus/injuries. Elbow/injuries. Nerve transfer. Ulnar nerve.

Citation: Rezende MR, Rabelo NTA, Silveira Júnior CC, Petersen PA, De Paula E JL, Mattar Júnior R. Results of ulnar nerve neurotization to biceps brachii muscle in brachial plexus injury. *Acta Ortop Bras.* [online]. 2012;20(6):317-323. Available from URL: <http://www.scielo.br/aob>.

INTRODUCTION

The anatomy of the brachial plexus (BP) is characterized by an area lacking in muscle or bone protection, besides being related to areas of considerable mobility such as the cervical and scapulohumeral region that make it susceptible to direct trauma (perforating) injuries as well as traction injuries, and can lead to severe functional losses of the upper limb.¹ Although less frequent than cranioencephalic traumas and spinal cord traumas, BP injuries are of considerable socioeconomic importance as they generally affect young patients who have their work capacity greatly impaired by the injury sequelae.

Accurate statistical data on BP injuries are scarce in the literature. In the United States the estimated incidence of this condition is 3.9 cases per 100,000 inhabitants/year. In Brazil, in an epidemiological study carried out at a referral hospital from the Federal District between May 2004 and 2005, it was possible to estimate an incidence of 1.75 cases per 100,000 inhabitants/year.¹

According to some authors, the first goal to be achieved in the treatment of BP injuries is to reestablish active elbow flexion.² Among the various surgical possibilities, neurological procedures should be prioritized. Repairs using grafts are only possible in postganglionic injuries, while nerve transfers (neurotizations) are indicated in preganglionic injuries. In this context, Oberlin et al.³ describe the use of ulnar nerve fascicles to reinnervate the biceps brachii in high BP injuries with avulsion of the roots of C5 and C6 and preservation of the more distal roots.

Our goal is to carry out a critical evaluation of the results obtained in 19 patients with high injuries of the brachial plexus submitted to the Oberlin procedure at our institution between February 2003 and May 2007; comparing them with the correlated studies available in the literature; and based on this analysis, to define the importance of predictive factors such as age, interval between trauma and surgery, injury level and associated injuries.

All the authors declare that there is no potential conflict of interest referring to this article.

Institute of Orthopedics and Traumatology of Hospital das Clínicas of the School of Medicine of Universidade de São Paulo.

Study conducted at LIM 41 – Laboratory of Medical Investigation of the Musculoskeletal System of the Department of Orthopedics and Traumatology of the School of Medicine of Universidade de São Paulo.

Mailing address: Rua Barata Ribeiro, 237, cj. 13/14, São Paulo, SP, Brazil. CEP. 01308-000. Email: marcelo@marcelorosaderezenende.com.br

Article received on 2/6/2011 and approved on 4/11/2012.

Acta Ortop Bras. 2012;20(6): 317-23

MATERIAL AND METHOD

A methodology similar to that applied by Merrel et al.⁴ was adopted in this study, comparing the results of the analysis of an own clinical series with the results of similar studies from the pertinent literature (meta-analysis).

Inclusion Criteria

All the patients with high traumatic injuries of the brachial plexus; with injury levels C5-C6 and C5-C6-C7; over 15 years of age; who had been submitted to the Oberlin procedure associated or not associated with concomitant procedures of the brachial plexus (reconstructions with graft, intraplexual or extraplexual neurotizations such as: accessory nerve to suprascapular nerve, triceps motor branch to axillary nerve) and with minimum postoperative follow-up of six months, were included in the study.

Exclusion Criteria

All the cases of obstetric paralysis, traumatic injuries in pediatric patients; ulnar nerve neurotizations for free muscle transfers and double neurotization to the elbow flexors (fascicles of the ulnar and median nerves) were excluded from the study.

Casuistry

Between February 2003 and May 2007, 19 patients (18 men and one woman) with average age of 28.7 (20 - 45) years underwent surgery. Eight patients presented injuries in C5-C6 and 11 in C5-C6-C7. The function of the flexors of the wrist and fingers in the preoperative period was assessed by the grading system of the British Medical Research Council (MRC): 1 case M2, 5 cases M3, and 13 cases M4. Eleven patients were victims of motorcycle accidents, five of whom presented fractures adjacent to the injured brachial plexus. The average time between the injury and the surgical procedure was 7.5(1-18) months. Concomitant procedures were executed in twelve patients: nine neurotizations of the accessory nerve to suprascapular nerve, two neurotizations of a triceps motor branch to the axillary nerve, two neurolyses and two upper trunk reconstructions with sural nerve graft. (Table 1)

Surgical Technique

A midline incision of approximately 10cm is made on the medial surface of the arm, where the incision midpoint is approximately 12cm from the acromion. The space between the biceps brachii and coracobrachialis muscles is explored and the motor branch(es) to the biceps, originating from the musculocutaneous (MC) nerve, are identified. Then the ulnar nerve is identified posterior to the medial intermuscular septum, and a 6cm-incision is made in the anterolateral aspect of its epineurium. Using the nerve stimulator, an attempt is made to identify motor fascicles to the extrinsic flexor muscles. One or two motor fascicles are then sectioned. This is followed by termino-terminal neurorrhaphy of the ulnar nerve fascicles with the motor branch(es) using three stitches of mono nylon 9.0 reinforced with fibrin glue. (Figure 1)

The patient's upper limb remains immobilized in a Velpeau sling for three weeks.

Review of Literature

Medical research sites (*Medline, PubMed, Medscape and Cochrane*) served as a reference source. Cross referencing was

Table 1. Relation of patients, age, associated adjacent fractures, level of injury, function of the extrinsic flexors in the preoperative period by the grading system of the British Medical Research System (MRC), time interval between the accident and the surgical treatment (ITAC) and concomitant procedures.

Patient	Age years	Adjacent Fractures	Level of Injury	Function C8-T1	IAST (months)	Concomitant Procedures
1	25	-	C5-C6	M4	10	Ac>Sup
2	24	-	C5-C6	M4	6	Nrl; Ac>Sup; TMB>Ax
3	27	-	C5-C6-C7	M4	8	No
4	20	Fr. ptC7	C5-C6C7	M3	10	Ac>Sup
5	37	Fr. pt C6 C7	C5-C6-C7	M3	7	Ac>Sup
6	43	Fr. ptC4-C7 and Clavicle	C5-C7-C7	M2	1	No
7	25	Fr. pt C7 and Occiput	C5-C6-C7	M3	3	Ac>Sup
8	21	Fr. Humerus and Clavicle	C5-C6-C7	M4	5	Nrl
9	26	-	C5-C6-C7	M4	7	REUT
10	27	-	C5-C6-C7	M4	8	No
11	30	-	C5-C6	M3	18	No
12	45	-	C5-C6-C7	M3	10	Ac>Sup
13	21	-	C5-C6	M4	4	Ac>Sup
14	33	-	C5-C6	M5	6	REUT
15	43	-	C5-C6	M4	9	No
16	25	-	C5-C6-C7	M4	12	Ac>Sup
17	27	-	C5-C6	M4	5	Ac>Sup; TMB>Ax
18	25	-	C5-C6	M4	5	Ac>Sup
19	22	-	C5-C6	M4	9	Ac>Sup

Fr.: fracture; pt Cx: transverse process of cervical spine; Nrl: neurolysis; Ac>Sup: neurotization of the accessory nerve to suprascapular nerve; TMB>Ax: neurotization of triceps motor branch to the axillary nerve; REUT: reconstruction of the upper trunk with graft.

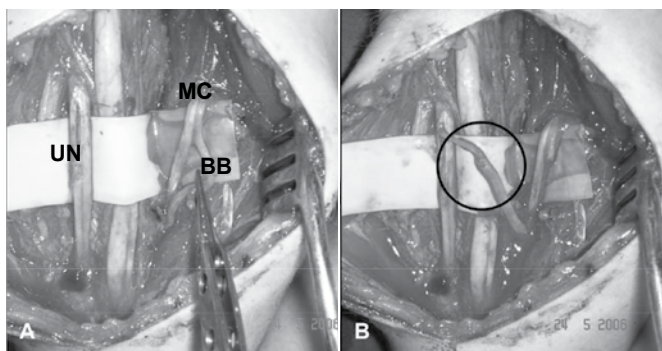


Figure 1. (A) Exposure of the ulnar (UN) and musculocutaneous (MC) nerves and the biceps motor branch (BB). (B) Termino-terminal neurorrhaphy of an ulnar nerve fascicle to the biceps motor branch (highlighted).

performed to obtain the most complete listing possible of clinical series with the application of the ulnar nerve neurotization technique to reinnervate the biceps brachii. Fifteen⁵⁻¹⁸ articles were found, of which six were subsequently disregarded. (Tables 2 and 3) To facilitate the collection and handling of data, the articles were organized in chronological order and numbered with Roman numerals.

Epidemiological data (sex, age bracket, mechanism of injury, associated injuries); injury level; preoperative function of the flexors of the wrist and fingers; time interval between injury and surgery; concomitant procedures of the brachial plexus; postoperative follow-up time, chronology of signs of biceps reinnervation; recovery of elbow flexion (Grading System of the Medical Research Council- MRC), and complications were all evaluated.

Table 2. Reports of clinical series with application of the Oberlin technique.

	Author (year)	Patients M W	Age/years (Min-Max) Mean	IAST/month (Min-Max) Mean	Other Concomitant Neurotizations	Follow-up (months)	Strength MRC ≥ 3 (%)	Strength MRC ≥ 4(%)
I	Oberlin et al. ³ (1994)	4 3 1	(18- 29) 23.5	(4-6) 4.6	Yes (1 case)	(9 - 24) 14.2	100%	75%
II	Loy et al. ⁵ (1997)	18 15 3	(17 - 41) 25.8	(4 -72) 17	Yes (10 cases)	(6 -48) 21	66%	61%
III	Franciosi et al. ⁶ (1998)	5 5 0	(19 -45) 26	(2 - 13) 6.8	Yes (5 cases)	(6 -12) 8.6	80%	80%
IV	Leechavenvongs et al. ⁷ (1998)	32 31 1	(19 - 46) 28	(3 - 12) 6	Yes (27 cases)	(11 - 40) 18	96%	93%
V	Sungpet et al. ⁸ (2000)	36 33 3	(16 - 42) 25	(3 - 8) 5	Not mentioned	(-) 22	94.4%	83.3%
VI	Bertelli and Ghizone ⁹ (2004)	10 10 0	(19 -32) 28	(5 - 7) ...	Yes (10 cases)	(-) 24	100%	100%
VII	Ferrarezi et al. ¹⁰ (2004)	39(+4) - -	Not mentioned	(2 -12) ...	Not mentioned	(7 - 84) -	88.3%	86%
VIII	Teboul et al. ¹¹ (2004)	32 27 5	(15 - 66) 28.1	(1.5 -75) 9	Yes (12 cases)	(9 - 74) 31	75%	62.5%
IX	Shahriar-Kamrani et al. ¹² (2005)	6(+3) 5 1	(18 - 47) 27.3	(5 - 12) 6.8	Yes	(6 - 15)	66.6%	50%

IAST: Interval between the accident and surgical treatment. M: Men. W: Women.

Table 3. Articles with the Oberlin technique, excluded from the study.

Author (year)	Reason for Exclusion
Al-Qattan et al. ¹³ (2002)	Application in obstetric paralysis.
Tung et al. ¹⁴ (2003)	Case series with double neurotization to reestablish elbow flexion.
Noaman et al. ¹⁵ (2004)	Application in obstetric paralysis.
Bhandari et al. ¹⁶ (2005)	Case series with diversified techniques; Shortage of data on patients submitted to the Oberlin procedure.
Shigmatsu et al. ¹⁷ (2006)	Application in obstetric paralysis.
Hierner and Berger ¹⁸ (2006)	Case series with diversified techniques; Shortage of data on patients submitted to the Oberlin procedure.

Table 4. Relation of postoperative follow-up and results of elbow flexion strength.

Patient	Follow-up months/MRC Grade of elbow flexion strength								
	3	6	9	12	18	24	36	48	60
1	M1	M3	-	-	-	M3	-	-	-
2	M1	M4	-	-	-	-	-	-	-
3	M1	M2	-	-	-	-	-	-	-
4	M0	M1	M1	-	-	-	-	-	-
5	M1	M1	-	-	-	-	-	-	-
6	M1	M1	-	-	M2	-	-	-	-
7	M0	-	-	-	-	M2	-	-	-
8	M3	M4	-	M4	-	-	-	-	-
9	-	M1	M1	-	-	-	-	-	-
10	M1	M2	-	M4	M4	-	-	-	-
11	M0	-	M2	-	-	-	-	-	M2
12	M0	M2/3	-	-	-	M3	-	-	-
13	M2	M3	-	M4	-	-	-	-	-
14	M0	M1	-	-	-	-	-	-	-
15	M2	-	M4	-	-	-	-	-	-
16	M0	M0	-	M1	-	-	-	-	-
17	M1	M3	M4	M4	-	-	-	-	-
18	M2	M3	-	-	-	M4	-	-	-
19	M0	M2	-	-	M4	-	-	-	-

RESULTS

The mean postoperative follow-up time was 15.7 (6-60) months. Eight patients recovered elbow flexion strength MRC grade M4; two patients, grade M3 and nine patients grade <M3. (Table 4) The first signs of active contraction appeared between two and six months. No patient had impairment of ulnar nerve function in the postoperative period.

The results obtained in elbow flexion, graded by the MRC, are correlated to the variables: age, interval between injury and surgical treatment, injury level, function of roots C8-T1 and association with fractures adjacent to the injured brachial plexus, and are represented in Figures 2 to 6.

We compared the end results of elbow flexion strength with the manifestation times of the first clinical signs of reinnervation of the biceps brachii in the postoperative period. (Figure 7) All the articles evaluated have the use of the ulnar nerve as

a donor for reinnervation of the biceps brachii as a technical principle.

There was considerable variation in the methodology of the studies and in the presentation of results.

Article IX¹² presented nine cases; however, three of these were disregarded as they involved the use of ulnar nerve fascicles for neurotization of the free gracilis muscle. Of the 43 cases in article VII,¹⁰ four used the median nerve as a donor, and were also excluded from the study.

According to the clearness and objectivity of the data provided, these were either put to use or discarded.

The compilation of the data obtained leads to the following results:

- 182 patients were assessed.
- One hundred forty-three had their sex specified by the authors, of these 92% were men.

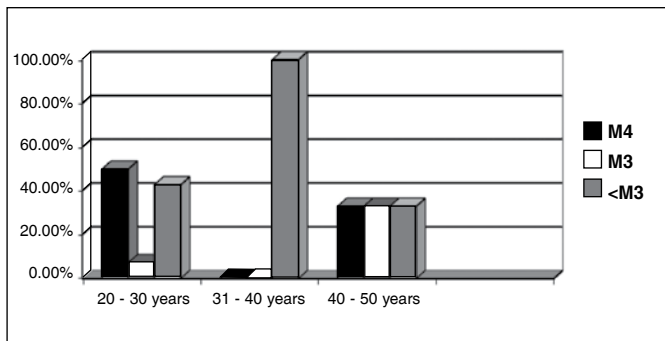


Figure 2. Correlation of the age bracket with the results of elbow flexion strength by the MRC Grading System.

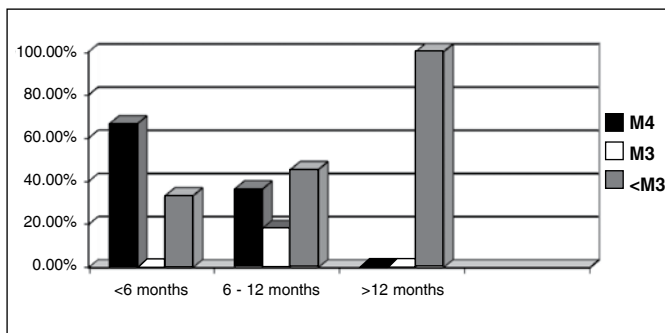


Figure 3. Correlation of the time interval between the injury and surgical treatment with the results of elbow flexion strength by the MRC Grading System.

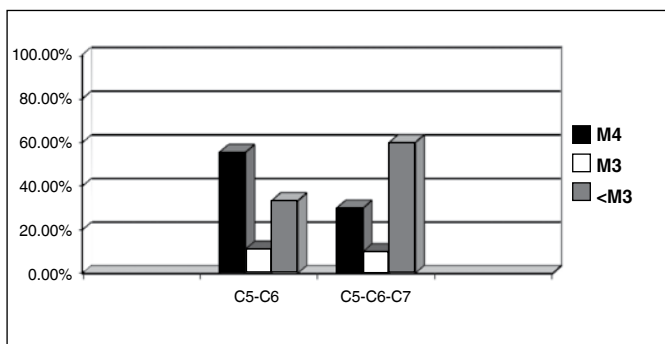


Figure 4. Correlation between the injury level with the results of elbow flexion strength by the MRC Grading System.

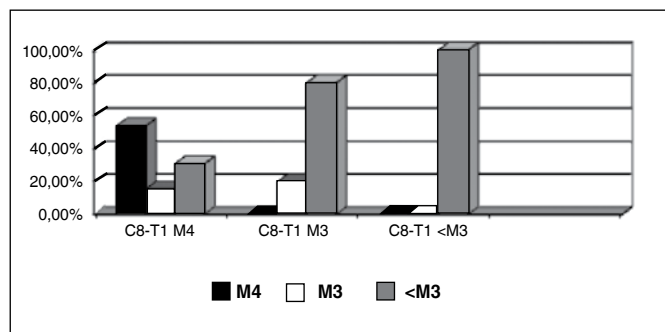


Figure 5. Correlation between the grade of strength of the extrinsic flexors of the fingers and wrist (C8-T1) by the MRC system in the preoperative period with the results of elbow flexion strength by the MRC Grading System.

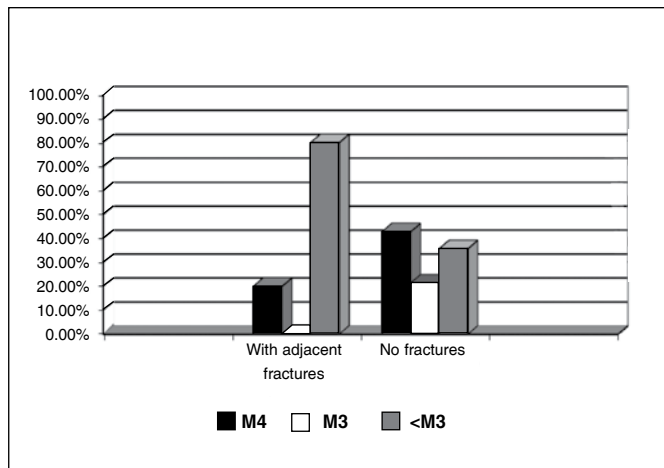


Figure 6. Correlation between the presence of adjacent fractures (cervical spine, humerus and clavicle) associated with the BP injury and the results of elbow flexion strength by the MRC Grading System.

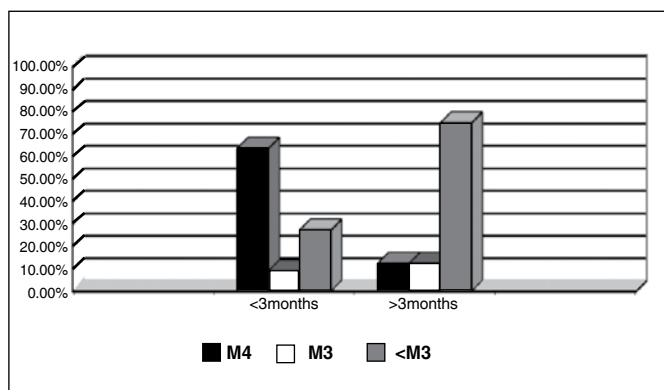


Figure 7. Correlation between the initial signs of reinnervation of the biceps brachii, in the postoperative period, and the results of elbow flexion strength by the MRC Grading System.

- The estimated average age was 26 years, ranging between 15 and 66 years.
- The etiology of the injuries receives little attention in these reports; but when mentioned, motorcycle accidents are highlighted.
- Associated traumatisms are neither specified nor valued.
- One hundred twenty-five patients presented deficit of C5-C6 and 57, deficit of C5-C6-C7.
- The function of the extrinsic flexors in the preoperative period was evaluated in Articles IV, V, VI, VII and VIII.
- The estimated mean time interval between accident and surgery was 7.3 months.
- Sixty-six patients were submitted to concomitant procedures: intraplexual and extraplexual neurotizations (accessory nerve to suprascapular nerve, triceps motor branch to axillary nerve)
- The postoperative follow-up period ranged from 6 to 84 months, averaging 20 months.
- Clinical signs of reinnervation (MRC grade M1 contraction) appeared between two and six months.
- The end result obtained for elbow flexion strength was MRC grade \geq M3 in 85.2 % and grade \geq M4 in 75.3 % of the patients.

- There is a consensus regarding low morbidity for the ulnar nerve with gradual improvement of hand sensitivity and increase in grip strength in the postoperative period in all the articles. The results obtained in elbow flexion strength, graded by the MRC, are correlated to the variables: injury level, interval between trauma and surgery and age bracket; and are represented in the graphs from Figures 8, 9 and 10 respectively.

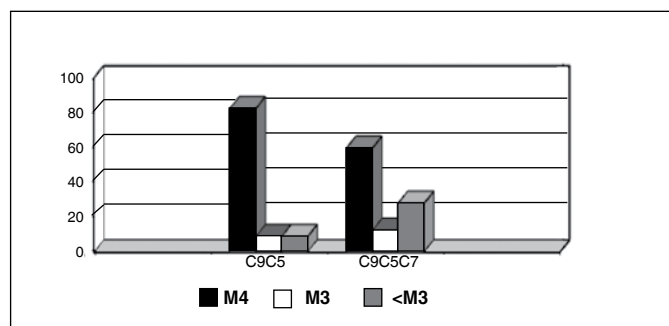


Figure 8. Relation between the injury level and the MRC grade of strength of the biceps brachii. Considering 182 cases from the literature.

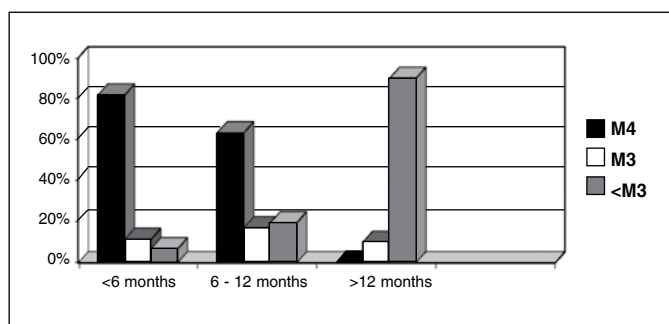


Figure 9. Relation of the time interval between the BP trauma and surgical treatment with the MRC grade of strength of the biceps brachii. Considering 95 cases (Articles I [partial], II, III, IV, VIII and IX) from the literature.

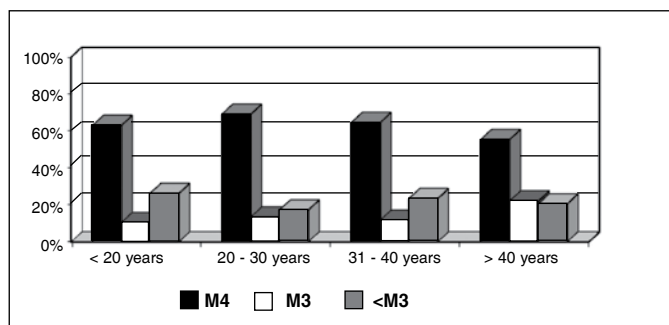


Figure 10. Relation between age bracket and the MRC grade of strength of the biceps brachii. Considering 97 cases (Articles I, II, III, IV, VIII and IX) from the literature.

DISCUSSION

As advocated by Hentz and Doi,² reestablishing active elbow flexion in brachial plexus injuries is a priority. Several surgical approaches are described to achieve such an objective: repair of the upper trunk with nerve grafts in postganglionic injuries; muscle transfers, intra- and extraplexual neurotizations in pre-ganglionic injuries.

Nerve grafts are not possible in preganglionic injuries. Under these circumstances the options are intraplexual neurotizations using remaining roots for reconstruction of the upper trunk; or extraplexual neurotizations with accessory nerve, intercostal nerves, phrenic nerve, hypoglossal nerve, nerve to the pectoralis minor and ulnar nerve.

In our casuistry, with the Oberlin procedure, we managed to reestablish active elbow flexion MRC Grade ≥ 3 in 52.6% of the cases and ≥ 4 in 42.1% of the cases. Our results are similar to those published by Loy et al.⁵ and Shahnriar-Kamrani et al.¹², but much lower than those of other authors such as Leechavervongs et al.,⁷ Sungpet et al.⁸ and Bertelli and Ghizone.⁹ Such diverse results are justified by the presence of multiple variables that, acting separately or in association, interfere in the prognosis of the primary injury.

Eleven of our patients presented C5-C6-C7 and eight, C5-C6 injuries. The former evolved with worse results. We can affirm that the involvement of root C7 was a negative factor in our series. The relation between the C7 injury and inferior results after ulnar nerve neurotiziation is shared by most authors. In the clinical series that present the best results there is a clear predominance of C5-C6 injuries with preserved function of C7.^{3,7-10} Of 182 patients described in the literature, 125 presented C5-C6 injury and 57, C5-C6-C7 injury; and they evolved with elbow flexion MRC grade ≥ 4 in 82.4% and 59.6% respectively. Ferraresi et al.¹⁰ is the only author who disagrees with such a relation; of his five cases with C5-C6-C7 injury, these all evolved with grade 4 elbow flexion. On the other hand, this author values the evaluation of flexion strength of the fingers and fist in the preoperative period as a prognosis indicator.

In our study, the strength of the flexors of the wrist and fingers at MRC grade ≥ 3 after the initial trauma influenced the end results. Under these circumstances, there was no effective recovery of elbow flexion in any patient.

Hentz and Doi² mention that the typical patient with traumatic brachial plexus injury is the young man involved in a motorcycle accident. Under these circumstances, patients often present associated cranioencephalic or thoracic trauma and fractures of the shoulder girdle and cervical spine. In our study, 63% of the injuries were caused by motorcycle accidents; three patients presented fracture of transverse processes of cervical vertebrae and 1, fracture of the occipital condyle. These four patients presented frustrating results in terms of elbow flexion recovery. We noticed that the presence of such injuries associated with brachial plexus trauma can interfere negatively in the results of the Oberlin procedure. This correlation is not mentioned in the literature evaluated.

In our casuistry only three patients (15.7%) were over 40 years of age, averaging 28.7 years. In the literature, of 95 patients, nine (9.3%) were over 40 years of age and the average age was 26 years. As it affects a predominantly young portion of the population, from the 2nd to the 4th decade of life, and without associated degenerative systemic diseases, there was no interference of age in the results in our series and in the literature.⁵⁻¹² The time interval between injury and surgical treatment interferes significantly in the results. In our patients, we obtained elbow flexion MRC grade 4 in 66.5% of the patients operated up to six months after the trauma, 27.2% between six and 12 months and 0% after 12 months. In the literature, 81.8% achieved

elbow flexion MRC grade 4 when operated up to six months after the injury, dropping to 63.4% between six and 12 months and 0% after 12 months. According to our data and that of the literature,^{5,6,11} the Oberlin procedure is ineffective more than 12 months after trauma.

The surgical technique adopted by us was the same originally described by Oberlin: one or two ulnar nerve fascicles (10%) were used with termino-terminal neuroorrhaphy to the biceps motor branches. But some modifications were described. Franciosi et al.⁶ sectioned the musculocutaneous nerve when this emerged from the lateral cord and applied a termino-lateral neuroorrhaphy to the ulnar nerve after the opening of an epineural window. This modification involves a more aggressive proximal dissection with the need for tenotomy of the pectoralis major to find the origin of the MC nerve. Ferraresi et al.,¹⁰ in several cases from his series, also used the entire musculocutaneous nerve and was slightly more aggressive in the harvesting of ulnar nerve branches, using up to 1/5 of the nerve section area. Teboul et al.¹¹ used up to three ulnar nerve fascicles in three patients. Sungpet et al.,⁸ on the other hand, used only a single fascicle for transfer in his study.

The fascicular topography of the peripheral nerves along their course creates controversy regarding the mode of selection of the fascicles for transfer. We used the nerve stimulator with the intention of identifying the motor fascicles to extrinsic flexors, especially to the FCU. However, in our series we were able to identify a considerable variation of motor responses within a continuous spectrum: at one end, patients whose fascicles when stimulated contracted well-defined muscles and, at the other end, those in whom the stimuli were inconclusive with diffuse contractions of intrinsic and extrinsic muscles. Under the latter circumstance the selection becomes randomized.

According to Jobe and Wright,¹⁹ the fascicles of the radial, median and ulnar nerves are arranged as a complex network of branched fascicles that are constantly interspersed along the nerve, yet their distal portions can be dissected over long courses without presenting anastomoses. Oberlin himself, justifying the randomized use of fascicles in his initial study, declares that at arm level, the ulnar nerve fascicles are mixed (with sensory and motor fibers).³ Osman et al.,²⁰ in a histomorphometric study of the ulnar nerve and its branches, concluded that the ulnar nerve has 52% and 48% of sensory and motor fibers respectively; and that fascicles to the motor branch of the flexor digitorum profundus (FDP) muscle, represent 9.5% of the section area of the ulnar nerve, for which reason it is a good option for transfer and neurotization of the motor branch of the biceps brachii. Sungpet et al.⁸ and Ferraresi et al.,¹⁰ using a nerve stimulator, seek to select motor fascicles for the flexor carpi ulnaris (FCU) muscle. Bertelli and Ghizoni;⁹ Teboul et al.¹¹ and Shahriar-Kamrani et al.¹² use the nerve stimulator to select motor fascicles of any extrinsic flexor in order to preserve the innervation of the intrinsic muscles of the hand. Despite technical variations in the selection of the fascicles, the functional results and, especially, the absence of ulnar nerve deficit, are similar among authors.

It can be stated that the fascicular definition of the ulnar nerve along its course in the arm should present a major variation among individuals; some having clearly differentiated motor and sensory fascicles at this level and others presenting this

definition in more distal segments. We noticed that the nerve stimulator should be used at all times, but by means of inconclusive motor responses we should not penalize those that proceed in a random manner, in the selection of the fascicles; since the mode of selection of the fascicles does not change the results. In patients with well-defined fascicles and with C7 deficit, preserving the branches to the FCU can be useful, targeting a future tendon transfer to reestablish the active extension of the fingers.

In our series, the first signs of reinnervation appeared between two and six months. We observed in our patients that the early appearance of the reinnervation signs is also correlated with the final recovery of elbow flexion strength; patients who presented biceps contraction with MRC grade ≥ 1 strength up to three months after surgery had the best long-term results. In the literature the first signs of reinnervation also appeared between two and six months after surgery, but the various authors cited did not correlate the early appearance of the contractions with the end results.

Frey states that the results of a neurotization distal to the brachial plexus are superior to those obtained by a proximal reconstruction, since the latter will prolong the reinnervation period and result in greater muscle atrophy.²¹ The proximity of the ulnar nerve to the endplate of the biceps explains the early appearance of the reinnervation signs after the Oberlin procedure. Such proximity also ensures a tension-free neuroorrhaphy, which eliminates the need for grafts. In 2001, Merrel et al.,⁴ in a meta-analysis of the literature in English, evaluate the results of 1088 neurotizations in 27 articles selected to determine the results on elbow and shoulder function. In relation to the restoration of elbow flexion, 26 studies with 965 neurotizations were analyzed. All told, 71% of the neurotizations for the musculocutaneous nerve achieved the result M3 (Medical Research Council Grading Scale) and 37% were equal to or higher than grade M4. The use of the intercostal nerves (54%) attained strength $\geq M3$ in 72% of the cases; when the spinal accessory nerve was transferred (39%) the strength was $\geq M3$ in 77% of the cases. However when the neurotization of these two nerves was performed without the use of grafts, strength M4 was achieved respectively in 41% and 29% for intercostal and spinal accessory nerves. The use of the ulnar nerve spares the accessory nerve for a neurotization of the suprascapular nerve, with the objective of stabilizing the shoulder; the same applies to the preservation of the medial pectoral nerve that innervates the pectoralis major necessary in the maintenance of thoracobrachial pinch.

In our service we apply the Oberlin technique in high injuries of the brachial plexus affecting C5-C6 and C5-C6-C7. Initially indicated in traumatic avulsions of C5-C6, the Oberlin technique was naturally extended to C5-C6-C7 avulsions and, more recently, has been applied under new circumstances such as obstetric paralysis^{13,15,17} and reinnervation of free muscle transfers.^{12,21,22} Since it presents a more predictable recovery, we also indicate the procedure in postganglionic injuries associated with the reconstruction of the upper trunks with graft; this conduct is also defended by Teboul et al.¹¹ and Shahriar-Kamrani et al.¹²

Narakas and Hents²³ recommend neurotizations to muscle transfers in early injuries, an opinion shared by Brandt and Ma-

chinon.²⁴ Muscle transfers are a good option for late injuries in which the endplates of the elbow flexors have already degenerated and will not respond satisfactorily to neurotization; or as a salvation procedure for previous failed neurotizations. Marshall et al.,²⁵ in a review of muscle transfers for restoration of elbow flexion, concluded that the best procedures were transfer of the latissimus dorsi and triceps, but that the results obtained by the Steindler procedure are also satisfactory. According to this author his best results were obtained in a patient who presented some degree of recovery of biceps contraction.

Nowadays we indicate Steindler flexorplasty as a secondary procedure in the restoration of functional elbow flexion in cases in which the Oberlin procedure has proven insufficient. This conduct was defended by Loy et al.⁵ and, more recently, by Teboul et al.¹¹; the latter recommends the procedure at least 12 months after neurotization.

Summarizing our results and the analysis of literature, it is possible to identify predictive factors. In the preoperative period, and in order of importance, there are: the interval elapsed between the plexus injury and surgical treatment; the presence of associated fractures of the cervical spine and occipital condyle; the residual function of the roots of C8-T1 after the trauma and the involvement of the root of C7. In the postoperative period, reinnervation signs should appear within up to three months, otherwise less favorable results are to be expected. Accordingly, patients with involvement of the root of C7; who have an important reduction of strength of the extrinsic flexors innervated by the ulnar nerve; and who were operated after six months of evolution, will probably not have functional elbow

flexion. Late surgeries, more than 12 months, are predestined for failure. Of our patients operated before six months after the injury, two presented fractures of transverse processes of the cervical vertebrae, ipsilateral to the injured plexus; if disregarded, the success rate that we achieved in this group reaches 100% for recovery of elbow flexion MRC grade 4. As concerns the last prognostic factor, our casuistry is not significant and future studies are necessary.

CONCLUSION

Based on the systematic review of literature it can be noted that the results obtained by the Oberlin technique are very variable and not always good. However, based on the critical evaluation of the series of 19 cases of brachial plexus reconstruction operated in the IOT, and on the analysis of the literature, using the Oberlin technique, its low morbidity showed it to be a good option for restoration of active elbow flexion in high injuries of the brachial plexus, both pre- and postganglionic. It was observed that results of the neurotization surgery of the ulnar to the musculocutaneous nerve are dependent: on the interval elapsed between the plexus injury and the surgical treatment, on the presence of associated fractures of the cervical spine and of the occipital condyle, on the residual function of the roots of C8-T1 after the trauma and on the involvement of the root of C7. Reinnervation signs manifested up to three months in the postoperative period show better long-term results. Unfavorable results can be improved afterwards with muscle transfers, especially the Steindler procedure. Paying attention to the predictive factors can create more realistic expectations.

REFERENCES

- Flores LP. [Epidemiological study of the traumatic brachial plexus injuries in adults]. *Arq Neuropsiquiatr*. 2006;64(1):88-94.
- Hentz VR, Dóí K. Traumatic brachial plexus injury. In: Green D, Hotchkiss R, Pederson W. Green's operative hand surgery. Philadelphia: Churchill Livingstone; 2005. p. 1319-71.
- Oberlin C, Béal D, Leechavengvongs S, Salon A, Dauge MC, Sarcy JJ. Nerve transfer to biceps muscle using a part of ulnar nerve for C5-C6 avulsion of the brachial plexus: anatomical study and report of four cases. *J Hand Surg Am*. 1994;19(2):232-7.
- Merrell GA, Barrie KA, Katz DL, Wolfe SW. Results of nerve transfer techniques for restoration of shoulder and elbow function in the context of a meta-analysis of the English literature. *J Hand Surg Am*. 2001;26(2):303-14.
- Loy S, Bhatia A, Asfazadourian H, Oberlin C. [Ulnar nerve fascicle transfer onto the biceps muscle nerve in C5-C6 or C5-C6-C7 avulsions of the brachial plexus. Eighteen cases]. *Ann Chir Main Memb Super*. 1997;16(4):275-84.
- Franciosi LF, Modestti C, Mueller SF. Neurotization of the biceps muscle by end-to-side neurotomy between ulnar and musculocutaneous nerves. A series of five cases. *Chir Main*. 1998;17(4):362-7.
- Leechavengvongs S, Witoonchart K, Uerpairojkit C, Thuvasethakul P, Ketmalasiri W. Nerve transfer to biceps muscle using a part of the ulnar nerve in brachial plexus injury (upper arm type): a report of 32 cases. *J Hand Surg Am*. 1998;23(4):711-6.
- Sungpet A, Suphachattwong C, Kawinwonggowit V, Patradul A. Transfer of a single fascicle from the ulnar nerve to the biceps muscle after avulsions of upper roots of the brachial plexus. *J Hand Surg Br*. 2000;25(4):325-8.
- Bertelli JA, Ghizoni MF. Reconstruction of C5 and C6 brachial plexus avulsion injury by multiple nerve transfers: spinal accessory to suprascapular, ulnar fascicles to biceps branch, and triceps long or lateral head branch to axillary nerve. *J Hand Surg Am*. 2004;29(1):131-9.
- Ferraresi S, Garozzo D, Buffatti P. Reinnervation of the biceps in C5-7 brachial plexus avulsion injuries: results after distal bypass surgery. *Neurosurg Focus*. 2004;16(5):E6.
- Teboul F, Kakkar R, Ameur N, Beaulieu JY, Oberlin C. Transfer of fascicles from the ulnar nerve to the nerve to the biceps in the treatment of upper brachial plexus palsy. *J Bone Joint Surg Am*. 2004;86(7):1485-90.
- Shahriar-Kamrani R, Jafari SM, Guiti MR. The results of using a part of ulnar nerve for restoration of elbow flexion in patients with upper brachial plexus injury. *Acta Med Iranica*. 2005;43(3):204-8.
- Al-Qattan MM. Oberlin's ulnar nerve transfer to the biceps nerve in Erb's birth palsy. *Plast Reconstr Surg*. 2002;109(1):405-7.
- Tung TH, Novak CB, Mackinnon SE. Nerve transfers to the biceps and brachialis branches to improve elbow flexion strength after brachial plexus injuries. *J Neurosurg*. 2003;98(2):313-8.
- Noaman HH, Shiha AE, Bahm J. Oberlin's ulnar nerve transfer to the biceps motor nerve in obstetric brachial plexus palsy: indications, and good and bad results. *Microsurgery*. 2004;24(3):182-7.
- Bhandari PS, Sadhotra LP, Bhargava P, Bath AS, Singh P, Mukherjee MK. Microsurgical reconstruction for devastating brachial plexus injuries. *Indian J Neurotrauma*. 2005;2(1):35-9.
- Shigematsu K, Yajima H, Kobata Y, Kawamura K, Maegawa N, Takakura Y. Oberlin partial ulnar nerve transfer for restoration in obstetric brachial plexus palsy of a newborn: case report. *J Brachial Plex Peripher Nerve Inj*. 2006;1:3.
- Hiermer R, Berger A. Options and results of neurotization of the musculocutaneous nerve in posttraumatic brachial plexus lesions of the adult. *J Hand Surg Am*. 2006;31(Suppl 1):27.
- Jobe MT, Wright PE. Peripheral Nerve Injuries. In: Canale ST, editor. *Campbell's operative orthopaedics*. 9th ed. St Louis: Mosby; 1998. p. 3827-87.
- Osman N, Bhatia A, Cadot B, Geffroy MC, Ledroux D, Oberlin C. Histomorphometry of the ulnar nerve and of its branches. *Surg Radiol Anat*. 1998;20(6):409-11.
- Frey M. Avulsion injuries to the brachial plexus and the value of motor reinnervation by ipsilateral nerve transfer. *J Hand Surg Br*. 2000;25(4):323-4.
- Hattori Y, Doi K, Baliarsing AS. A part of the ulnar nerve as an alternative donor nerve for functioning free muscle transfer: a case report. *J Hand Surg Am*. 2002;27(1):150-3.
- Narakas AO, Hentz VR. Neurotization in brachial plexus injuries. Indication and results. *Clin Orthop Relat Res*. 1988;(237):43-56.
- Brandt KE, Mackinnon SE. A technique for maximizing biceps recovery in brachial plexus reconstruction. *J Hand Surg Am*. 1993;18(4):726-33.
- Marshall RW, Williams DH, Birch R, Bonney G. Operations to restore elbow flexion after brachial plexus injuries. *J Bone Joint Surg Br*. 1988;70(4):577-82.