

RETROSPECTIVE STUDY OF FIRST METATARSAL BASE OSTEOTOMY AS A TREATMENT OF HALLUX VALGUS

HELENCAR IGNÁCIO¹, ALCEU GOMES CHUEIRE², GUARACY CARVALHO FILHO³, LEANDRO VIEIRA NASCIMENTO⁴,
UBIRATAN MAIA RODRIGUES VASCONCELOS⁴, GUSTAVO TRAJANO DE FREITAS BARÃO⁴

SUMMARY

The authors evaluated 33 patients (48 feet) with moderate to severe hallux valgus, surgically treated by using a 1st metatarsal wedged base osteotomy technique associated to soft tissues repair. Comparisons correlating gender, age, and x-ray parameters were performed by using the t-test for independent samples; sesamoid deviation was compared by Kruskal-Wallis non-parametric test. All patients answered to a questionnaire in which they expressed their degree of satisfaction regarding the final results of the surgery. Seventy six per cent of patients were women between 14 and 60 years old (average 38.15 years old) with an average follow-up time of 41 months. There was no differ-

ence in x-ray variation concerning gender. There were no pre or post-operative differences when mean scores for right and left feet were compared. X-ray evaluation presented 73% of excellent results and the degree of total satisfaction with the method was 60.7%. There is no evidence proving that age may influence the patients' degree of satisfaction; nevertheless, all patients above 60 years old reported to be partially satisfied. We concluded that this surgical procedure is an efficient and safe method for the treatment of moderate and severe hallux valgus.

Keywords: Hallux valgus; Osteotomy; Metatarsus

INTRODUCTION

According to Mann and Coughlin, hallux valgus was first reported in 1856, giving more emphasis to medial exosthosis genesis than to the complex deformity itself⁽¹⁾. Subsequently, in 1871, the first definition for the deformity as being only a static subdislocation of the first metatarsophalangeal joint with hallux lateral deviation and medial deviation of the first metatarsus⁽²⁾. This objective definition of the deformity remains as the one best expressing the complex changes occurring in the first radius, being frequently accompanied by deformity and symptoms in other toes⁽³⁾.

Hallux valgus is characterized by an angle above 9° between the first and second metatarsals (IMA); an angle in valgus above 15 degrees at the first metatarsophalangeal joint (HVA)⁽³⁾; and a lateral subdislocation of the sesamoids (DS) in variable degrees⁽¹⁾.

The purpose of classifying the hallux valgus aims to facilitate the decision about the best procedure to be performed⁽²⁾. There is no perfect classification, but it is important to know the system, because this takes into consideration: hallux degree of valgus, the angle between the first and second metatarsus, the degree of sesamoid dislocation, and the distal joint angle of the first metatarsal. Depending on these parameters, the deformity can be classified as mild, moderate, or severe.

In literature, there is a vast amount of studies addressing and advocating various surgical techniques, such as soft parts proce-

dures (McBride's technique modified by Duvries), arthrodesis (Lapidus and McKeever's technique) and osteotomies (Chevron's, Keller's, Akin's, Michell's techniques), especially the first metatarsal base osteotomy^(4,5,6,7,8,9,10,11).

The first metatarsal base osteotomy is prescribed in any age group, and its major indication is for hallux valgus with incongruent metatarsophalangeal joint (subdislocated), with HVA above 30°, and IMA above 16°, being contra-indicated in patients with congruent joint, significant arthrosis, and in any kind of spasticity⁽²⁾.

The objective of this study is to present the results achieved by means of the use of base osteotomy for the treatment of moderate to severe hallux valgus, evaluating the improvements on X-ray parameters (HVA, IMA, DS, MDJA), the subjective analysis of the degree of satisfaction and techniques' ability to correct it, based on pre- and postoperative data.

CASE SERIES AND METHODS

Our study comprehended 33 patients (48 feet) with moderate to severe hallux valgus, with HVA ranging from 20° to 53° (average: 30.33°), IMA of 11° to 20° (average: 12.45°), grade 2 or 3 of sesamoid deviation (deviation greater than 50%) and metatarsal distal joint angle (MDJA) ranging from 10° to 60° (average: 23.3°). Those patients came from the Foot Surgery infirmary of the Department of Orthopaedics and Traumatology and were followed up from July 1997 to November 2005, with a mean follow up time of 41 months, ranging from thirteen to sixty-five months.

Study conducted at the Department of Orthopaedics and Traumatology, Medical College, São José do Rio Preto-SP (FAMERP) – Hospital de Base

Correspondences to: Av. Brigadeiro Faria Lima, 4929 – Cep 15090-000 - Bairro Nova Redentora – São José do Rio Preto – SP

1. PhD professor in Orthopaedics and Traumatology, and Preceptor of the Resident Doctors
2. PhD Professor in Orthopaedics and Traumatology, and Head of the Discipline of Orthopaedics and Traumatology
3. PhD Professor in Orthopaedics and Traumatology, and Head of the Department of Orthopaedics and Traumatology
4. Resident doctor of the Orthopaedics and Traumatology Service

Received in: 04/13/05; approved in: 12/23/05

The patients were submitted to deformity correction by the first metatarsal base osteotomy with addition wedge technique combined to soft parts release. Among studied patients, 15 (45.4%) presented with bilateral affection, in 13 (39.5%) only the left foot was affected, and in 5 (15.1%) only the right foot was affected. Ages ranged from 14 to 60 years old (average: 38.15 years), being 8 male patients (24%) and 25 (76 %) female patients.

The main indication for surgical treatment was pain preceding hospitalization (average: 4.4 years, ranging from 2 months to 22 years), followed by first metatarsophalangeal joint deformity (average: 11.3 years; minimum 1 years, maximum 40 years).

All patients presented with pain at the medial eminence of the first metatarsus head, 6 patients (18.2 %) also presented with pain at the 2nd metatarsophalangeal joint region (17.4%) and 2 patients (6%) at the 5th metatarsophalangeal joint.

Regarding activities restraint, 2 patients (6%) presented with restraints only for sport-related activities, 27 (82.7%) presented such restraints for daily activities, and 4 (12.1%) presented with pain even at rest. Of the patients above, 26 (78%) reported shoes-wearing restraints.

X-ray images of the foot were taken pre- and postoperatively in all patients at anteroposterior (AP) and lateral orthostatic-position planes, being used as parameters: hallux valgus angle⁽¹²⁾ (formed between the straight line segment corresponding to medial diaphyseal axis of hallux proximal phalanx and first metatarsus mechanical axis); intermetatarsal angle⁽¹²⁾ (formed by the mechanical axis of I and II metatarsi); sesamoid deviation (measurement of sesamoid subdislocation degree according to grading criteria by Smith et al.⁽¹²⁾); and metatarsal distal joint angle (MDJA) measured by the line linking both ends of the distal joint surface of the first metatarsus and the one located perpendicularly to the diaphyseal medium axis of the first metatarsal as well (Figure 1).

According to Coughlin, X-ray measurements of the angles are useful parameters for hallux valgus classification⁽¹⁾, as follows:

- 1)** Mild deformity – characterized by HVA below 20°, IMA below 11° and less than 50% dislocated sesamoids.
- 2)** Moderate deformity – characterized by HVA between 20° and 40°, IMA between 11° and 16° and 50 – 75% dislocated sesamoids
- 3)** Severe deformity – characterized by HVA above 40°, IMA above 16°, and more than 75% dislocated sesamoids

Regarding the surgical technique employed, after asepsis, anti-sepsis, sterile drapes placement and tourniquet attached to thigh radix, surgery was performed with a longitudinal and medial incision starting at the medium portion of the proximal phalanx and extending proximally two or three centimeters from the medial eminence. The sensitive branch of the superficial fibular nerve was dissected and isolated. Capsule was opened in "L" shape, leaving a strong capsular patch adhered to the base of hallux proximal phalanx (Figure 2). The exostectomy was performed with oscillatory saw, using the extension of the medial border of the first metatarsus diaphysis as a guide. The second incision was performed between the first and second metatarsal with an aperture approxi-

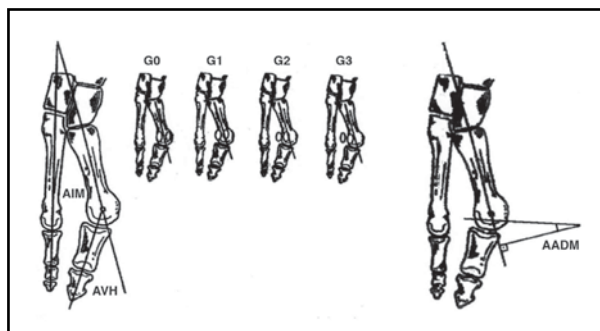


Figure 1 - Basic X-ray parameters for evaluating Hallux Valgus

mately 2-cm long, dissecting and isolating hallux adductor tendon, then performing its tenotomy (Figure 3).

Last incision was for osteotomy purposes, dorsal, at 2 cm distally to the first cuneiform metatarsal joint and extending proximally from 3 cm distally to the tendon of hallux extensor longus, being identified the cuneiform metatarsal joint. With the aid of the oscillatory saw, osteotomy was performed at 1 cm distal to metatarsal joint surface in right angle without cross-sectioning lateral cortical (Figure 4).

The size of the wedge basis was calculated according to intraoperative X-ray image, performed after osteotomy port, so as to reduce pre-existent X-ray parameters back to normal values, if the removed wedge basis was shown to be insufficient for correcting those X-ray values, the graft obtained from medial protuberance was doubled, aiming to build a sufficient bone block to fill adduction osteotomy.

Graft was modeled to perfectly fit the osteotomy and avoiding bone protuberances. Osteotomy was fixed with a Kirschner wire 1.5, obliquely inserted and directed by per-operative X-ray control (Figure 5).

Capsulorrhaphy to aid on HVA correction was performed after exeresis of approximately 1.0 cm of the perpendicular arm of the "L" at the capsule aperture (compared to metatarsus diaphysis).

A 5-cm second resection was performed at the horizontal portion of the "L" to aid on reducing sesamoids after tractioning of the plantar portion of the joint capsule. Capsule suture was performed with multifilament absorbable suture number 0 (Vicryl®), helping on HVA and sesamoids correction. Then, surgical incisions on the skin were sutured with non-absorbable monofilament 4.0 (mononylon®). Subsequently, new X-ray images were taken to check if all values had been corrected.

Dressing was placed after surgery and the patients were instructed to replace it on a daily basis. Stitches were removed at the 15th day postoperatively, and gait was not allowed until the end of the sixth week, when Kirschner wires were removed after a new X-ray control (Figure 6).

At the moment of endpoint evaluation, additionally to clinical data obtained from X-ray studies and from the patients, they answered a subjective questionnaire, from which data about presence of residual pain, final appearance, and degree of personal satisfaction were taken.

For statistical analysis, comparisons of X-ray parameters variations were made through the paired t-test, except for the Sesamoid Deviation (SD). The SD was compared by the non-parametric sign test. Comparisons correlating gender, age, and X-ray parameters,

except the SD, were made by the t-test for independent samples. SD was compared by Kruskal-Wallis' non-parametric test. Comparisons correlating gender, age, X-ray parameters, except SD, and according to the degree of satisfaction were made by using the variance analysis, while SD was compared by Kruskal-Wallis' test. Pearson's correlation coefficients were calculated among phases and among feet. A significance level of $\alpha = 0.05$ was adopted.

RESULTS

Average angles of studied X-ray parameters (HVA, IMA, SD and MDJA) significantly decreased postoperatively in both feet (28 left and 20 right) (Table 1 and Graphs 1 and 2). HVA returned to original normality levels ($< 15^\circ$) in 31 feet (64.6%), and decreased to levels of mild deformity (between 15° and 20°) in 10 (20.83%). IMA returned to normal ($< 9^\circ$) in 35 feet (73%), and to mild levels in 10 (20.83%).

Table 2 assesses the 15 cases presenting bilateral affection, showing no differences in average and standard deviation when compared to the outcomes of right foot against the left, both pre- and postoperatively. Those results were also depicted on Graphs 3 and 4. Regarding sesamoid deviation (SD) degree, a major improvement was seen when compared to pre-operative period. Before surgery, 22.9% of sesamoid deviation cases were considered as grade III and 77.1% as grade II, with no patient with grade-0 or -I SD. Postoperatively, 33.4% presented with SD grade 0, 39.5% grade I, 16.6% grade II, and 10.4% grade 3, as shown in Graph 5. Regarding personal satisfaction responded from the questionnaire at late postoperative period, 23 patients (69.7%) said they were fully satisfied with the surgery, 7 (21.2%) were partially satisfied, and 3 (9%) were unsatisfied. Those subjective data were represented on Graph 6.

When the postoperative degree of satisfaction was evaluated within the various age groups in study, we observed that full satisfaction was found in the patients whose ages were below 60 years old. Similarly, the ages of the 3 patients showing dissatisfaction ranged 20 to 59 years old. Above 60 years old, all patients were partially satisfied, according to Graph 7.

Three patients with unsatisfactory results were females and presented with moderate hallux valgus preoperatively, evolving with increased hallux and intermetatarsal valgus angle after surgery. In only one patient, MDJA presented a decreased value, despite other X-ray parameters have been increased.

Concerning sesamoid deviation, two patients presented an increase from grade 2 to grade 3, and one patient remained as grade 2. No cases of soft parts infection, skin necrosis, suture dehiscence, or osteotomy reduction loss occurred.

DISCUSSION

Hallux valgus should not be described as a simple deformity of the hallux in valgus, but

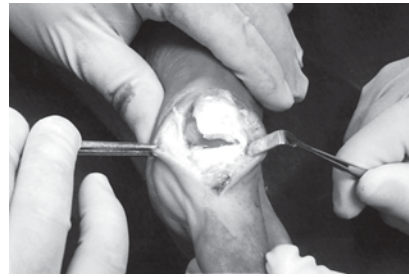


Figure 2 - Capsule opening in "L" shape

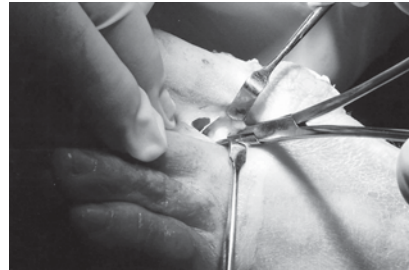

Figure 3 - Hallux adductor tendon, dissected and isolated

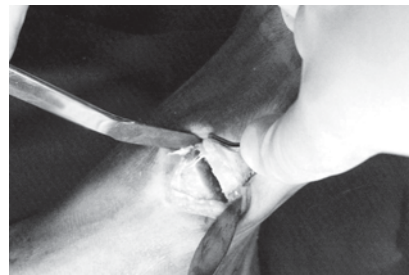

Figure 4 - First metatarsus base osteotomy

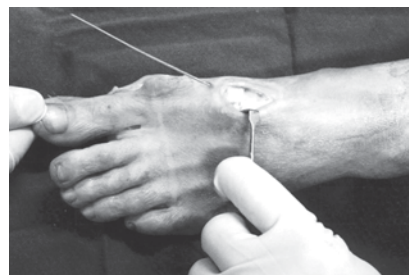


Figure 5 - Graft placement and Kirschner fixation

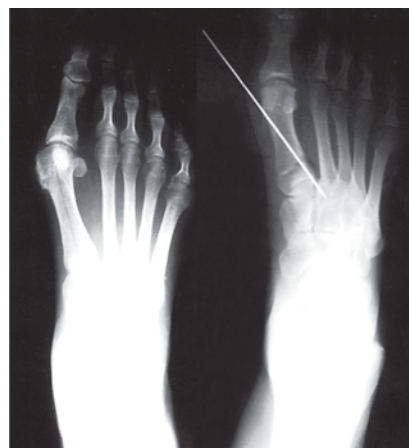

Figure 6 - Pre- and postoperative X-ray images

as a medial deviation of the first metatarsal, or even an exosthosis at the level of the first metatarsal's head⁽¹³⁾. Hallux deviation in valgus is just one of foot anatomy changes and this is not always a major concern⁽¹⁴⁾. This abnormality should be evaluated as a complex, structurally variable deformity of which clinical manifestation presents a wide range of severity, and may be understood as a pathology displacing medial segment, changing the biomechanics and compromising function. This pathology is usually painful, also implying in discomfort regarding shoes wearing, and foot profile can be considered ugly from the aesthetic point of view⁽¹³⁾.

Extrinsic and intrinsic factors take part on the genesis of deformities. The most important extrinsic etiologic factor is wearing inappropriate shoes, of which anterior chamber is triangle-shaped, producing metatarsals heads approximation with lateral deviation of the hallux and medial deviation of the 5th anklebone⁽²⁾. According to Lapidus⁽¹⁵⁾, female's shoes, tapered at the frontal end and with heels, is a determinant factor for a rapid development of hallux valgus, especially when combined to hereditary factors.

Intrinsic factors are increasingly being valued as the physiopathology of this complex deformity is being clarified⁽²⁾. Among the major factors, we can highlight: the first metatarsal varus (*metatarsus primus varus*), Egyptian-type digital formula, the metatarsal formula index minus, the valgus flat foot, ligament hyperlaxity, the rounded shape of the first metatarsus distal joint surface, neuromuscular diseases, and the rheumatoid pathologies.

On the other hand, the higher incidence in a family presupposes the "hereditary" factor of which genetic features have an incomplete penetration, are bonded to the female gender chromosome and present diversified expressivity⁽¹³⁾.

Regarding treatment, we may say that there is a limitation regarding conservative treatment in the natural evolution of the hallux valgus deformity⁽¹³⁾.

Surgical treatment has been object of uncountable studies, due to the complexity of the pathology and to associated anatomical details, existing about 150 different techniques described⁽²⁾.

Base osteotomy is indicated, among others, to patients in any age group presenting joint incongruence and severe deformities (HVA $> 30^\circ$, IMA > 13), being contraindicated in the presence of arthrosis.

In this retrospective study of patients with moderate to severe hallux valgus treated with

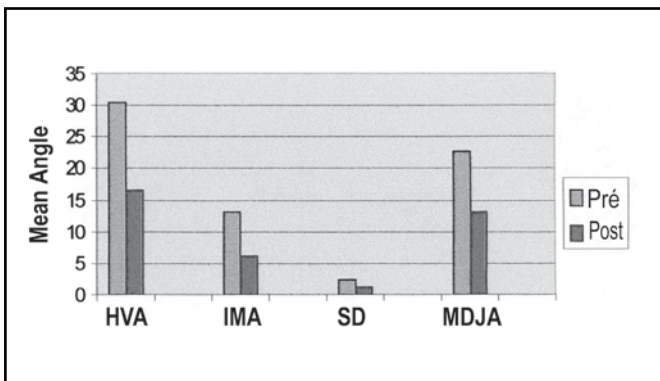
base osteotomy, a significant reduction of studied X-ray parameters was seen. Most of the feet returned to normality levels or achieves mild deformities (83.33% for HVA and 89.5% for IMA), those date were also noted by other authors^(16,17). This technique produces a sufficiency of the first metatarsus for two reasons: it promotes a lateral translation of distal fragment and the introduction of a medial wedge⁽¹⁶⁾. An improvement on the degree of sesamoid subdislocation was seen at the postoperative period, although not so expressively as in other studies in literature⁽¹⁶⁾. Except for three patients, the majority showed improvement of the SD after surgical correction. Although not everybody had achieved a normality degree, there was a decrease from a severe dislocation degree to a milder one. The vast majority of the patients in our study were females (76%); a

Parameters	Numbers	Average		Standard Deviation		p value
		Pre	Post	Pre	Post	
L HVA	28	30.4	16.6	9.4	11.9	0.0000
R HVA	20	31.2	15.6	7.2	10.0	0.0000
L IMA	28	13.2	6.2	2.7	6.4	0.0000
R IMA	20	12.0	5.5	1.5	3.7	0.0000
L SD	28	2.3	1.1	0.5	0.9	0.0000
R SD	20	2.1	0.9	0.3	1.0	0.0000
L MDJA	28	22.7	13.2	14.8	9.3	0.0000
R MDJA	20	24.6	15.3	15.0	10.8	0.001

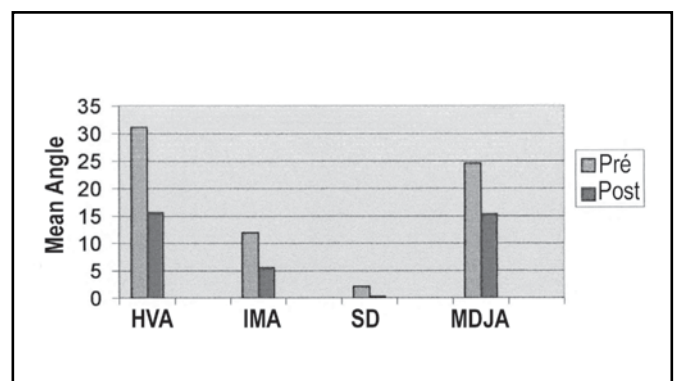
Parameters	Numbers	Average		Standard Deviation		p value
		Pre	Post	Pre	Post	
HVA Pre	15	31.0	30.9	9.7	7.4	0.934
HVA Post	15	16.7	13.5	12.4	7.2	0.204
IMA Pre	15	13.4	12.4	2.7	1.4	0.136
R IMA Post	15	6.5	5.3	6.4	3.7	0.423
SD Pre	15	2.3	2.1	0.46	0.35	0.164
SD Post	15	1.1	0.9	0.9	0.9	0.334
MDJA Pre	15	20.3	23.0	17.3	16.8	0.307
MDJA Post	15	13.2	13.4	9.7	8.8	0.888

Table 1- Pre- and postoperative average values of hallux valgus angle (HVA) intermetatarsal angle (IMA), sesamoids deviation (SD) and metatarsal distal joint angle (MDJA) for right and left feet.

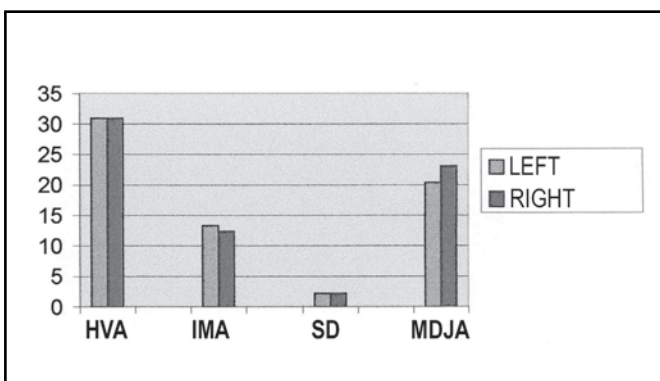
fact also reported by Salomão et al.⁽¹⁸⁾ (84.37% among 160 patients); Mann and Coughlin⁽¹⁹⁾ (94%) and Nery⁽²⁰⁾ (100% in a series of 55 patients), with the use of inappropriate shoes being one of the most important factors mentioned, which was also noted by many authors^(16,19,21,22). There was no difference between men and women concerning mean age at the time of surgery (38.15 years old). According to Brazilian literature, broader statistics show that age group is variable. In the case series of Salomão et al.⁽¹⁸⁾, mean age was 44.6 years old, being lower in the study by Nery⁽²⁰⁾, with an average of 36.7 years old. According to the subjective degree of satisfaction answered in a questionnaire, most of patients reported being satisfied with surgical outcome, being this result similar to that in the study by Cedell and Aström⁽²³⁾, in which 60% were



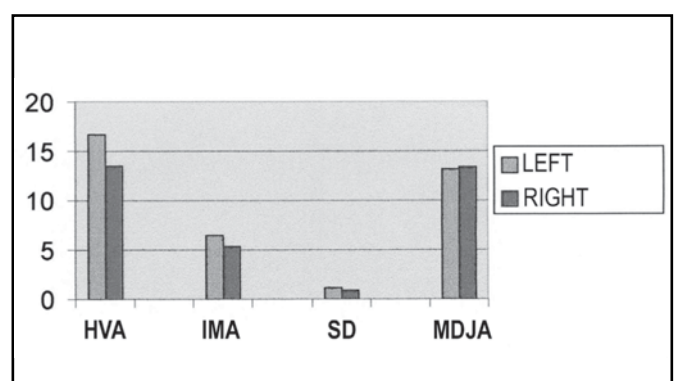
Graph 1- X-ray parameters for the left foot



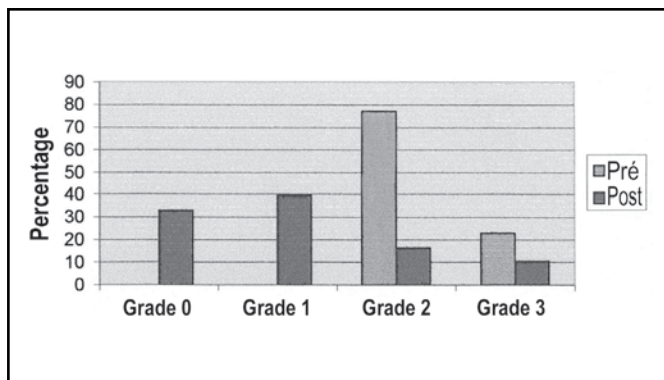
Graph 2 - X-ray parameters for the right foot



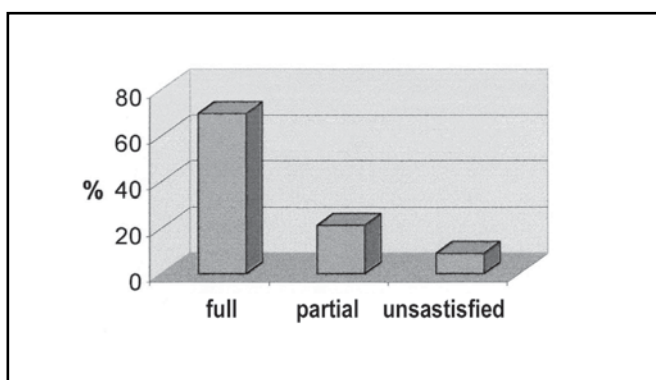
Graph 3 - Preoperative mean angles



Graph 4 - Postoperative mean angles



Graph 5 - SD degree (percentage) pre- and postoperatively

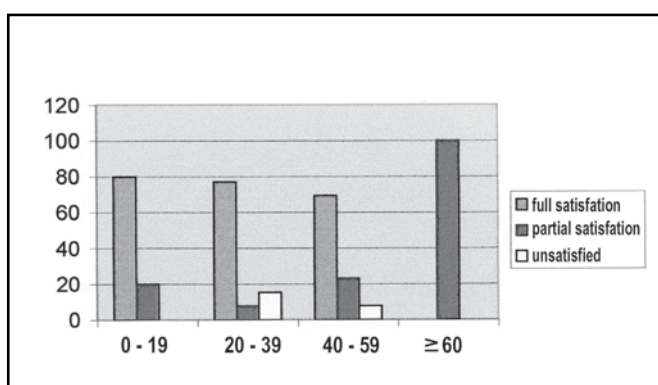


Graph 6 - Postoperative satisfaction

fully satisfied with the procedure.

It was noticed that the average decrease of the HVA, IMA and SD after surgery was lower in the group of unsatisfied patients, but this was not noticed for MDJA, since there is no difference in the mean angle according to satisfaction degree. When a comparison is made to literature, we see that the majority of authors don't use this X-ray parameter for outcomes endpoint evaluation^(4,16,20,23).

There is no evidence showing that mean age could influence satisfaction degree ($p = 0,45$), but it was observed that all patients above 60 years old reported partial satisfaction, and dissatisfaction results were shown by 20 – 59 year-old age group. Such data



Graph 7 - Satisfaction degree percentage in age groups

could not be found in similar reports in current literature.

In both patients with juvenile hallux valgus, operated at 14 years old, we did not find changes on X-ray planes after 16 months of follow-up, maintaining the same values achieved at the immediate postoperative period. Those patients remained asymptomatic during this final follow-up period, being satisfied with the surgical technique employed.

CONCLUSION

We conclude that the first metatarsus base osteotomy in the treatment of moderate to severe cases of Hallux Valgus was shown to be a safe and effective method, reducing all pre-existent X-ray parameters, leading to full satisfaction for the majority of patients.

REFERENCES

- Mann RA, Coughlin MJ. Adult hallux valgus. In: Mann RA, Coughlin MJ. Surgery of the foot and ankle. 7th ed. St. Louis: Mosby; 1999; p.151-267.
- Nery CAS. Hálux valgo. Rev Bras Ortop 2001; 36:183-99.
- Richardson EG. Transtornos do hálux. In: Campbell. Cirurgia ortopédica. 8thed. Nascimento, FG. São Paulo: Mosby; 1996; p.2811-94.
- Henning EE, Hamid AJAA, Francisco OLS, Henning C. Estudo retrospectivo comparativo de algumas técnicas cirúrgicas no tratamento do hallux valgus. Rev Bras Ortop 1997; 32:641-6.
- Borton DC, Stephens MM. Basal metatarsal osteotomy for hallux valgus. J Bone Joint Surg Br 1994; 76:204-9.
- Grace D, Hughes J, Klenerman L. A comparison of Wilson and Hohmann osteotomies in treatment of hallux valgus. J Bone Joint Surg Br 1988; 70:236-41.
- Hetherington VJ, Steinbock G, La Porta D, Gardner C. The Austin bunionectomy: a follow-up study. J Foot Ankle Surg Am 1993; 32:162-6.
- Johnson KA. Chevron osteotomy of the first metatarsal: patient selection and technique. Comtemp Orthop 1981; 3:707-11.
- Jones RO, Harkless LB, Baer MS, Wilkinson SV. Retrospective statistical analysis of factors in influencing the of long-term complication following hallux abducto valgus surgery. J Foot Surg 1991; 30:344-9.
- Kinmard P, Cantin S. The Akin procedure in hallux valgus. Can J Surg 1991; 34:491-3.
- Hardy RH, Clapham JCR. Observation on hallux valgus. Basead on a controlled series. J Bone Joint Surg Br 1951; 33:376-91.
- Smith RW, Reynolds JC, Stewart MJ. Hallux valgus assessment: report of research committee of American Orthopaedic Foot and Ankle Society. Foot Ankle 1984; 5:92-103.
- Carvalho Junior AE. Hálux valgo no adulto. Clin Ortop 2001; 2:365-78.
- Salomão O. Pé do adulto. In: Hebert S, Xavier R, Junior, A.G.P.; Barros Filho, TEP et al. Pé Ortopedia e Traumatologia Princípios e Prática; Porto Alegre, Artmed; 1998. 301-312.
- Lapidus PW. The author's union operation from 1931 to 1959. Clin Orthop 1960; 16:119-35.
- Ruaro AF, Carvalho Junior AE, Fernandes TD, Salomão O, Aguiar JAG, Meyer AT. Estudo comparativo entre duas técnicas de osteotomia no tratamento do hálux valgo: análise clínica e radiográfica. Rev Bras Ortop 2000; 35:248-59.
- Limbird TJ, Dasilva RM, Green NE. Osteotomy of the first metatarsal base for metatarsus primus varus. Foot Ankle 1989; 9:158-62.
- Salomão O, Carvalho Junior AE, Fernandes TD, Koyama C, Arruda JCA, Kosai T. Hálux valgo e pé plano: estudo radiográfico em 160 pacientes. Rev Bras Ortop 1993; 28:402-6.
- Mann RA, Coughlin MJ. Hallux valgus: etiology, anatomy, treatment and surgical considerations. Clin Orthop 1981; 157:31-41.
- Nery CAS. Osteotomia em "Chevron" para tratamento do hálux valgo. Parte 1- Avaliação clínica radiológica e estudo trigonométrico. Rev Bras Ortop 1993; 30:385-92.
- Coughlin MJ, Thompson FM. The high price of high-fashion foot-wear. Instr Course Lect 1995; 44:371-7.
- Kato T, Watanabe S. The etiology of hálux valgus in Japan. Clin Orthop 1981; 157:78-81.
- Cedell CA, Aström M. Proximal metatarsal osteotomy in hallux valgus. Acta Orthop Scand 1982; 53: 1013-8.