







PECTORALIS MAJOR TENDON INJURY: RECONSTRUCTION USING BONE TUNNEL AND ANCHORS

LESÃO DO TENDÃO DO PEITORAL MAIOR: RECONSTRUÇÃO UTILIZANDO TÚNEL ÓSSEO E ÂNCORAS

JOSÉ CARLOS GARCIA JUNIOR¹ , EDUARDO FERREIRA CORDEIRO¹ , HILTON VARGAS LUTFI¹ , MAURÍCIO DE PAIVA RAFFAELLI¹ ,
MAURÍCIO SALOMÃO FADEL¹ , MÁRCIO EDUARDO KOZONARA¹ 

1. NAEON Institute, São Paulo, SP, Brazil.

ABSTRACT

Objective: This study aims to assess a new technique used for pectoralis major reconstruction using bone tunnel and fixation with metallic anchors in the contralateral cortical bone. **Methods:** Patients who had undergone post-surgical reconstruction of the pectoralis major at least 24 months before were assessed by the UCLA Shoulder Score and the Simple Shoulder Test and compared with the contralateral side by manual goniometry. Subgroup analysis was also performed between grafted and non-grafted patients. **Results:** 13 patients fulfilled the inclusion criteria. The average UCLA score was 34.77 ± 0.12 , compared with the standard 27 of good and excellent results $p < 0.0001$. The Simple Shoulder test mean was 11.92 ± 0.08 . Grafted and non-grafted subgroups had no statistical differences for UCLA $p = 0.58$ and Simple Shoulder Test $p = 1.00$. Long term losses for elevation or external rotation were lower than 5° . No lesions recurred. All patients returned to their physical activities with no restrictions. **Conclusion:** The pectoralis major reconstruction technique using a bone tunnel and metallic anchors in the contralateral cortical bone was effective. However, its execution needs special care to avoid complications. **Level of Evidence IV, Case Series.**

Keywords: Pectoralis Muscles. Suture Anchors. Athletic Injuries.

RESUMO

Objetivo: Avaliar, em uma série de casos, o uso da técnica de reconstrução do músculo peitoral maior através de túnel ósseo na cortical umeral anterior, feito no local de inserção original desse tendão, com fixação tendínea, usando âncoras metálicas na cortical contralateral. **Métodos:** Foram avaliados pacientes com mais de 24 meses de pós-operatório de reconstrução do tendão do peitoral maior através do escore da UCLA, do teste simples de ombro e da goniometria manual comparativa com o lado contralateral. Foram também avaliados e comparados os subgrupos uso de enxerto versus sem enxerto usando os testes de qualidade de vida e goniometria mencionados acima. **Resultados:** De todos os pacientes operados pelo cirurgião sênior do serviço, 13 alcançaram os critérios de inclusão e foram incluídos nesse trabalho. O escore da UCLA foi de $34,77 \pm 0,12$, comparado com o padrão 27 de bons e ótimos resultados $p < 0,0001$. A média para o teste simples de ombro foi de $11,92 \pm 0,08$. Com relação ao uso de enxerto, não houve diferenças entre os subgrupos com e sem enxerto, $p = 0,62$ para o escore da UCLA e $p = 0,35$ para o teste simples de ombro. Não houve perda de elevação ou rotação externa superior a 5° nem relesões. Todos os pacientes retornaram às atividades físicas. **Conclusão:** A técnica de reconstrução do tendão do peitoral maior com túnel ósseo e fixação na cortical contralateral com âncoras demonstrou-se efetiva, mas sua execução necessita cuidado afim de evitarem-se complicações. **Nível de Evidência IV, Série de Casos.**

Descritores: Músculo Peitoral. Âncoras de Sutura. Traumatismos em Atletas.

Citation: Garcia JC Jr, Cordeiro EF, Lutfi HV, Raffaelli MP, Fadel MS, Kozonara ME. Pectoralis major tendon injury: reconstruction using bone tunnel and anchors. *Acta Ortop Bras.* [online]. 2022;30(2): Page 1 of 4. Available from URL: <http://www.scielo.br/aob>.

INTRODUCTION

Lesions of the pectoralis major muscle were first described in 1822 by Patissier.¹ Until 2012, medical literature had reported around 200 cases only of this type of injury.² Although uncommon, such lesions have been more prevalent in recent decades, mainly in 20 to 40-year-old males. Its

main causes are car accidents³ and an increasing number of sports, including: weightlifting, especially straight supine; rugby; boxing; and some throwing sports.^{2,3} The most common rupture mechanism is an excessive eccentric contraction with pectoral extension after resisting a load applied with the arm in abduction and extension position.¹⁻⁵

José Carlos Garcia Junior is a paid consultant at Zimmer Biomet.
All other authors declare no potential conflict of interest related to this article.

The study was conducted at NAEON Institute and at Hospital Moriah.

Correspondence: José Carlos Garcia Junior. Avenida Ibirapuera, 2907, room 1206, São Paulo, SP, Brazil, 04028001. josecarlos@naeon.org.br

Article received on 05/12/2020, approved on 11/18/2020.



More individuals seem to have suffered total rupture of the pectoral caused by abuse of anabolic steroids for rapid muscle mass gain, possibly because of disproportion in the cross-sectional area of the tendon and the muscle, changes in sensitivity to pain and tendon stiffness, less energy absorption, and fail caused by stretching loss.⁶

The pectoralis major is a muscle with two parts: the clavicular and the sternal, the latter most commonly involved in ruptures.¹ This lesion is diagnosed by clinical diagnosis, i.e., using only anamnesis and physical examination.⁷ Imaging such as ultrasound and magnetic resonance are useful in cases of doubt or chronic lesions and to establish the site and extension of the pectoral lesion.¹ Radiographic examination is useful to assess cases with bone avulsion or which need fracture differentiation.^{1,5}

During clinical examination, patients usually feel a sudden pain in the medial and cranial face of the arm and/or the thorax associated with a click, with or without ecchymosis. Loss of the axillary fold causes muscle asymmetry,^{2,3} which is more visible when patients perform limb abduction by flexing against resistance, especially with the shoulder in external rotation or resisting forced adduction by the examiner.

Compared to conservative treatment, surgery leads to improved function and is usually recommended for young individuals, athletes, and those with aesthetic complaints.⁸ Non-surgical treatment is best indicated for patients with partial or muscle mass rupture, patients with low functional demand, and older adults.^{1,8}

Surgical options include fixation of the tendon to the humerus with bone tunnels or suture anchors; suture of the tendon of the ruptured sternal head with an intact clavicular head tendon; screws with washers; "endobuttons;" interference screws; and direct repair of lesions in the musculotendinous junction.⁴ Auto/allografts may be needed for reconstructions or repair of chronic lesions. The most commonly used grafts are of the patellar tendon with bone fragment, of tensor fascia latae, and of semitendinosus, gracilis, and calcaneal tendons.⁹⁻¹²

This study sought to evaluate a technique of pectoralis major muscle reconstruction which uses bone tunnels in the anterior humeral line at the original insertion site of the tendon and metal anchors in the contralateral cortical area for fixation. We also compared chronic patients with semitendinosus tendon graft and those with acute ruptures without graft.

METHODS

Retrospective cohort study of case series type. This study also compared two subgroups: patients with chronic injury or any type of lesion who needed a semitendinosus tendon graft against patients who did not require grafting. The only patient with acute rupture who required grafting had a rare transtendinous injury.

Inclusion criteria: all patients diagnosed with total rupture of the pectoralis major tendon who were subjected to surgery and operated from March 2009 to March 2018 by anchoring in the contralateral cortical using bone tunnel where the tendon is reinserted with or without graft.

Exclusion criteria: patients who were not diagnosed with pectoralis major rupture, patients older than 60 years, patients with muscular lesions, patients subjected to other surgical techniques, vulnerable populations, and those who refused to provide data for the study.

Of the 25 patients with pectoralis major injury who were operated by the senior surgeon of the group, 13 fit the inclusion criteria and were evaluated. The other 12 were excluded for using other fixation methods, of which: three underwent suturing of the sternal head with the clavicular head (technique no longer recommended by the author) and nine had transosseous fixations. We assessed

13 patients subjected to surgery for repair/reconstruction of the pectoralis major muscle tendon performed by a single surgeon from January 2009 to March 2018, with at least 27 months of post-surgery follow-up.

Evaluation scores were:

UCLA Shoulder Score, Simple Shoulder Test, and comparative manual goniometry with contralateral side: all with at least two years of post-surgery.

Intraoperative and postoperative complications were reported.

Surgical technique:

The patient is placed in beach chair position under general anesthesia and Brachial plexus block. A pathway is made similarly to the deltopectoral approach but lower (about 2 cm below the coracoid process and 7 cm towards the armpit). For injuries in which reinsertion is possible, a bone tunnel with three holes in the anterior cortical is prepared using Kirschner 4.0 wires spaced about 5 mm. These holes are joined using rongeur. If needed, one more hole can be made, but three are usually enough. Three more holes as wide as the anchor cylindrical shaft diameter are then made through the tunnel in the contralateral cortical, one in the middle and 90° from the canal, one upper, and another lower, the latter two with about 70° – 45° angulation with the larger axis of the canal in extrinsic directions toward the center. Three 5 mm diameter metal anchors with at least two high strength wires each are inserted into these three holes through the tunnel. A Krackow-type suture is made in the tendon towards the pectoral and back using the high resistance wires of the anchors (Figure 1). The wires are then pulled to the intraosseous and sutured (Figure 2). When necessary, two tendons are usually used for grafting: the gracilis and the semitendinosus tendon, both trespassed through the middle of muscle mass, medial to myotendinous junction. A continuous-anchored suture is also made with a few more high-strength wires in the medial part of the graft and the lateral part of the pectoral, forming a web to dissipate energy to the muscle (Figure 3) and prevent new acute ruptures of this region of the pectoral trespassed with grafted tendons. This "web" must be tested, and all areas of the pectoral should be tensioned by the web distribution of points to avoid vascular strangulation as much as possible. Grafted tendons are then sutured with a tension that keeps adequate tone in the pectoral, with the three anchors in the same way as described above for acute pectoral injury (Figures 4 and 5). At closure, only skin and subcutaneous tissue are closed.

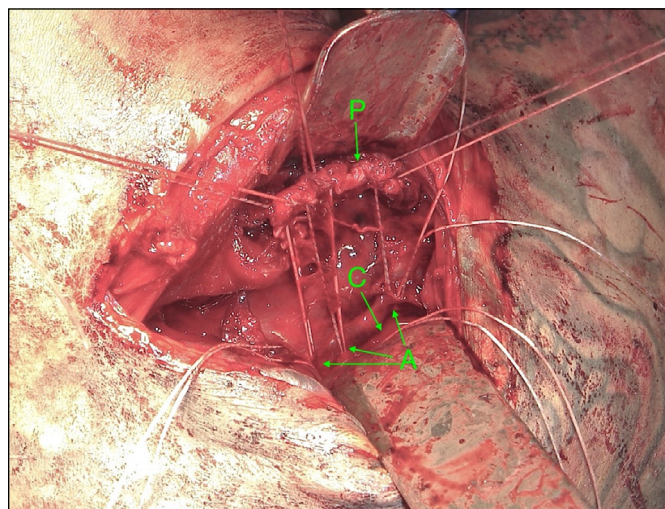


Figure 1. Visualization similar to deltopectoral approach, sutured tendon and view of the osseous canal. P: pectoral; C: bone tunnel; A: anchors.

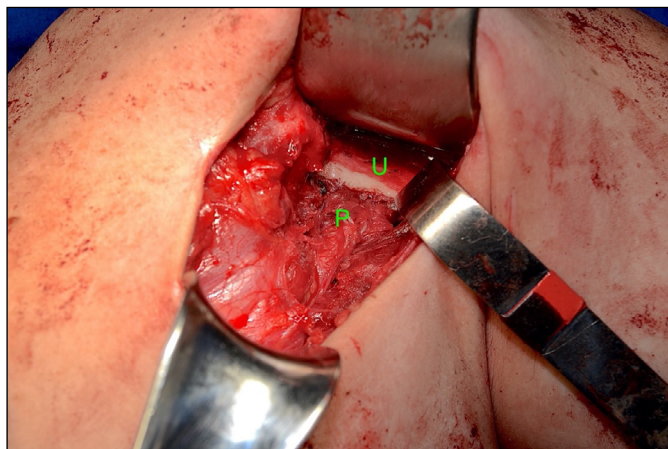


Figure 2. Visualization similar to deltopectoral approach, insertion of the pectoralis major tendon. U: humerus; P: pectoralis major.

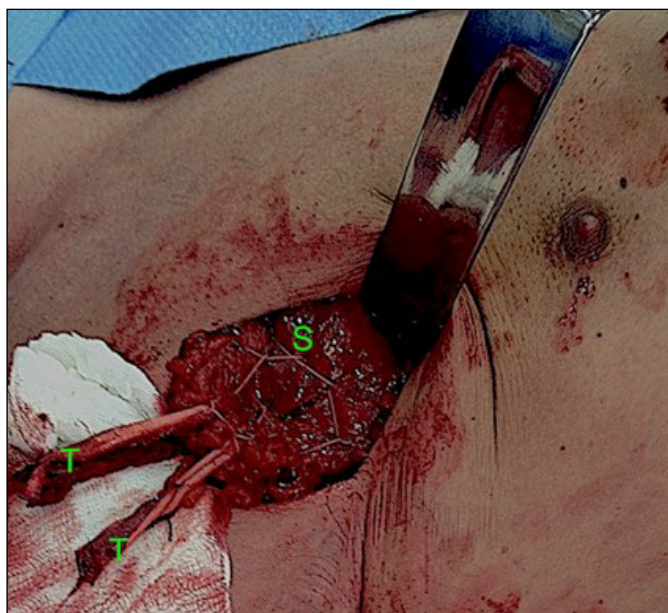

Figure 3. Visualization similar to deltopectoral approach, semitendinosus graft and web suture. S: "web" sutures; T: graft of the semitendinosus tendon.

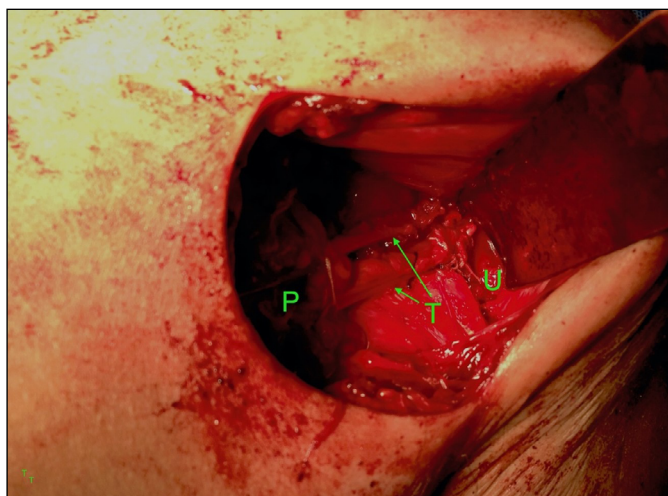


Figure 4. Visualization similar to deltopectoral approach, graft inserted in the osseous canal. P: pectoralis; A: inserted anchors; U: humerus.

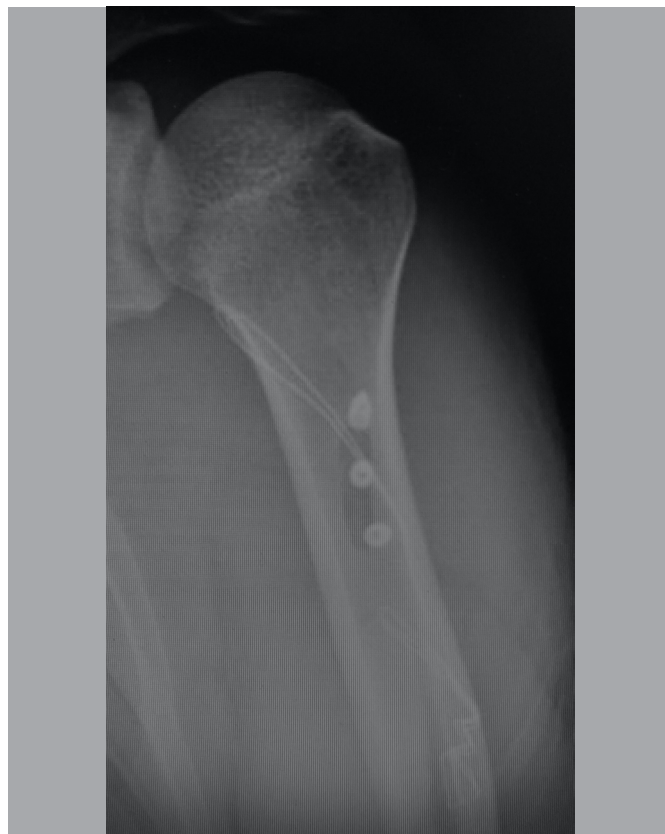

Figure 5. Radiography of the 3 implanted anchors and the bone tunnel.

After the procedure, the patient has to wear a sling for four weeks and the pendulum exercises begin after 2 weeks of surgery. After four weeks of surgery, passive range of motion exercises begin at the pain limit. The patient usually completes the movement after 12 to 13 months of operation at most. The patient returns to physical activities after 10 weeks of surgery and to activities with normal loads after 20 weeks.

Statistical evaluation respected the nature of the curves and subgroup analysis was performed between patients with and without tendon graft. Data were compared with good and excellent result patterns established by the literature and between subgroups. Established significance was 0.05 in a two-tailed curve.

This study was approved by the Research Ethics Committee under no. 3.734.596.

RESULTS

Of the 13 patients who participated in the study, nine were operated on the right side and four were operated on the left side. Seven patients required a semitendinosus tendon graft: six who had chronic injury and tendon degeneration and one with a transtendinous lesion. The six others did not need grafting because they had acute injury or had all grafts removed from the gracilis and semitendinosus tendons. The mean follow-up time was 76 months (27-135). All patients were male. The overall UCLA Shoulder Score was 34.77 ± 0.12 , compared to the standard 27 of good and optimal results $p < 0.0001$. The mean for the Simple Shoulder Test was 11.92 ± 0.08 . Subgroups with and without graft had $p = 0.62$ for the UCLA score and $p = 0.35$ for the Simple Shoulder Test.

Means, standard errors of UCLA and SST, and mean evolution and injury time between subgroups with and without graft are summarized in Table 1. However, since this lesion is rare, the number of individuals is still low to indicate equality between subgroups.

Table 1. Data and comparison of subgroups with and without grafts.

	Graft	No graft	p
Number of patients	7	6	
UCLA Score	34.57 0.30	34.83 0.17	0.35
Simple Shoulder Test	12 0	12 0	0.62
Injury time	24.71 months	Up to 2 weeks	————
Follow-up Time	56.71	92.17	————

One patient developed quadrilateral space syndrome caused by mispositioning of the synthesis material four years after the procedure and required surgical removal of the extruded extremity of the anchor with a diamond drill through the posterior pathway, without compromising pectoral fixation. This patient returned to activities with no functional losses and all the other patients returned to their physical activities with no restrictions. Elevation and external rotation losses were lower than 5° compared to the contralateral side.

DISCUSSION

Pectoralis major tendon rupture is uncommon and has three fixation methods: suture in the enthesis with anchors,³ suture in the enthesis with “endobuttons,”¹² transosseous fixation,¹³ and others less frequent. Transosseous fixation is one of the most frequently used methods, has greater contact with the bone marrow, and possibly the greatest biological potential.¹⁴

The method that uses anchors had the lowest pull-out strength.⁹ On the other hand, transosseous fixations had no significant differences in pullout strength compared to fixations with “endobuttons.”⁹ In this biomechanical study, the anchor bone fixation surface is scarified, weakening the cortical where it is inserted; however, the senior author used anchors through a bone tunnel and fixed in the contralateral cortical bone. According to the standard osteosynthesis technique used for cortical screws, an orifice of similar width to that of the cylindrical shaft of the anchor is made from the inside to the outside of the contralateral cortical bone to avoid losing the thread or breaking the cortical. The wedge design of the anchor helps its thread to create a trail in

the bone with progressive increase in pressure and decreased fragility points, similarly to tapered compression screws.¹⁵ Moreover, the bone elliptical tunnel of the first cortical favors tendon-bone healing, as seen in transosseous points.¹⁴

These results were successful for all cases, with safety and excellent functional recovery. However, the anchor should be carefully inserted, so it does not excessively pass through the contralateral cortical. The anchor usually has a strong handle, typical of cortical bone. To avoid the more medial part of the arm and its neurovascular structures, the anchors should be carefully positioned and introduced in the direction of the triceps, with inclination of at least 30° lateral in relation to the sagittal plane in the posterior cortical while the patient’s arm is in anatomical position. The senior surgeon believes that, except for transosseous points, this positioning is important regardless of the synthesis material used, since it could avoid possible neurological lesions or complications.

Acute lesions show better results when they are operated within three weeks.¹⁶ However, based on our experience, the surgery for chronic lesion using graft did not influence the functional results, with $p = 0.62$ for the UCLA Score and $p = 0.35$ for the Simple Shoulder Test. The senior surgeon increased only the sling time as a precaution. The web arrangement created by the author is somewhat similar to another mentioned in the literature and with a similar function.¹² It interweaves the systems of each graft with the entire distal portion of the muscle, creating a unique mechanism of energy dissipation to protect the graft and improve its fixation to the muscle.

The limitation of this study is the lack of biomechanical studies of pull-out strength which use the fixation technique in the contralateral cortical and the small number of participants, since pectoralis major rupture is an uncommon lesion.

CONCLUSION

The technique of pectoralis major tendon reconstruction with bone tunnel and fixation in the contralateral cortical with anchors proved to be effective, but needs to be carefully executed to avoid complications.

AUTHORS’ CONTRIBUTIONS: Each author contributed individually and significantly to the development of this article. JCGJ: intellectual concept of the article, writing of the article, critical review, and surgeries; EFC: data analysis and critical review; JCGJ, HVL, MPR, MSF, MEK: data acquisition and writing of the manuscript.

REFERENCES

- Patissier P. Traite des maladies des artisans et de celles qui résultent des diverses professions d’après Ramazzini. Paris: J.-B. Baillière; 1822.
- Merolla G, Paladini P, Campi F, Porcellini G. Pectoralis major tendon rupture: surgical procedures review. *Muscles Ligaments Tendons J.* 2012;2(2):96-103.
- Provencher MT, Handfield K, Boniquit NT, Reiff SN, Sekiya JK, Romeo AA. Injuries to the pectoralis major muscle: diagnosis and management. *Am J Sports Med.* 2010;38(8):1693-705.
- Merolla G, Paladini G, Artiaco S, Tos P, Lollino N, Porcellini G. Surgical repair of acute and chronic pectoralis major tendon rupture: clinical and ultrasound outcomes at a mean follow-up of 5 years. *J Orthop Surg Traumatol.* 2015;25(1):91-8.
- Balazs GC, Brelin AM, Donohue MA, Dworak TC, Rue JPH, Giuliani JR, et al. Incidence rate and results of the surgical treatment of pectoralis major tendon ruptures in active – duty military personnel. *Am J Sports Med.* 2016;44(7):1837-43.
- Inhofe PD, Grana WA, Egle D, Min KW, Tomasek J. The effects of anabolic steroids on rat tendon: an ultrastructural, biomechanical, and biochemical analysis. *Am J Sports Med.* 1995;23(2):227-32.
- Garrigues GE, Kraeutler MJ, Gillespie RJ, O’Brien DF, Lazarus MD. Repair of pectoralis major ruptures: single-surgeon case series. *Orthopedics.* 2012;35(8):e1184-90.
- Fung L, Wong B, Ravichandiran K, Agur A, Rindlisbacher T, Elmaraghy A. Three-dimensional study of pectoralis major muscle and tendon architecture. *Clin Anat.* 2009;22(4):500-8.
- Rabuck SJ, Lynch JL, Guo X, Zhang LQ, Edwards SL, Nuber GW, Saltzman MD. Biomechanical comparison of 3 methods to repair pectoralis major ruptures. *Am J Sports Med.* 2012;40(7):1635-40.
- Butt U, Mehta S, Funk L, Monga P. Pectoralis major ruptures: a review of current management. *J Shoulder Elbow Surg.* 2015;24(4):655-62.
- Baverel L, Messedi K, Pietu G, Crenn V, Gouin F. Pectoralis major tear with retracted tendon: how to fill the gap? Reconstruction with hamstring autograft and fixation with an interference screw. *Case Rep Orthop.* 2017;2017:2095407.
- Metzger PD, Bailey JR, Filler RD, Waltz RA, Provencher MT, Dewing CB. Pectoralis major muscle rupture repair: technique using unicortical buttons. *Arthrosc Tech.* 2012;1(1):e119-25.
- Schepsis AA, Grafe MW, Jones HP, Lemos MJ. Rupture of the pectoralis major muscle: outcome after repair of acute and chronic injuries. *Am J Sports Med.* 2000;28(1):9-15.
- Rodeo SA, Arnoczky SP, Torzilli PA, Hidaka C, Warren RF. Tendon-healing in a bone tunnel. A biomechanical and histological study in the dog. *J Bone Joint Surg Am.* 1993;75(12):1795-803.
- Beadel GP, Ferreira L, Johnson JA, King GJW. Interfragmentary compression across simulated scaphoid fracture – analysis of 3 screws. *J Hand Surg.* 2004;29(2):273-8.
- Butt U, Mehta S, Funk L, Monga P. Pectoralis major ruptures: a review of current management. *J Shoulder Elbow Surg.* 2015;24(4):655-62.