EFFECTS OF DECOMPRESSION TIME AFTER SPINAL CORD INJURY ON NEUROLOGIC RECOVERY IN WISTAR RATS

César de César Netto[1], Leonardo Franco Pinheiro Gaia[1], Alexandre Adorno Sattin[1], Alexandre Fogaça Cristante[1], Raphael Martus Marcon[1], Tarcísio Eloy Pessoa de Barros Filho[1], Reginaldo Perilo Oliveira[1], Ivan Dias Rocha[1], Arthur Roncon Dias[1], Clarissa Harumi Omori[2]

ABSTRACT

Objective: Traumatic spinal Cord injuries are common in patients with high-energy trauma, and have significant morbidity and mortality rates, as well as high psychological and social costs, causing a major impact on public health. To date, the treatment of such lesions remains controversial, with various studies in the literature comparing the results of non-surgical treatment with immediate, early or late surgical decompression. The objective of the present study is to compare the results of immediate and early (within 1 hour) spinal Cord decompression. Methods: In the belief that the surgical treatment obtains the best result, this experimental study has a case-control design, with histopathological and functional analysis of the results of surgical treatment of 25 Wistar mice submitted to posterior laminectomy immediately, or after one hour of spinal Cord compression. Results: in terms of functional and neurological deficit, the responses were better in the mice treated with immediate surgical decompression than in those treated one hour after the lesion (p=0.036). Conclusion: The earlier the decompression of spinal Cord injuries is performed, the better the end results in terms of the function and presence of neurological deficit.

Keywords: Spinal cord injuries. Rats, Wistar. Decompression.

Citation: de César Netto C, Gaia LF, Sattin AA, Cristante AF, Marcon RM, Barros Filho TE, et al. Effects of decompression time after spinal cord injury on neurologic recovery in wistar rats. Acta Ortop Bras. [online]. 2010;18(6):315-20. Available from URL: http://www.scielo.br/aob.

INTRODUCTION

Spinal cord injuries entail a profound transformation in the quality and style of life, with impairment of independence and socioeconomic relations of those that suffered the injury; this kind of trauma is very costly for the public health system, due to the high complexity of the procedures carried out in the acute phase of the injury (surgeries, imaging methods, support measures and hospitalization) and long period of treatment and multi-disciplinary follow-up. It generally occurs secondarily to auto accidents, firearm injuries and sharp weapon injuries and diving in shallow water. The initial (primary) traumatic injury typically involves impact, compression and contusion of the spinal cord, and results in immediate damage to the nerve cells, axonal tracts and blood vessels. A lot has been done today in order to reverse and/or minimize the secondary physiological processes, which include hemorrhage, edema, ischemia and hypoxia, influenced by the release of endogenous mediators, promoting cell death by apoptosis and necrosis.[1] In spite of so many efforts, very little progress was made in the neurological recovery of traumatized individuals. Therefore new ideas for supplementary therapeutic intervention have been conceived and studied, including the use of the hyperbaric chamber, activity of new antioxidants and neuronal growth factors and optimization of the decompression time, the latter evaluating whether compressive factors such as bone fragments, ligaments or intervertebral disc can exacerbate the mechanical damage after the primary lesion over time.

There is strong evidence in literature that surgical decompression of the spinal cord and alignment of the vertebral canal in the first days or weeks produces better final neurological recovery in relation to decompressions in more prolonged periods (months or years).[2-6]

What still remains controversial is whether even earlier (within the first hours) decompressions would be beneficial. Considering that the surgery should be performed only after stabilization of the patient's conditions.

All the authors declare that there is no potential conflict of interest referring to this article.

1 – Laboratory of Medical Investigation of the Musculoskeletal System – LIM41 of the Department of Orthopedics and Traumatology of FMUSP
2 – Graduate Student at the School of Medicine of USP (Universidade de Sao Paulo)

Study conducted at the Institute of Orthopedics and Traumatology of Hospital das Clínicas da Faculdade de Medicina da Universidade de São Paulo
Mailing Address: Rua Capote Valente 467, apto. 53, São Paulo, SP. Brazil. CEP 05409-001. E-mail: pinhal_89@yahoo.com.br

Article received on 9/2/09 and approved on 11/8/09

Delamarter et al.[7,8] in a recent study, used of a nylon cable to compress the spinal cord circumference homogenously so as to halve its diameter. He concluded that decompressions within the first hour after injury of the upper thoracic spinal cord in dogs allow considerable recovery, while decompressions at a later stage did not produce significant improvement. This study was based on a method of continuous compression of the spinal cord. Our best model reproduces spinal cord traumas, in which there is an immediate primary lesion followed by non-homogeneous spinal cord compression. Although many authors defend the surgical approach when there is evidence of spinal cord compression,[6,9] several others do not point out advantages of this method over the conservative, non-surgical approach.[10-12] They allege that once the spinal cord has been injured, all the damage is irreversible or when there is neurological recovery, this occurs irrespective of factors such as surgery (including the time between the injury and the decompression), spinal deformity, bone injury mechanism and narrowing of the vertebral canal.

In this study we determined, through histopathological and functional analyses, the effects of the compression time and of the timing of decompression in neurological recovery after spinal cord injury, using a group of animals with immediate decompression after standardized spinal cord trauma and another sustained for a short period (1 hour).

MATERIAL AND METHODS

Lesions were created in 25 rats of the 30 initially estimated, using the NYU IMPACTOR[13] (New York Impactor), with a fall height of 25.0 mm. The rats were divided into 2 groups, whereas 12 underwent immediate decompression after the lesion (Red group), and 13 sustained spinal cord compression for one hour before the decompression (Black group). Five deaths were probably due to the effects of anesthesia (intraperitoneal pentobarbital), even though the application was diluted in saline solution and performed according to dosage standardization by weight and gender. Two of these deaths occurred before the start of the laminectomy, two during the surgical procedures and one in the immediate postoperative period. In addition, there was a sixth death on the 5th postoperative day of unknown cause, hence leaving only 11 rats remaining in the red group. The production of the lesions and the euthanasia of the animals occurred at the Laboratory of Spinal Cord Studies of the Institute of Orthopedics and Traumatology of Faculdade de Medicina da Universidade de São Paulo. The animals were kept in the Laboratory of Spinal Cord Injury Studies of IOT-FMUSP, in individual cages, in air conditioned chambers and under adequate food and hygiene conditions.

The study subjects were male Wistar rats from a single supplier (Bioterium of Faculdade de Medicina da Universidade de Sao Paulo). The rats were 12 weeks of age, weighed from 260g to 340g and were guaranteed pathogen free. Care was taken to ensure the adequate identification of all of them.

Anesthetic Procedures

The rats were anesthetized with intraperitoneal pentobarbital. The dose used was 55-75 mg/kg. The optimal dose may vary depending on many factors, but the anesthetic effect always started in around 5 minutes. This dose of pentobarbital anesthetized the rat for approximately 2 hours. The evaluation of the deep anesthetic plane was determined by the absence of corneal reflexes and tail compression.

Laminectomy

The spinal cord was exposed with a laminectomy for the contusion.

An opening was made in the skin of the dorsal midline to expose T8-T12 of the spinal column.

The muscles inserted in the spinous processes of T10-T11 were cut and separated. The laminectomy of T10 and T9 was performed with pliers, starting from the caudal edge of T10 and delicately removing small fragments along the T10 lamina with the pliers in the cranial direction (a right-handed surgeon operates with the rat's head close to his left hand) up to the T9 lamina. No damage was caused to the spinous process of T8 or the spinal cord (damage to the spinous process of T8 would cause weakening of the site for the positioning of the cranial clamp). The opening, with a minimum margin of 2mm, was sufficient to accommodate the Impactor head.

Contusion

The NYU IMPACTOR was used to bruise the spinal cord and to monitor the contusion. Between contusions, the IMPACTOR head was immersed in a lab beaker with saline solution. The IMPACTOR head was carefully cleaned with a 95% alcohol solution before the contusion.

The rat was positioned in the IMPACTOR. The T8 segment was pinched then the caudal clamp was fastened on the spinous process of the T11 segment. A sponge was placed under the rat's chest. (The rats were suspended by the T8 and T11 segments).

The rod of the IMPACTOR was adjusted at position zero. The base clip was attached to the surgical wound margin.

The rod of the IMPACTOR was centralized and lowered in the direction of the spinal cord, between the upper margin of T9 margin and the lower margin of T10. When the head came into contact with the spinal cord, the IMPACTOR emitted a sound and luminous signal.

The rod of the IMPACTOR was raised to the height of 25.0 mm. The height was inputted in the IMPACTOR program and it was prepared for the acquisition of data.

The IMPACTOR was released to bruise the spinal cord. The rod of the IMPACTOR was raised immediately in the Red group and an hour after the contusion in the Black group.

The rat was removed and placed on a heated surface (not exceeding 38º C). The contusion site was inspected, stanching any hemorrhage. The contusion site was washed with saline solution. The paravertebral muscles were sutured and the skin closed with 3-0 suture thread. (Figure 1)

Procedures in the immediate and late post-lesion period

The rat was transferred to a chamber with controlled temperature (the temperature was kept at around 25-28º C). The purpose of the chamber is to prevent hypothermia).

During the 7 days, the rats received prophylactic antibiotic therapy (cefazolin 25mg/kg) and appropriate basic care, such as food and hygiene, was provided.

The rats' bladders were squeezed on a daily basis, since vesical emptying was necessary due to post-spinal cord lesion autonomic dysfunction, avoiding or attenuating the severity of the vesical distension.

During this period the rats were also weighed and evaluated in terms of the degree of dehydration based on the skin turgor and loss of 15g or more in one or two consecutive days, with the oral administration of saline solution. Going by the urine color (hematuria) it was possible to verify the need for supplementary

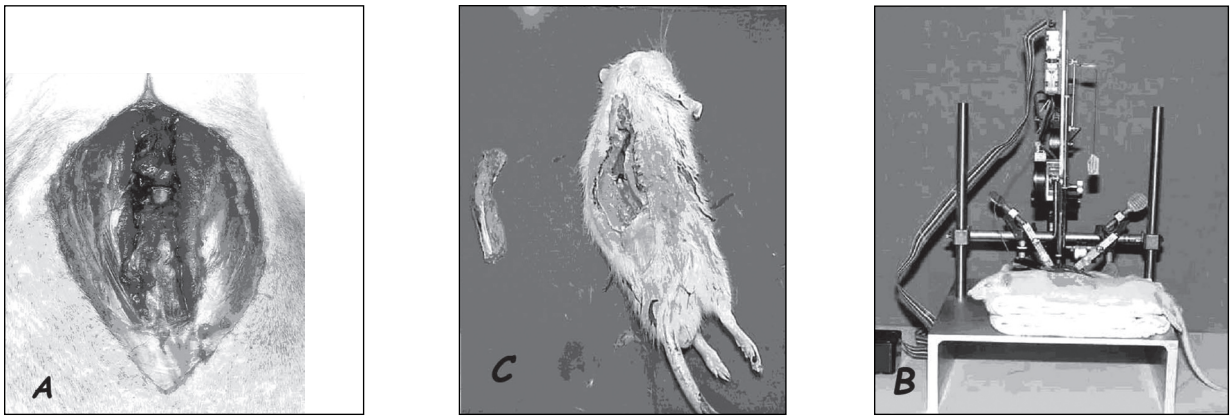

Figure 1 – *A) Route of access to the spinal cord and laminectomy; B) NYU IMPACTOR; C) Resection of the spinal column.*

antibiotic therapy (levofloxacin, 2.5mg/kg) for the therapeutic approach to the urinary infection, which was observed in 15 animals. Regression of hematuria was verified in all the cases in less than two days.

There were 25 functional analyses on the second postoperative day and 24 on the seventh day, following the BBB scale[14,15], that is a scale standardized for evaluation of the motor function in rats based on the assignment of a score according to the individual ability of each animal to move different joints or not, taking into consideration the range and frequency of these movements, enabling subsequent statistical analyses. The observation was made by two properly trained researchers, who reached a consensus in relation to the score, with the purpose of making the analysis more objective. (Chart 1)

Euthanasia and Tissue Samples for Anatomopathological Experiment

Euthanasia was performed one week after the lesion. The procedures for euthanasia and removal of tissue samples were the following:

The rat was weighed to obtain body weight at the time of euthanasia, verifying that all of them had recovered their preoperative initial weight.

Double the dose of pentobarbital used to anesthetize the animal was applied intraperitoneally. This dose was sufficient to provoke euthanasia.

A spinal cord sample was taken for histopathological analysis.

Histopathological and statistical analysis:

The spinal cord was dissected, two segments above and two below the lesion as a safety margin. This material was fixed in a 10% formaldehyde solution, for a minimum time of 72 hours. The spinal cord segment underwent cuts in the axial plane, at intervals of 2mm, with representation of the entire injured area and of the uninjured area, which would serve as internal control. This material was processed in a histotechnical procedure with dehydration in alcohol, hardened in paraffin and stained with hematoxylin and eosin, whereas each cut was between 6 and 9 microns thick. The pathologist, after analyzing the slides, assigned points according to the degree of necrosis, edema, congestion, degeneration of the substance (liquefaction, cavitation) and cell infiltration at the level of the lesion, 2 segments above (cranial) and two segments below (caudal).

Chart 1 – *Functional analysis scale (BBB)*

0: No observable movement of the rear limb;
1: Limited movement of one or more joints, normally the hip and/or the knee;
2: Ample movement of a joint or ample movement of one joint and limited movement of another joint;
3: Ample movement of two joints;
4: Limited movement of three joints of the rear limb;
5: Limited movement of two joints and ample movement of the third;
6: Ample movement of two joints and limited movement of the third;
7: Ample movement of the three joints of the rear limb;
8: Synchronized movement of the three joints, in alternate flexion-extension, without weight bearing or plantar positioning of the rear limb without weight bearing;
9: Plantar positioning of the rear limb with weight bearing only when the animal is at rest or steps leaning on the instep with bearing of body weight (occasional, frequent or consistent) and no step leaning on the sole;
10: Occasional steps leaning on the sole with bearing of body weight, without coordination between fore and hind limb;
11: Frequent or consistent steps leaning on the sole and without coordination between fore and hind limb;
12: Frequent or consistent steps leaning on the sole and occasional coordination between fore and hind limb;
13: Frequent or consistent steps leaning on the sole and frequent coordination between fore and hind limb;
14: Consistent steps leaning on the sole, consistent coordination between fore and hind limb, and hind limb predominantly rotated (medially or laterally) upon contact with the ground and upon leaving the ground;
15: Consistent steps leaning on the sole, consistent coordination between fore and hind limb and nonexistent or occasional weight bearing on the ankles during gait; position of the hind limb predominantly parallel to the body;
16: Consistent steps leaning on the sole, consistent coordination between fore and hind limb and frequent weight bearing on the ankles during gait; position of the hind limb parallel to the body upon initial contact with the ground and rotated medially or laterally upon leaving the ground;
17: Consistent steps leaning on the sole, consistent coordination between fore and hind limb and frequent weight bearing on the ankles during gait; position of the rear limb parallel to the body upon initial contact with the ground and upon leaving the ground;
18: Consistent steps leaning on the sole, consistent coordination between fore and hind limb and consistent weight bearing on the ankles during gait; position of the rear limb parallel to the body upon initial contact with the ground and rotated medially or laterally upon leaving the ground;
19: Consistent steps leaning on the sole, consistent coordination between fore and hind limb and consistent weight bearing on the ankles during gait; position of the rear limb parallel to the body upon initial contact with the ground and upon leaving the ground; the tail is not lifted for part of the time or all the time;
20: Consistent steps leaning on the sole, consistent coordination between fore and hind limb and consistent weight bearing on the ankles during gait; position of the rear limb parallel to the body upon initial contact with the ground and upon leaving the ground; and instability of the trunk; tail consistently elevated;
21: Consistent steps leaning on the sole, consistent coordination between fore and hind limb and consistent weight bearing on the ankles during gait; position of the rear limb parallel to the body during gait; and stable trunk; tail consistently elevated.

E.g.: 0 – without necrosis
1 – small quantity of necrosis
2 – medium quantity of necrosis
3 – large quantity of necrosis

The scores obtained from each criterion going from the analyzed cuts were added up, thus obtaining a score for each rat (between 0 and 15). The scores of the rats from the same group were added up, to thus obtain the score by group.

The statistical analysis of the scores obtained by histopathology and BBB scale was based on the Wilcoxon test and Mann-Whitney U test. Results with p below or equal to 0.05 are considered significant.

EXCLUSION CRITERIA

The 5 animals that died probably due to the effects of the anesthesia were excluded from the study, as no rat developed infection refractory to the antibiotic therapy as explained above and/or important autophagy. A functional analysis was only conducted with the animal from the red group that died on the 5th postoperative (PO) day in the 2nd PO, and it was excluded from the second functional analysis in the 7th PO.

RESULTS

Functional analysis

The spinal cord lesions coincided with the midline, as the functional deficit was symmetrical, impairing the motor function of both the right lower limb and of the left lower limb;

All 48 limbs evaluated (11 animals from the red group and 13 from the black group) on the 2nd and on the 7th postoperative day presented statistically significant improvement of the motor function in this period ($p<0.001$);

The red group, when compared with the black group, presented better neurological recovery between the 2nd and 7th postoperative. There was no significant difference between the two groups in the first functional evaluation ($p=0.104$), while in the 7th PO the red group presented better evaluation by the BBB scale ($p=0.036$). (Charts 2 to 6)

Histopathological analysis

The anatomical lesion was much more pronounced in the fall segment of the Impactor rod than in the segments above and below the lesion. The average score of the two groups at the lesion level was 10.2 (score from 0 to 15), while above the lesion this score was 2.3, and below the lesion, 2.4;

The degree of anatomical lesion was very similar between the segments above and below the lesion;

Chart 2 – *Mann-Whitney test – Comparison of the BBB Scale between Lower Left Limb (LLL) and Lower Right Limb (LRL).*

Ranks

	LL-12	N	Mean ranks	Sum of ranks
2PO	LRL	25	22.82	570.50
	RRL	25	28.18	704.50
	Total	50		
7PO	LRL	24	23.92	574.00
	RRL	24	25.08	602.00
	Total	48		

Test statistics

	2PO	7PO
Mann-Whitney U	245.500	274.000
Wilcoxon W	570.500	574.000
Z	–1.500	–.303
Significance of asymptote (bicaudal)	.134	.762

a. Conclusion: there is no statistical difference between LRL and RRL by the evaluation of the BBB Scale

Chart 3 –*Wilcoxon Test – Red Group: Evolution from 2PO to 7PO by the BBB Scale.*

Ranks

		N	Mean ranks	Sum of ranks
RedLeftSD07 –	Negative ranks	0[a]	.00	.00
RedLeftSD02	Positive ranks	11[b]	6.00	66.50
	Associations	0[c]		
	Total	11		
RedRightSD07 –	Negative Ranks	0[d]	.00	.00
RedRightSD02	Positive Ranks	11[e]	6.00	66.00
	Ties	0[f]		
	Total	11		

a. RedLeftSD07 < RedLeftSD02
b. RedLeftSD07 > RedLeftSD02
c. RedLeftSD02 = RedLeftSD07
d. RedRightSD07 < RedRightSD02
e. RedRightSD07 > RedRightSD02
f. RedRightSD02 = RedRightSD07

Test statistics[b]

	RedLeftSD07 – RedLeftSD02	RedRightSD07 – RedRightSD02
Z	–2.946[a]	–2.944[a]
Significance of asymptote (bicaudal)	.003	.003

a. Conclusion: there was significant improvement between 2PO and 7PO for LRL in the Red Group ($p = 0.003$)
b. There was significant improvement between 2PO and 7PO for RRL in the Red Group ($p = 0.003$)

Chart 4 –*Wilcoxon Test – Black Group – Evolution from 2nd PO to 7th PO by the BBB Scale.*

Ranks

		N	Mean ranks	Sum of ranks
BlackLeftDP07 –	Negative ranks	0[a]	.00	.00
BlackLeftDP02	Positive ranks	13[b]	7.00	91.00
	Associations	0[c]		
	Total	13		
BlackRightSD07 –	Negative ranks	0[d]	.00	.00
BlackRightSD02	Positive ranks	13[e]	7.00	91.00
	Associations	0[f]		
	Total	13		

a. BlackLeftSD07 < BlackLeftSD02
b. BlackLeftSD07 > BlackLeftSD02
c. BlackLeftSD02 = BlackLeftSD07
d. BlackRightSD07 < BlackRightSD02
e. BlackRightSD07 > BlackRightSD02
f. BlackRightSD02 = BlackRightSD07

Test statistics[b]

	BlackLeftSD07 – BlackLeftSD02	BlackRightSD07 – BlackRightSD02
Z	–3.203[a]	–3.190[a]
Significance of asymptote (bicaudal)	.001	.001

a. Conclusion: There was significant improvement between 2PO and 7PO for LRL in the Black Group ($p = 0.001$)
b. There was also significant improvement between 2PO and 7PO for RRL in the Black Group ($p = 0.001$)

Chart 5 – *Wilcoxon test – Total Group (Red Group + Black Group) – Evolution of the BBB Scale from the 2nd PO to the 7th PO.*

Ranks

		N	Mean ranks	Sum of ranks
7PO – 2PO	Negative ranks	0[a]	.00	.00
	Positive ranks	48[b]	24.50	1176.00
	Associations	0[c]		
	Total	48		

a. 7PO < 2PO
b. 7PO > 2PO
c. 2PO = 7PO

Test statistics[b]

	7PO - 2PO
Z	–6.054[a]
Significance of asymptote (bicaudal)	.000

a. Conclusion: there was significant improvement between 2PO and 7PO
b. p < 0.001

Chart 6 – *Mann-Whitney Test – Comparison between the Red and Black groups.*

Ranks

	Group 12	N	Mean ranks	Sum of ranks
2PO	Red	24	28.52	684.50
	Black	26	22.71	590.50
	Total	50		
7PO	Red	22	28.89	635.50
	Black	26	20.79	540.50
	Total	48		

Test statistic[a]

	2PO	7PO
Mann-Whitney U	239.500	189.500
Wilcoxon W	590.500	540.500
Z	–1.624	–2.093
Significance of asymptote (bicaudal)	.104	.036

a. Conclusions: The Red group presents better evaluation by the BBB Scale on 7PO when compared with the Black group (p = 0.036). There is no difference between the two groups on 2PO (p = 0.104).

At the level of the lesion, the group that underwent immediate decompression obtained a larger anatomical lesion than the group that suffered decompression after one hour, with p=0.056;
Above the lesion, the group that underwent immediate decompression obtained a larger anatomical lesion than the group that suffered decompression after one hour, with p=0.099;
Below the lesion, the group that underwent immediate decompression obtained a larger anatomical lesion than the group that underwent decompression after one hour, with p=0.046.

DISCUSSION

For a study to be conducted, attention should be paid to the choice of an adequate, applicable and standardized methodology, simulating traumatic spinal cord lesion in humans.
The animals of preference would ideally be the primates, yet their use is limited due to cost, availability and ethical issues. The choice of Wistar[16] rats is due to the spinal cord vascularization, similar to that of humans, availability in our field, low cost in acquisition and maintenance, need for small spaces and ease in the obtainment of litters with controlled weight and age.
The weight drop model is the most extensively used in the study of traumatic spinal cord lesion, and the one that most closely resembles traumatic lesion in human beings. This model consists of the free fall of a known mass from a pre-established height on the surgically exposed spinal cord. The New York University Impactor is a computerized system of this model, resulting in standardized contusions and the obtainment of homogeneous and reliable data.
The BBB scale, used for the performance of the functional analysis, is widely adopted to evaluate post-spinal cord lesion neurological recovery in rats. It is of easy application and allows users to assign scores objectively, with little interobserver variation, making it possible not only to evaluate the neurological deficit of the animal upon observation, but also to monitor its evolution. It is a comprehensive method, in which the main joints of the lower limb, stability of the trunk and tail suspension, are verified in various criteria (amplitude, frequency, coordination and consistency).
The results obtained with the statistical analysis showed that the group that underwent immediate decompression after the spinal cord contusion presented better neurological recovery over one week of observation, with better evaluation on the 7th postoperative day than the group that sustained the compression for 1 hour before the decompression (p=0.036). It was also verified that on the 2nd postoperative day the two groups did not present significant difference in relation to neurological evaluation.
As regards the anatomopathological analysis, the value of p (α error) obtained at the level of the lesion (0.056), above (0.099) and below (0.046) was very close to the acceptable cutoff value (0.05). These results suggest that the anatomical lesion is more important in the group that underwent immediate decompression after the spinal cord contusion. However, in this case, with the sampling used it was not possible to conclude with statistical significance on any difference between immediate decompression and decompression after 1 hour based on this analysis.
Both groups were submitted to identical primary lesions (dropping of the rod). The differential between them is in the secondary lesion, represented by the prolonged suspension of the rod. The worse recovery in the group with decompression after 1 hour is probably due to the intensity and duration of the processes involved in the latter type of lesion. Persistent spinal cord compression, even if for a short period of time, may be provoking a more prolonged period of ischemia, leading to the decrease of axoplasmic flow and tissue necrosis with fragmentation of axons and surrounding myelin. Moreover, greater edema, inflammatory infiltrate, release of inflammatory mediators and hemorrhage are also presumably contributing toward the progression of the lesion, accentuating for ischemia, necrosis and fibrosis, and hampering axonal regeneration.
These results, evidencing the benefits of a surgical decompression of the vertebral canal as early as possible, are in line with other experimental studies on animals, in which other spinal cord lesion methods and other decompression periods were used.[17,18]
This study stresses the importance of early surgical treatment. This approach could be lessening comorbidities related to spinal cord trauma (impaired walking, bedriddenness, emotional

changes, neurological deficit, etc.), resulting in a shorter hospitalization time, lower costs and socioeconomic dependence and enabling better quality of life for the patient.

Besides the optimization of the decompression time, other supporting techniques are considered in recent studies with the intention of further minimizing the neuronal lesion and of producing better functional axonal regeneration.[19-26] Among the new techniques, special emphasis is placed on stem cell implantation, the use of new medications (anti-inflammatory drugs, axon regeneration promoters, apoptosis inhibitors), interference in oxidoreduction (hyperbaric chamber, vitamin C), cryotherapy, etc.

CONCLUSION

The earlier the surgical decompression of the vertebral canal, the better the final neurological recovery. These results obtained in rats suggest the applicability of this technique in humans.

REFERENCES

1. Rhoney DH, Luer MS, Hughes M, Hatt J. New pharmacologic approaches to acute spinal cord injury. Pharmacotherapy. 1996;16: 382-92.
2. Papadopoulos SM, Selden NR, Quint DJ, Patel N, Gillespie B, Grube S. Immediate spinal cord decompression for cervical spinal cord injury: feasibility and outcome. J Trauma. 2002;52:323-32.
3. Mirza SK, Krengel WF, Chapman JR, Anderson PA, Bailey JC, Grady MS, et al. Early versus delayed surgery for acute cervical spinal cord injury. Clin Orthop Relat Res. 1999;(359):104-14.
4. Fehlings MG, Tator CH. An evidence-based review of decompressive surgery in acute spinal cord injury: rationale, indications, and timing based on experimental and clinical studies. J Neurosurgery. J Neurosurg. 1999;91(1 Suppl):1-11.
5. Bailey RW, Badgley CE. Stabilization of the cervical spine by anterior fusion. J Bone Joint Surg Am. 1960;42:565-94.
6. Zhu H, Feng YP, Young W, You SW, Shen XF, Liu YS, et al. Early neurosurgical intervention of spinal cord contusion: an analysis of 30 cases. Chin Med J (Engl). 2008;121:2473-8.
7. Delamarter RB, Coyle J. Acute management of spinal cord injury. J Am Acad Orthop Surg. 1999;7:166-75.
8. Delamarter RB, Sherman J, Carr JB. Pathophysiology of spinal cord injury. J Bone Joint Surg Am. 1995;77:1042-49.
9. Bohlman HH. Current concepts review. Treatment of fractures and dislocations of the thoracic and lumbar spine. J Bone Joint Surg Am. 1985;67:165-9.
10. Donovan WH, Cifu MD, Schotte DE. Neurological and skeletal outcomes in 113 patients with closed injuries to the cervical spinal cord. Paraplegia. 1992;30:533-42.
11. Bucholz RD, Cheung KC. Halo vest versus spinal fusion for cervical spinal injury: evidence from an outcome study. J Neurosurg. 1989;70:884-92.
12. Tator CH, Duncan EJ, Edmonds VE, Lapczak LI, Andrews DF. Comparison of surgical and conservative management in 208 patients with acute spinal cord injury. Can J Neurol Sci. 1987;14:60-9.
13. New York University, Medical Center. IMPACTOR NYU spinal cord contusion system. Operation manual. Impactor software version 7.0. New York, 1993; 41p.
14. Basso DM, Beattie MS, Bresnahan JC. A sensitive and reliable locomotor rating scale for open field testing in rats. J Neurotrauma. 1995;12:1-21.
15. Barros Filho TE, Molina AE. Analysis of the sensitivity and reproducibility of the Basso, Beattie, Bresnahan (BBB) scale in Wistar rats. Clinics (Sao Paulo). 2008;63:103-8.
16. Rodrigues NR. Padronização da lesão de medula espinal em ratos Wistar [tese]. São Paulo: Faculdade de Medicina da Universidade de São Paulo; 1999.
17. Zhang HQ, Li KH, Long WR. Anterior approach in the surgical treatment of cervical fracture and spinal cord injury. Hunan Yi Ke Da Xue Xue Bao. 2002;27:139-42.
18. Silber VS, Vaccaro AR. Summary statement: The role and timing of decompression in acute spinal cord injury: Evidence based guidelines. Spine (Phila Pa 1976). 2001;26(24 Suppl):S110.
19. Lee KD, Chow WN, Sato-Bigbee C, Graf M, Graham RS, Young H, et al. FTY720 reduces inflammation and promotes functional recovery after spinal cord injury. J Neurotrauma. 2009; 26:2335-44
20. Torres S, Salgado-Ceballos H, Guizar-Sahagún G, Torres JL, Orozco-Suarez S, Diaz-Ruiz A, et al. Deleterious versus neuroprotective effect of metabolic inhibition after traumatic spinal cord injury. Spinal Cord. 2009;47:745-50.
21. Tian DS, Liu JL, Xie MJ, Zhan Y, Qu WS, Yu ZY, et al. Tamoxifen attenuates inflammatory-mediated damage and improves functional outcome after spinal cord injury in rats. J Neurochem. 2009;109:1658-67.
22. Zeman RJ, Bauman WA, Wen X, Ouyang N, Etlinger JD, Cardozo CP. Improved functional recovery with oxandrolone after spinal cord injury in rats. Neuroreport. 2009;20:864-8.
23. Hook MA, Moreno G, Woller S, Puga D, Hoy K Jr, Balden R, et al. Intrathecal morphine attenuates recovery of function after a spinal cord injury. J Neurotrauma. 2009;26:741-52.
24. Wang X, Budel S, Baughman K, Gould G, Song KH, Strittmatter SM. Ibuprofen enhances recovery from spinal cord injury by limiting tissue loss and stimulating axonal growth. J Neurotrauma. 2009;26:81-95.
25. Ha KY, Kim YH. Neuroprotective effect of moderate epidural hypothermia after spinal cord injury in rats. Spine (Phila Pa 1976). 2008;33:2059-65.
26. Ha KY, Kim YH, Rhyu KW, Kwon SE. Pregabalin as a neuroprotector after spinal cord injury in rats. Eur Spine J. 2008;17:864-72.