

# COMPARISON OF TOTAL HIP ARTHROPLASTY IN OSTEOARTHRITIS OF MECHANICAL AND RHEUMATOLOGIC CAUSES

LEANDRO EJNISMAN<sup>1</sup>, NATHALIA ZALC LEONHARDT<sup>1</sup>, LAURA FILLIPINI LORIMIER FERNANDES<sup>1</sup>, MARCOS DE CAMARGO LEONHARDT<sup>1</sup>, JOSÉ RICARDO NEGREIROS VICENTE<sup>1</sup>, ALBERTO TESCONI CROCI<sup>1</sup>

## ABSTRACT

**Objective:** To compare the use of uncemented implants in total hip arthroplasty in patients with rheumatologic diseases and mechanical osteoarthritis. **Methods:** We retrospectively evaluated 196 patients who were operated by the Hip and Arthroplasty Surgery Group of the IOT-HCFMUSP between 2005 and 2009. Patients were divided into two groups: mechanical causes (165 patients) and rheumatologic causes (31 patients). Groups were compared between each other in age, gender and follow-up time. Osseointegration rate and percentage of failure in arthroplasty

were evaluated. **Results:** No statistically significant difference was found in osseointegration rates (in both femoral and acetabular components) in both groups. The rates of revision surgery and implant survival also did not show statistically significant differences. **Conclusion:** The use of uncemented total hip arthroplasty did not show worse results in rheumatologic patients. **Level of Evidence III, Retrospective Case Control Study.**

**Keywords:** Arthroplasty, replacement, hip. Arthritis, rheumatoid. Cementation. Osseointegration.

**Citation:** Ejnisman L, Leonhardt NZ, Fernandes LFL, Leonhardt MC, Vicente JRN, Croci AT. Comparison of total hip arthroplasty in osteoarthritis of mechanical and rheumatologic causes. *Acta Ortop Bras.* [online]. 2014;22(1):38-42. Available from URL: <http://www.scielo.br/aob>.

## INTRODUCTION

Osteoarthritis of the hip leads to chronic pain that generates functional disability. Its incidence is estimated to be 500,000 new cases per year in the Caucasian American population.<sup>1</sup> The goal of the treatment of osteoarthritis of the hip is to reduce pain and improve function. Initially, the treatment is done conservatively, by changes in lifestyle, weight loss, physical therapy and drugs such as analgesics, non-steroidal anti-inflammatory drugs and chondroprotectors. However, in a number of cases, conservative treatments are not successful and there is a need of surgical treatment. Among established surgical treatments, the first method of choice is total hip arthroplasty, approximately 170,000 total hip arthroplasties being performed annually in US.<sup>2</sup> Hip arthroplasties were, at the beginning, all performed by the cemented technique. However, studies with long term follow-up evaluating cemented acetabular components showed rates of aseptic loosening of this component varying between 1% and 42%, tending to increase over time, especially after ten years of surgery.<sup>3,4</sup> These facts motivated the emergence and development of uncemented acetabular components, which have

been used in total hip arthroplasty for nearly two decades. An extensive published literature supports the use of uncemented implants, although the follow-up time in these papers is shorter than the case series with cemented prostheses. In a literature review, considering a uncemented implant, totalizing 2428 arthroplasties with a mean follow-up period of 7 years, the results obtained were 0.4% of loosening; 0.3% revision for aseptic loosening; 4.7% total reoperation; and 5% periacetabular osteolysis.<sup>5,6</sup>

When assessing the durability of femoral components, uncemented arthroplasties allow implant survival of 10 to 20 years, depending on the adequacy of form and materials developed in the course of technological medical advances. This time span is comparable to cemented femoral arthroplasties, with the additional advantage of greatly reducing the risk of intraoperative hemodynamic complications arising from the cementing process.<sup>7-9</sup>

Despite the advances of uncemented prosthesis, there is still a discussion in the literature regarding the use of this model in patients with osteoarthritis from rheumatologic causes, mainly

All the authors declare that there is no potential conflict of interest referring to this article.

1. Instituto de Ortopedia e Traumatologia do Hospital das Clínicas da Faculdade de Medicina da Universidade de São Paulo, São Paulo, SP, Brasil.

Work performed at the Laboratory of Muscle-Skeletal Research (LIM 41), Departamento de Ortopedia e Traumatologia da Faculdade de Medicina da Universidade de São Paulo, São Paulo, SP, Brazil.

Correspondence: Marcos de Camargo Leonhardt, Rua Sena Madureira 1245, ap 111, São Paulo, SP, Brazil. 04021-051. marcos\_leon85@yahoo.com

Article received in 06/18/2013, approved in 09/25/2013.

rheumatoid arthritis.<sup>10,11</sup> However, there is consensus that the results of arthroplasty in these patients are worse.<sup>12</sup>

The experience of our service is that uncemented implant can be used in such patients.<sup>13</sup> The objective of this study is to compare the osseointegration of the acetabular and femoral components, and acute complications of 196 patients operated of osteoarthritis of the hip due to rheumatic and non-rheumatic causes in our department.

## CASES AND METHODS

Were evaluated, retrospectively, 196 patients through analysis of medical records and imaging tests. They underwent total hip arthroplasty with the same prosthesis type and same surgical technique used by the Hip Surgery Group, Instituto de Ortopedia e Traumatologia, Hospital das Clínicas da Faculdade de Medicina, Universidade de São Paulo in the period 2005-2009. These patients were divided into two groups according to the cause of hip osteoarthritis: mechanical or rheumatic osteoarthritis.

As mechanical causes of osteoarthritis of the hip the following conditions were considered: primary osteoarthritis, osteonecrosis of the femoral head, sequela of development dysplasia of the hip, sequela of epifisiolistas, Perthes sequela, sequelae to trauma and infection. The following conditions were considered rheumatologic causes of osteoarthritis of the hip: rheumatoid arthritis, juvenile rheumatoid arthritis, ankylosing spondylitis, systemic lupus erythematosus and psoriatic arthritis.

Patients who underwent arthroplasty with prosthesis models other than patients with femoral neck fracture, and revision arthroplasties were not included. Were also excluded from the study patients who failed follow for any reason within one year. The present study is two-tailed, being our H0 null hypothesis equality of osseointegration of the arthroplasty components of both patient groups, and our alternative hypothesis H1 a difference between them.

Surgical approaches used in surgery were the direct lateral approach (Hardinge) and the posterior approach. An uncemented acetabular component made of a porous titanium alloy coated with hydroxyapatite (MBA, Lépine®) was used. The used femoral component was the uncemented stem made of porous titanium alloy with hydroxyapatite (Targos, Lépine®) proximal cover. A polyethylene insert and a 28mm stainless steel modular femoral head were used. Infectious prophylaxis was achieved in all patients with cefuroxime 1.5 mg administered intravenously at induction of anesthesia, and repeated every 12h for 24h. Anti-thrombotic mechanical prophylaxis was done through motor and drug physiotherapy with subcutaneous enoxaparin 40mg per day for 30 days.

After discharge patients were evaluated at 3 weeks, 6 weeks, 12 weeks, 6 months, 1 year, and annually thereafter. The analysis was made by reviewing medical records. Preoperative radiograph was used for the assessment of bone quality by Dorr *et al.*<sup>14</sup> classification. Radiographs of the immediate postoperative period and radiograph of the last postoperative follow up were evaluated by three independent senior surgeons for the presence of signs of occurrence of osseointegration and implant migration, suggesting its loosening. (Table 1)

Acetabular osseointegration was considered through the presence of three of the five signs listed below,<sup>15</sup> in asymptomatic patients in the first year postoperatively evaluation, concomitant to the absence of radiographic signs of acetabular migration:

1. Presence of bone condensation in the superolateral region of the surface of the acetabular component (zone 1 of DeLee and Charnley);
2. Presence of bone condensation in the lower inferomedial region of the surface of the acetabular component (zone 3 of DeLee and Charnley);
3. Absence of radiolucent lines thicker than 1mm and involving at least two adjacent zones of the surface of the acetabular component;
4. Presence of decreased radiographic density in the medial region of the surface of the acetabular component (zone 2 of DeLee and Charnley); and
5. Presence of radial trabecular bones, perpendicular to the surface of the acetabular component in zones 1 or 2 of DeLee and Charnley.

The migration of the acetabular component was defined by the change in the abduction angle greater than 5° and change in the position of the implant in the horizontal or vertical axis, equal or greater than 3 mm,<sup>16</sup> considering as an horizontal parameter the bilacral line and as vertical parameter Kohler's line (Kohler's bisector tear).

The evaluation of the femoral component is performed as described by Engh *et al.*<sup>17</sup> (Table 2)

**Table 1.** Dorr<sup>14</sup> Classification for bone quality.

Dorr	Radiographic aspect
A	Thick femoral cortical in two radiographic views (anteroposterior and lateral "cross table")
B	Thick cortical in anteroposterior view and tapering of posterior cortical in lateral view
C	Narrow cortical in all views

**Table 2.** Engh<sup>17</sup> criteria for osseointegration of uncemented femoral stems.

Fixation scales	1. Presence of lines or lucence on the porous interface	- Present in >50%: 5 points less
		- Absent: 5 points more
	2. Presence of "spot welds"	- Present in <50%: 0 points
		- Present: 5 points more
Stabilization scales	1. Presence of lines or lucence on the interface	- Absent: 2.5 points less
		- Undetermined: 0 points
		- Present in > 50%: 3.5 points less
	2. Presence of pedestal	- Absent: 5 points more
		- Unstable: 3.5 points less
		- Stable : 0 points
	3. Remodeling of the calcaneum	- Hypertrophic: 4 points less
		- Atrophic: 3 points more
	4. Stem migration	- Present: 5 points less
		- Absent: 3 points more
- undetermined: 0 points		
5. Loose particles of the porous surface	- Present: 5 points less	
	- Absent: 1 point more	

After application of the score system proposed by Engh, the femoral stems were considered osseointegrated (score equal or greater than 0 points) or not osseointegrated (score lower than 0 points).

The groups were also compared for the presence of complications: pain, neurologic injury, vascular injury, presence of post-operative infection, presence of arthroplasty dislocation, need for revision of any components, deep vein thrombosis, and/or pulmonary thromboembolism and periprosthetic fractures. Data with normal distribution were analyzed using parametric tests. Nominal data were divided into 2x2 contingency tables and evaluated by Pearson's chi-square test or Fisher exact test, when necessary. The significance level was 0.05. The Epiinfo® 3.5.4 software (CDC - U.S./Atlanta) was used to perform the statistical analyzes.

## RESULTS

Total hip arthroplasties were performed in 196 patients, and of these 31 had osteoarthritis of the hip due to rheumatic diseases. The patients' overall mean age was 52.43 years old with standard deviation of 16.15 years old. The mean age of patients with osteoarthritis of the hip due to rheumatic diseases was 42.03 years old with a standard deviation of 13.46. In patients with hip mechanical disease, the mean age was 54.98 years old and standard deviation 14.18. The difference between both groups was statistically significant ( $P < 0.05$ ).

Of the total sample 44.38% were women, among rheumatologic patients, 41.93% were females and in the group of mechanical diseases, 44.84% belonged to this gender. There was no statistically significant difference between the two groups ( $p = 0.46$ ). The disease had bilateral presentation in 25.51% of the sample group, and the occurrence of bilateralism was 38.7% among rheumatoid patients and 23.03% in the control group. This difference was not statistically significant ( $p = 0.06$ ).

The mean follow-up time of patients in the mechanical disorders group was 39 months with a standard deviation of 16.1 months. In the group of rheumatic diseases the mean follow-up was also 39 months, but with a standard deviation of 16.4 months. These data showed no statistical difference.

Among the causes considered rheumatologic, fourteen patients had ankylosing spondylitis, twelve had rheumatoid arthritis, two had juvenile rheumatoid arthritis, two had psoriatic arthritis and two had systemic lupus erythematosus. (Figure 1)

Among the mechanical causes, the distribution obtained showed 70 cases of primary osteoarthritis, 60 of osteonecrosis of the femoral head, nine posttraumatic, five post-infection, fifteen sequelae of developmental dysplasia of the hip five sequelae of Legg- Calvé-Perthes and one sequela to epifisiolistasis. (Figure 2) Bone quality presented in the total sample group observed was 37.24% Dorr A; 34.18% Dorr B; and 28.57% Dorr C. Among rheumatologic patients, none showed bone quality considered type A by the Dorr Classification system, 29.03% showed Dorr B and 70.96% Dorr C. Among the mechanical causes 44.24% were Dorr A, 35.15% Dorr B and 20.60% Dorr C. The difference between the distributions of bone quality between the groups was statistically significant, with  $p < 0.05$ . (Figure 3)

Regarding osseointegration of the acetabular component, there were four failures of osseointegration (2% of the total), three in the group of mechanical disorders (1.8%) and one in the

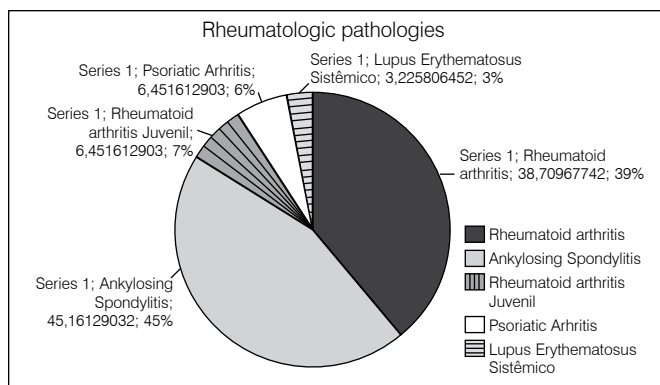


Figure 1. Rheumatologic pathologies in the sample.

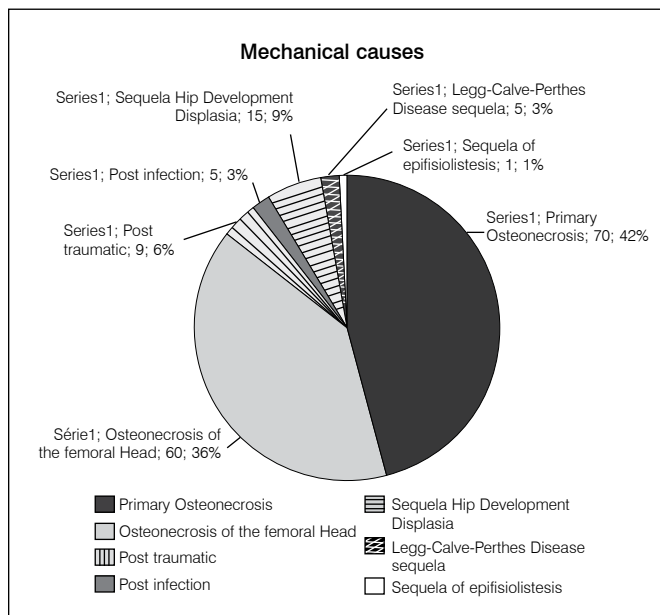


Figure 2. Mechanical pathologies in the sample.

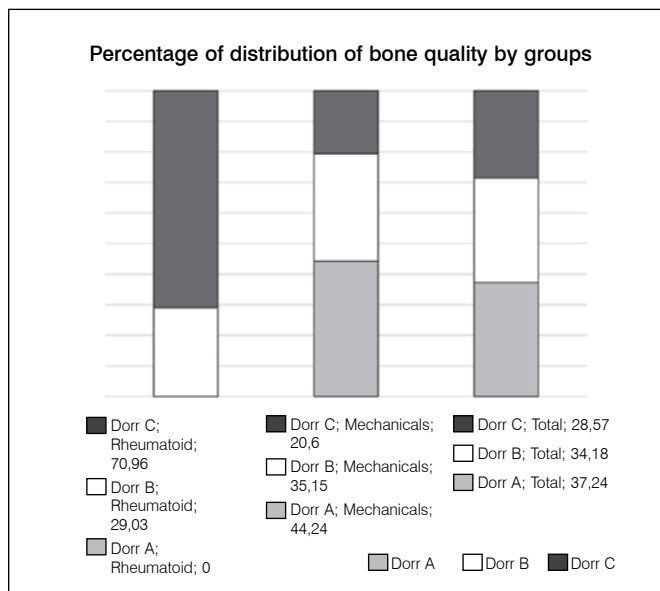


Figure 3. Distribution according to bone quality (Dorr).

group of rheumatic diseases (3.2%). There was no statistically significant difference in these data. ( $p > 0.05$ )

The osseointegration of the femoral component, by the criteria already described, did not occur in only two patients, and all of them belonged to the group whose osteoarthritis was attributed to a mechanical factor (1.2% of the mechanical group, and 1% of the total). It is important to note that these two patients also showed lack of integration of the acetabular component.

There was need for revision of the total hip arthroplasty in four patients with acetabular loosening. Three of these were part of the group of mechanical diseases and all of them had septic loosening of the prosthesis, two of them showed no femoral osseointegration (patients already mentioned in the previous paragraph) and a third patient with failure on acetabular osseointegration and fixed femoral. The patient group of rheumatic diseases, who required revision, had aseptic loosening of the acetabular component of the prosthesis, with fixed femoral component. With these data, we found that the survival rate of the implants in the rheumatic diseases group was 96.8% and in the group of mechanical disorders was 98.2%. There was no statistical difference ( $p > 0.05$ ). (Table 3)

Fourteen patients showed fractures during the surgical procedure, of these, eleven belonged to the group of mechanical causes and three to the rheumatic group. The percentage of fractures in the rheumatologic group was 9.67% and in the group of mechanical causes it was 6.66%. This difference was not significant ( $p > 0.05$ ).

**Table 3.** Patients with revision needs.

#	Gender	Age (years)	Group	Pathology	Cause of revision	Loosen/reviewed component
1	Male	53	Mechanical	Perthes' Sequela	Infection	Both / Both
2	Male	27	Rheumatologic	Juvenile Rheumatoid Arthritis	Aseptic Loosening	Acetabulum / acetabulum
3	Female	75	Mechanical	Primary osteoarthritis	Infection	Both / Both
4	Female	32	Mechanical	DDQ Sequela	Infection	Acetabulum /both

## DISCUSSION

Both groups showed a similar distribution by gender, laterality and follow up time, showing that there was no sample selection bias. We observed, however, a lower mean age in the rheumatology group, a fact predicted by some authors with a trend to early surgical treatment in these patients.

At first, it may be surprising that there was no statistical difference regarding the gender of the patients, since when speaking in rheumatologic diseases the main disease is rheumatoid arthritis, which is more common in younger women, and mechanical pathologies, which has as main disease primary osteoarthritis, more common in the elderly.

Specifically noting the present sample, we have as main rheumatic cause ankylosing spondylitis, which is more common in younger men. Regarding the age of patients, it was also expected that rheumatic diseases would be mostly cured in younger patients than mechanical pathologies.

However, the main cause in the group of mechanical pathologies is osteonecrosis of the femoral head, which unlike primary osteoarthritis, requires earlier surgical intervention. It has been noticed that the mean age of all patients was 52 years old, well below the usual mean age for hip arthroplasty.<sup>18,19</sup>

Patients in the group of rheumatic diseases showed worse bone quality, according to Dorr criteria, than the patients in the mechanical disorders group. This fact is well justified taking into account that the vast majority of rheumatic diseases present with osteopenia. Osteopenia is caused mainly by the use of corticosteroids, as well as by the patient's low demand, and metabolic changes due to the disease. Such changes do not occur so markedly in mechanical pathologies.

No difference was observed regarding osseointegration of the implant components, either femoral or acetabular. We observed equivalent rates of need for revision and intraoperative fractures. This differs from the consensus that not cemented implants should not be used in patients with rheumatologic diseases, with the risk of major complications and premature failure of the implant.

In our experience, patients with rheumatic diseases have similar outcome after uncemented hip arthroplasties, even with impaired bone quality and increased risk of infection (by the inherent immunosuppression of the disease and the use of immunosuppressive drugs to its control).

Furthermore, the use of uncemented implants decreases almost totally the risk of hemodynamic complications, common during the cementing process, being a significant advantage. The survival rate of implants also showed no statistical difference between the groups (96.8% in the rheumatic diseases group, and 98.2% in the mechanical disorders group) and is comparable to the survival rates of implants reported in the literature, ranging from 97.5 to 100% in 10 years follow up.<sup>20</sup> Still, it is worth noting that in worldwide literature, infection cases are usually not included in the series, which did not occur in this study. If infection cases would have been excluded, the survival rate would have been even higher.

## CONCLUSION

The result of this study suggests that there are no difference between the results obtained in uncemented total hip arthroplasty, among rheumatologic patients and not rheumatic, although this result is contrary to the consensus on the use of cemented hip prosthesis in patients with poor bone quality.

In our experience, we observed a successful osseointegration of similar components in both groups, a similar prevalence of immediate and late complications, as well as the prosthesis survival. With these data, we suggest that more studies are performed to determine the equivalence of outcomes between the use and cemented and uncemented prostheses in rheumatologic patients, since no cementing represents a decrease of operative risks.

## REFERENCES

1. Wilson MG, Michet CJ Jr, Ilstrup DM, Melton LJ 3rd. Idiopathic symptomatic osteoarthritis of the hip and knee: a population-based incidence study. *Mayo Clin Proc.* 1990;65(9):1214-21.
2. Kurtz S, Mowat F, Ong K, Chan N, Lau E, Halpern M. Prevalence of primary and revision total hip and knee arthroplasty in the United States from 1990 through 2002. *J Bone Joint Surg Am.* 2005;87(7):1487-97.
3. Charnley J. The long-term results of low-friction arthroplasty of the hip performed as a primary intervention. *J Bone Joint Surg Br.* 1972;54(1):61-76.
4. Martell JM, Pierson RH 3rd, Jacobs JJ, Rosenberg AG, Maley M, Galante JO. Primary total hip reconstruction with a titanium fiber-coated prosthesis inserted without cement. *J Bone Joint Surg Am.* 1993;75(4):554-71.
5. Callaghan JJ, Gaffey JL, Goetz DD. Cementless acetabular fixation at 15 years with the HG1 cup: comparison to the gold standard Charnley. Paper presented at the American Association of Hip and Knee Surgeons 12th Annual Meeting; Dallas, TX; 2002.
6. Soto MO, Rodriguez JA, Ranawat CS. Clinical and radiographic evaluation of the Harris-Galante cup: incidence of wear and osteolysis at 7 to 9 years follow-up. *J Arthroplasty.* 2000;15(2):139-45.
7. Engh CA Jr, Culpepper WJ 2nd, Engh CA. Long-term results of use of the anatomic medullary locking prosthesis in total hip arthroplasty. *J Bone Joint Surg Am.* 1997;79(2):177-84.
8. Schramm M, Keck F, Hohmann D, Pitto RP. Total hip arthroplasty using an uncemented femoral component with taper design: outcome at 10-year follow-up. *Arch Orthop Trauma Surg.* 2000;120(7-8):407-12.
9. Gröbl A, Chiari C, Gruber M, Kaider A, Gottsauner-Wolf F. Cementless total hip arthroplasty with a tapered, rectangular titanium stem and a threaded cup: a minimum ten-year follow-up. *J Bone Joint Surg Am.* 2002;84(3):425-31.
10. Hanssen AD, Cabanela ME, Michet CJ. Hip arthroplasty in patients with systemic lupus erythematosus. *J Bone Joint Surg Am.* 1987;69(6):807-14.
11. Zangger P, Gladman DD, Urowitz MB, Bogoch ER. Outcome of total hip replacement for avascular necrosis in systemic lupus erythematosus. *J Rheumatol.* 2000;27(4):919-23.33.
12. Unger AS, Inglis AE, Ranawat CS, Johanson NA. Total hip arthroplasty in rheumatoid arthritis. A long-term follow-up study. *J Arthroplasty.* 1987;2(3):191-7.
13. Vicente JR, Ulhoa CA, Katz M, Addeo RD, Croci AT. A comparative study of "plasmacup" and "porous-coated" acetabular components: survival after 10 to 12 years of follow-up. *Clinics (Sao Paulo).* 2010;65(11):1111-4.
14. Dorr LD, Kane TJ 3rd, Conaty JP. Long-term results of cemented total hip arthroplasty in patients 45 years old or younger. A 16-year follow-up study. *J Arthroplasty.* 1994;9(5):453-6.
15. Moore MS, McAuley JP, Young AM, Engh CA Sr. Radiographic signs of osseointegration in porous-coated acetabular components. *Clin Orthop Relat Res.* 2006;444:176-83.
16. Callaghan JJ, Salvati EA, Pellicci PM, Wilson PD Jr, Ranawat CS. Results of revision for mechanical failure after cemented total hip replacement, 1979 to 1982. A two to five-year follow-up. *J Bone Joint Surg Am.* 1985;67(7):1074-85.
17. Engh CA, Massin P, Suthers KE. Roentgenographic assessment of the biologic fixation of porous-surfaced femoral components. *Clin Orthop Relat Res.* 1990;(257):107-28.
18. Jana AK, Engh CA Jr, Lewandowski PJ, Hopper RH Jr, Engh CA. Total hip arthroplasty using porous-coated femoral components in patients with rheumatoid arthritis. *J Bone Joint Surg Br.* 2001;83(5):686-90.
19. Eskelinen A, Paavolainen P, Helenius I, Pulkkinen P, Remes V. Total hip arthroplasty for rheumatoid arthritis in younger patients: 2,557 replacements in the Finnish Arthroplasty Register followed for 0-24 years. *Acta Orthop.* 2006;77(6):853-65.
20. Reitman RD, Emerson R, Higgins L, Head W. Thirteen year results of total hip arthroplasty using a tapered titanium femoral component inserted without cement in patients with type C bone. *J Arthroplasty.* 2003;18(7 Suppl 1):116-21.