

Treatment of nonunion in the third distal of the radius

MARCO AURÉLIO SERTÓRIO GRECCO¹, LUIS CARLOS ANGELINI², MARCELO TAVARES DE OLIVEIRA³, NELSON TROMBINI⁴, FRANCISCO CARLOS MARTINS⁵, SÔNIA MARIA DE ALMEIDA PACHECO BARBOSA⁶

SUMMARY

The authors presented a prospective study of four patients presenting pseudoarthrosis at the distal third of the radius. Two patients were females and two were males, aged between 29 and 51 years with a mean age of 42.5 year old. The diagnosis of pseudoarthrosis was provided within an average of 5.3 months after trauma. One patient presented as personal morbid history, epilepsy and osteoporosis, two patients were smokers and obe-

se, and the fourth had an open fracture. The treatment consisted of internal osteosynthesis and autogenous bone graft. All patients were submitted to pre- and post operative clinical evaluation for palmar holding force and wrist range of motion. 100% of the radius distal-third fractures in pseudoarthrosis have been united, with all patients returning to their respective professional activities.

Keywords: Pseudoarthrosis; Fractures; Non-United; Radius fractures.

INTRODUCTION

Fractures affecting the distal third of radius are the most frequent ones in the upper limb and are characterized by their expressiveness, first described by Pouteau (1783). Today, they are considered as complex lesions which, depending on proposed treatment, will present a variable result. However, such lesions are scarce in literature⁽¹⁾. As an example, we can mention the pseudoarthrosis of the distal end of the radius, which is uncommon. It is worthy to highlight the quotation: "Pseudoarthrosis is so rare that, on the sixth week of immobilization in a distal radius fracture, the plastered apparatus can be removed with or without radiographic evidences of union"⁽²⁾.

Some factors associated to pseudoarthrosis have been reported, such as: obesity, diabetes, alcoholism, vascular peripheral disease, psychic disorders, scleroderma, improper immobilization, excessive distraction of fracture at the external fixation, open fracture, interposed soft tissues on the fracture^(3,4).

Uncountable treatments for this complication are mentioned: internal osteosynthesis with autogenous bone graft of the iliac^(3,4,5), radiocarpal arthrodesis^(3,4,6), extra-articular bone graft⁽⁷⁾, transient ankylosis⁽⁸⁾ and autogenous bone graft of the iliac with plastered immobilization⁽⁹⁾.

The purpose of this study was to evaluate the treatment of pseudoarthrosis of radius distal fractures.

CASUISTICS AND METHODS

Within the period comprised between March 2000 and December 2001, four wrists of four patients presenting with fractures on radius distal third with pseudoarthrosis have been treated. From these four patients, two were females and two were males. Mean age of patients was 42.5 years old, ranging from 21 to 59 years. The left side was involved in two patients and the right side in one of them.

We collected data regarding occupations, personal morbid history, etiologic factors of fractures, early treatments of the fracture, time elapsed (in months) from fracture to pseudoarthrosis diagnosis, and the time elapsed (in weeks) to complete bone union.

Fractures have been classified according to the "Association for the Study of Internal Fixation" (AO/ ASIF) method; and whether there was a fracture exposure or not, classifying them as closed or open fracture.

The pseudoarthrosis diagnosis was provided upon radiographic examination and clinical tests.

The radiographic study was performed with images on frontal and lateral planes. On frontal plane, the upper limb is positioned with shoulder abduction and elbow flexion in 90 degrees, forearm in a neutral position with hand resting on the cassette. We used the most accepted nomenclature in literature, where

Study conducted at the Hand Surgery Clinic of the Hospital do Servidor Público Municipal of São Paulo, São Paulo/ SP, Brazil.

Correspondences to: Discipline of Orthopaedics and Traumatology, Surgery Department - HE/FMTM. Av. Getúlio Guaritá s/nº - Bairro Abadia CEP 38025-440 - Uberaba - MG. E-mail: marcoasgrecco@metalnet.com.br

- 1- Doctor Orthopaedic, ex-resident of the Hand Surgery Clinic
- 2- Doctor Orthopaedic at HSPM and Doctor in Charge of the Hand Surgery Clinic
- 3- Doctor Orthopaedic
- 4- Doctor Orthopaedic
- 5- Doctor Orthopaedic, ex-resident of the Hand Surgery Clinic
- 6- Occupational Therapist

Received in: 03/31/04 ; approved in: 08/30/04

posteroanterior position creates a posteroanterior image, resulting from the ray path at the capitatum head level, perpendicular to the film, in a dorsovolar direction. The image so captured provides an opportunity to evaluate all distal radioulnar joint, the adjacent radius and ulna, all the carpus, metacarpal base and radius distal third.

Lateral radiographic image was captured with the elbow positioned in a 90° flexion and with the ulnar edge of the forearm and wrist over the cassette. The correct image reveals the palmar face of the pisiformis, in a mean point between scaphoid volar pole and the volar face of the capitatum head (Figures 1, 2, and 3).

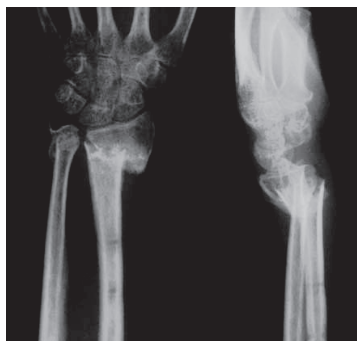

Figure 1 – Radiographs on PA and lateral planes of a pseudoarthrosis of distal radius fracture in patient number 1.

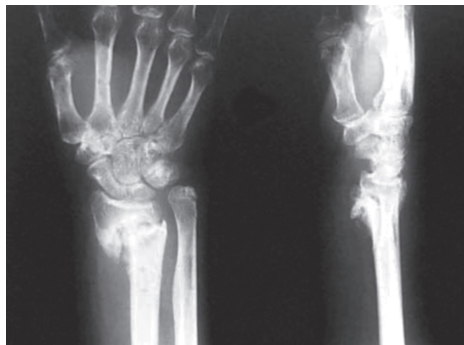


Figure 2 - Radiographs on PA and lateral planes of a pseudoarthrosis of distal radius fracture in patient number 2.

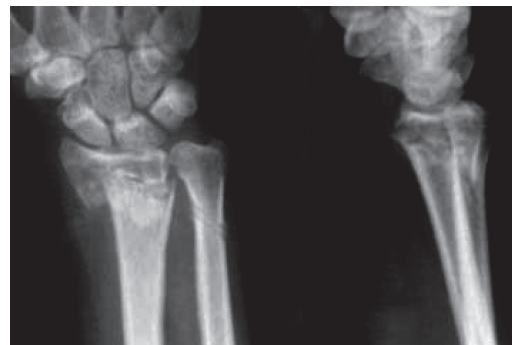

Figure 3 - Radiographs on PA and lateral planes of a pseudoarthrosis of distal radius fracture in patient number 4.

We clinically observed: pain, palmar holding force and wrist range of motion.

Pain was recorded according to patient's complaint. The presence of pain was recorded as positive (+) and its absence as negative (-).

Palmar holding force was measured by using a hydraulic dynamometer Jamar®. For this test, the elbow is kept in a 90° flexion, forearm in neutral rotation and the Jamar® switch at position 2, being performed three measurements and their average recorded as the force value (in kg/f). Wrist active range of motion was measured by using the goniometer in flexion, extension, abduction, adduction, pronation and supination.

SURGICAL TECHNIQUE

After general anesthesia, the operating field was prepared with the upper limb resting on a complementary table, with shoulder abducted by 90 degrees and elbow flexed by 90 degrees. The pneumatic garrote was routinely used, placed on the medium third of the arm; then, asepsis and antisepsis of the forearm, wrist and hand with povidine (iodized polyvinyl pirolidone, solution) were performed. The same procedure was performed on the contralateral hip region for bone graft removal. After ten minutes with the upper limb rose, the pneumatic garrote was insufflated with controlled pressure within 100 to 150 mmHg above patient's systolic pressure.

Patient number 1 was submitted to open reduction through a 10-cm dorsal and longitudinal incision at the level of the 3rd compartment, close to radius dorsal tuberculum; the extensor retinaculum was opened from dorsal to proximal, and the thumb long extensor muscle was withdrawn for accessing radius metaphy-

sis. Deformity correction and the interposing of autogenous bone graft removed from the iliac were performed, followed by internal fixation with AO plate, type N. In patient number 2, an open reduction through two incisions was performed – one volar and radial, and the other ulnar. The ulnar incision extended longitudinally in 10 cm between ulnar flexor and extensor tendons of the carpus. Osteotomy and a 5-cm shortening of the ulna were performed, as well as internal fixation with a reconstruction plate DCP-AO. At volar and radial levels, a 10-cm longitudinal incision was performed at the radial border of the radial flexor tendon of the carpus; the square pronator muscle was opened from distal

to proximal, in order to address the radial metaphysis. After deformity was corrected, according to the schedule, the internal osteosynthesis with AO plate type T was performed with the insertion of an autogenous bone graft removed from the ulna, following its shortening. Regarding patients # 3 and 4, at volar and radial levels, a 10-cm longitudinal incision close to the radial edge of the radial flexor tendon of the carpus was made; the square pronator muscle was opened from distal to proximal in order to address radial metaphysis. After the deformity was corrected, the internal osteosynthesis was performed using an AO plate type T, and the open reduction was performed (through a volar incision), internal fixation (with plate and screw) and autogenous graft removed from the right iliac bone. By blocking pronation-supination movements in patient # 3, simultaneously, this radioulnar joint complication was treated by using the Sauvé-Kapandji technique^(1,10).

After surgery, the pneumatic garrote was deflated and local hemostasis was performed. Then, structures were sutured in planes. Bloody areas were involved in sterile patches, cotton and crepe bandages and then, a volar support plastered splint, brachiopalmar, with free fingers' metacarpophalangeals and interphalangeals and thumb. The upper limb was kept in a fabric support extending from the shoulder to the hand.

POSTOPERATIVE CARE

On the seventh day after surgery, dressing was placed on the wrist and on the bone graft donating region.

Between the tenth and the fourteenth days postoperatively, new dressings were placed. At that moment, surgical stitches on the iliac region and on the distal third of the forearm were

removed. The upper limb was immobilized with forebrachiopalmar plaster. Radiographic controls were taken on the first week and on a monthly basis, until fracture union.

Those patients were followed up, in a weekly basis, in an outpatient level, by the occupational therapy team, coordinated by the surgeon. They were submitted to rehabilitation in three scheduled visits, one at a week, according to the rehabilitation protocol in service, aiming the early motion of metacarpophalangeal joints.

Patient number 2 progressed with delay in union, verified three months after early surgical treatment of the pseudoarthrosis and was submitted to another surgery, which removed the sclerotic bone and granulation tissue and, then, another autogenous bone graft removed from the homolateral iliac.

Upon the union of fractures in pseudoarthrosis, the occupational therapy group, coordinated by the surgeon, rehabilitated patients regarding ranges of motion of radioulnar, distal, radiocarpal joints, and palmar holding force. Patients were submitted

to clinical assessment, being assessed the presence of pain and verified the palmar holding force and active range of motion of wrist joints. Values for this verification were compared to those obtained preoperatively, for percentage quantification of the improvements.

RESULTS

Data regarding occupations, personal morbid history, etiologic factors of fractures, fracture exposure, classification of fractures according to the A.O., early fracture treatments, time (in months) elapsed from the fracture to pseudoarthrosis diagnosis; bone union period (in weeks), preoperative strength, pain, flexion, extension, supination, pronation, abduction and adduction are presented on Tables 1, 2, 3 and 4.

Patients improved the palmar holding force (42%); palmar flexion (30.2%), extension (19.3%); supination (49.6%); pronation (37%); abduction (34.6%) and palmar adduction (61%). All patients progressed to absence of pain (Table 4).

P	g	Age	Occupation	Side	History	Causes
1	F	48	Housewife	R	Epilepsy and Osteoporosis	Fall
2	M	59	Clerk	L	Smoking and Obesity	Fall
3	M	21	Bricklayer	R	No report	Car accident
4	F	42.5	Maid	L	Smoking	Fall

Table 1 - Information about patients with distal radius pseudoarthrosis – listed by numbers; gender (g); Age in years; occupation; involved side; history and fracture causes

P	A	O	Fracture Exposure	Early Treatment	Diag. Pseud. (months)	End Treatment	Union (Weeks)
1	B	2	Closed	Closed reduction External fixation without bone graft	5	Open reduction and internal fixation with plate and screw, and bone graft	12
2	C	2	Closed	Closed reduction External fixation without bone graft	6	Open reduction and internal fixation with plate and screw, and bone graft	24
3	C	3	Open	Open reduction External fixation without bone graft	5	Open reduction and internal fixation with plate and screw, and bone graft	10
4	B	2	Closed	Closed reduction External fixation through De Palma method	5	Open reduction and internal fixation with plate and screw, and bone graft	14

Table 2 - Data of four patients with pseudoarthrosis of the distal radius fracture, listed by numbers (p), AO/ ASIF Classification of fracture, fracture exposure, early treatment of fracture, pseudoarthrosis diagnostic after fracture, in months (diag. pseud); end treatment of pseudoarthrosis and bone union, in weeks.

P	Force (kg/f)	Pain	Flex	Ext	Sup	Pro	Abd	Ad
1	10	+	50°	60°	55°	62°	13°	18°
2	12	+	48°	50°	80°	90°	15°	30°
3	13	+	45°	41°	15°	21°	8°	7°
4	11.5	+	47°	50°	70°	75°	16°	17°
Mean	11.6		47.6°	50.3°	55°	62°	13°	18°

Table 3 - Data of four patients with pseudoarthrosis of the distal radius fracture, listed by number (p); preoperative palmar holding force, preoperative flexion (flex); preoperative pain; preoperative extension (ext); preoperative supination (sup); preoperative pronation (pro); preoperative palmar abduction (abd), and preoperative palmar adduction (ad).

p	Force pre/post (kg/f)	Pain	Flex Pre/post	Ext pre/post	Sup pre/post	Pro pre/post	Abd pre/post	Ad pre/post
1	10/16	-	50°/67°	60°/75°	55°/82.4°	62°/80	13°/17°	18°/21°
2	12/30	-	48°/66°	50°/55°	80°/85°	90°/85°	15°/18°	30°/40°
3	13/30	-	45°/65	41°/50°	15°/80°	21°/85°	8°/17°	7°/30°
4	11.5/17	-	47°/50°	50°/60°	70°/82°	75°/90°	16°/18°	17°/25°
Averages	11.6/23.3		47.6°/62°	50.3°/60°	55°/82.3°	62°/85°	13°/17.5°	18°/29°
%	42		30.2	19.3	49.6	37	34.6	61

Table 4 - Data of four patients with pseudoarthrosis of distal radius fracture; listed by number (p); pre- and postoperative palmar holding force; postoperative pain; pre- and postoperative flexion (flex); pre- and postoperative extension (ext). pre- and postoperative supination (sup); pre- and postoperative pronation (pro); pre- and postoperative palmar abduction (abd); pre- and postoperative palmar adduction (ad); averages and percentage of improvement between pre- and postoperative averages.

Distal radius fractures are the most frequent ones on the upper limb; it is estimated that they account for 10 to 12% of all fractures of the skeleton, and can represent 74.5% of all fractures of the forearm, with an approximate incidence of 1:10.000 individuals⁽¹¹⁾.

Complications are frequent on radius distal fractures and include vicious union, reflexive-sympathetic dystrophy, distal radioulnar and radiocarpal arthrosis, hand and wrist joints' stiffness, nervous and tendinous lesions⁽¹²⁾ and the uncommon pseudoarthrosis^(4,13). A fracture of the distal third of the radius unusually progresses to pseudoarthrosis, that is why the plastered appa-

ratus can be removed on the sixth week of immobilization, with or without radiographic evidences of union⁽²⁾.

Pseudoarthrosis is defined as the lack of union in a fracture, with clinical and radiographic evidences that the fracture healing process is completed, but in which union will potentially be unlikely. The final status of a non-united fracture is the occurrence of pseudoarthrosis⁽¹⁴⁾.

Clinical symptoms usually are not dramatic; they usually cause slight to negligible pain, weakness feeling, instability of the end, deformity and abnormal motion at the fracture core. Radiographically, the following are noticed: fracture line, which is usu-

ally totally visible; little or no bone callus formation, both internal and external on oligotrophic or atrophic pseudoarthrosis; external exuberant bone callus formation on hypertrophic pseudoarthrosis; medullar duct can be obliterated or opened; the edges of bone fragments usually present with re-absorption and sclerosis; there are diffuse osteoporosis and osteopenia, indicating limb disuse; deformity with angulation or rotation and image showing graft material broken or loosen when used for osteosynthesis⁽¹⁴⁾.

Only four pseudoarthrosis of distal radius fractures have been studied and treated, which confirms the scarcity of this kind of lesion. Most of the reports in literature mention only one or two presenting with this complication^(7,8,9). Watson-Jones⁽¹³⁾, in 1942, found only one case within 3,199 distal radius fractures. Barcon and Kurtzke, in 1953, reported an incidence of 0.2% in approximately 2,000 cases of such fracture⁽¹⁵⁾. Recently, articles were described with five and twelve cases^(3,4).

Regarding age group, this study presented individuals with ages ranging from 21 to 59 years old (average 42.5), which is consistent to data found in literature.

Regarding trauma mechanism, the most common causes, similar to those described by other authors, are falls^(4,6).

As for the personal morbid history, the following cases were reported: one presented with epilepsy and osteoporosis; two, smoking and obesity; and the last one, an open fracture. There is a similar description in literature^(3,4).

In the cases discussed, the early treatment of fracture consisted on a closed reduction with external fixation, with no bone graft in three patients, being two of them treated with the external fixation device and the other, by a modified De Palma method; the fourth, an open fracture treated with open reduction and external fixation, also without bone graft. Open fracture, extensive inappropriate immobilization, soft tissues lesion, excessive distraction of the external fixation device, interposed soft tissues and excessive comminution are factors associated with pseudoarthrosis^(3,4).

The time elapsed from the fracture until the pseudoarthrosis diagnosis was, in average, 5.3 months, which is consistent to other author's reports^(3,5,9).

Various pseudoarthrosis treatments are mentioned in literature. There are reports on extra-articular bone graft⁽⁷⁾, transient ankylosis of wrists with threads fixating the second and third metacarpus to radius distal and proximal fragments⁽⁸⁾, and autogenous bone graft of the iliac with plastered immobilization in a child⁽⁹⁾. The treatment most commonly described consists on an open reduction and internal fixation with plate and screw, dorsal or volar, with autogenous bone graft from the iliac^(3,4,5). The procedures performed by us are consistent to this treatment, aiming to recover palmar holding force, distal radioulnar and radiocarpal joint's range of motion, and the return to daily and professional activities. On the other hand, there are authors describing cases of radiocarpal arthrodesis in their studies^(3,4,6). Segalman et al.⁽⁹⁾, in 1998, used as an arthrodesis criterion a classification based on the distal subchondral bone to pseudoarthrosis. They classified as type A the presence of less than 5 mm of subchondral bone, considering it as insufficient for open reduction and internal fixation with plate and screws; and as type B when there are more than 12 mm, appropriate for internal fixation and bone graft. From the nine type-A patients who were treated by them, six were submitted to wrist arthrodesis. We disagree with such procedure for considering that the pseudoarthrosis should be treated primarily, prior to the arthrodesis.

About the time for the union of radius distal third fractures in pseudoarthrosis, data in literature vary. There are case reports in which union occurred⁽³⁾ between three and 12 months^(3,5,7,8,9). Therefore, our results – ranging from 12 to 24 weeks – are consistent to those mentioned in literature (Figures 4, 5 and 6).

Smith et al.⁽⁴⁾ mentioned an unsuccessful case of early pseudoarthrosis treatment, similar to that referred to in this study (patient number 2). Those authors treated this intercurrent with electric stimulus and remade the internal osteosynthesis with a new bone graft. In our approach, we chose to perform the remo-

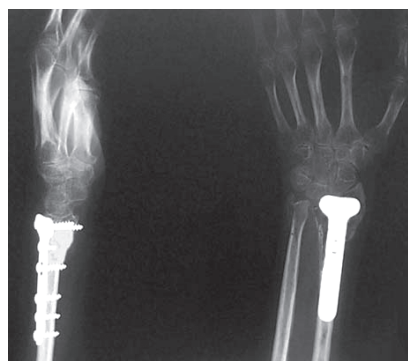


Figure 4 – Radiographs on PA and lateral planes, showing bone union after 12 weeks of surgical treatment of pseudoarthrosis of distal radius fracture in patient number 1.

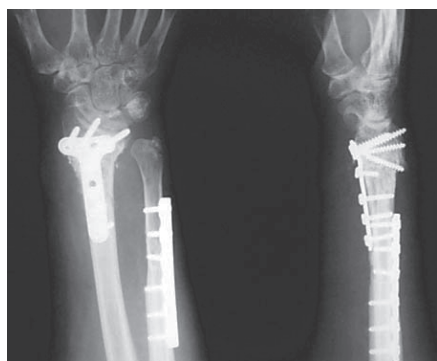


Figure 5 - Radiographs on PA and lateral planes, showing bone union after 24 weeks of surgical treatment of pseudoarthrosis of distal radius fracture in patient number 2.

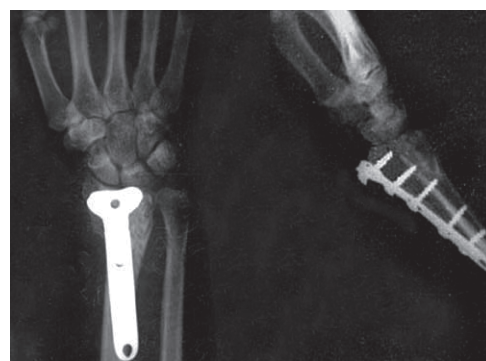


Figure 6 - Radiographs on PA and lateral planes, showing bone union after 14 weeks of surgical treatment of pseudoarthrosis of distal radius fracture in patient number 4.

val of sclerotic bone and granulation tissue of the pseudoarthrosis, a new autogenous bone graft and did not perform the internal osteosynthesis, because, during the surgical procedure, we noticed that it remained stiff.

Regarding clinical treatment, we verified, before and after surgical procedure, the subjective presence of pain reported by patient, palmar holding force and the range of motion of distal radiocarpal and radioulnar joints (flexion, extension, abduction, adduction, pronation and supination). Unfortunately, there are no references in literature to this kind of clinical evaluation, which makes any comparison to our results impossible. We emphasize that at baseline evaluation, two patients presented with a range of motion close to normal.

All patients in this study returned to daily and professional activities, a concrete fact that we noticed and considered as

worthy to mention. Literature does not provide any information about this subject.

Finally, we ratify the scarcity of such complication, with few cases mentioned in literature, being its etiology still not clear. The diagnosis of pseudoarthrosis, once confirmed by appropriate clinical and radiographic tests, and with a well-prepared pre-operative planning, as showed here, makes an appropriate surgical technique feasible to treat pseudoarthrosis, providing patients with the return to his/her daily and professional activities.

CONCLUSION

The treatment of pseudoarthrosis in all patients was successful. We noticed an improvement in esthetics, pain, palmar holding force and wrist range of motion. The patients returned to their professional activities.

REFERENCES

- 1) Angelini LC, Leal Junior JG. Tratamento das seqüelas das fraturas da extremidade distal do rádio. In: Pardini Junior AG. Traumatismos da mão. 3ª ed. Rio de Janeiro: Medsi; 2000. p.457-80.
- 2) Wilton JN. Fractures and joint injuries In: Watson J. Edinburgh: Churchill Livingstone; 1976.
- 3) Segalman KA, Clark GL. Un-united fractures of the distal radius: a report of 12 cases. J Hand Surg 1998; 23:914-919.
- 4) Smith VA, Wright TW. Nonunion of the distal radius. J Hand Surg Br 1999; 24:601-603.
- 5) Harper WM, Jones JM. Non-union of Colles' fracture: report of two cases. J Hand Surg Br 1990; 15:121-123.
- 6) McKee MD, Waddell JP, Yoo D, Richards RR. Nonunion of distal radial fractures associated with distal ulnar shaft fractures: a report of four cases. J Orthop Trauma 1997; 11:49-53.
- 7) Hamada G. Extra-articular graft for non-union in Colles' fracture. J Bone Joint Surg 1944; 26:833-835.
- 8) Saleh M, Ribbans WJ, Maffert RH. Bundle nailing nonunion of the distal radius: case report. Handchir Mikrochir Plast Chir 1992; 24:273-275.
- 9) Kwa S, Tonkin MA. Nonunion of a distal radial fracture in a healthy child. J Hand Surg Br 1997; 22:175-177.
- 10) Angelini LC, Leite VM, Faloppa F, Laredo JF. Surgical treatment of Madelung disease by the Sauvè-Kapandji technique. Ann Chir Main Memb Super 1996; 15:257-267.
- 11) Alffram PA, Bauer GC. Epidemiology of fractures of the forearm. J Bone Joint Surg Am 1962; 44:105-114.
- 12) Stewart DH, Innes AR, Burke FD. The hand complications of Colles' fractures. J Hand Surg Br 1985; 10:103-106.
- 13) Watson-Jones R. Fractures and other bone and joint injuries. 2ª ed. Edinburgh:Livingstone; 1942.
- 14) Croci AT. Retarde de consolidação e pseudo-artrose. Acta Ortop Bras 1997; 5:26-32.
- 15) Bacorn RW, Kurtzke JF. A study of two thousand cases from the New York State Workmen's Compensation Board. J Bone Joint Surg Am 1953; 35:643-658.