

SPOTORNO® TOTAL HIP ARTHROPLASTY

CARLOS ALBERTO DE SOUZA MACEDO¹, RODRIGO BENEDET SCHEIDT², HUMBERTO MOREIRA PALMA³,
RICARDO ROSITO⁴, WALMOR WEISSHEIMER JUNIOR⁵, CARLOS ROBERTO GALIA⁶

SUMMARY

The objective of the study was to assess clinical-X-ray endpoint on a cohort of 48 patients (54 hips) submitted to Spotorno® primary non-cemented total hip arthroplasty in the last 20 years (1985 – 2005), with mean follow-up time of 17.5 years (range: 8-20 years). In the clinical and functional evaluation, 92.7% good outcomes were achieved. Osteopenia was found in 24 acetabula (44.4%) and 30 femurs (55.6%); A mean of 2 millimeters (0-5 mm) of polyethylene wear-off

was present in 43 acetabula (79.6%). The statistical analysis of the results suggested that the presence of osteopenia is not associated to the clinical endpoint ($p=0.75$); polyethylene wear-off as well as the presence of osteopenia was more significant if patients below the age of 55 years ($p<0.05$). We concluded that the use of a Spotorno® prosthesis on this cohort showed good outcomes, similar to those previously reported in literature.

Keywords: Hip arthroplasty; Surgery; Hip.

Citation: Macedo CAS, Scheidt RB, Palma HM, Rosito R, Weissheimer Junior W, Galia CR. Spotorno® total hip arthroplasty. *Acta Ortop Bras.* [online journal]. 2008; 16(4): 217-222. Available at URL: <http://www.scielo.br/aob>.

INTRODUCTION

The worldwide popularization of the Total Hip arthroplasty (THA) was disseminated by Vharnley in the 1960's⁽¹⁾. At that time, the metal-polyethylene joint fixed with cement (polymethylmethacrylate - PMMA) was the golden standard. With the dissemination of cemented THA, we also saw an increase of the number of complications, particularly the aseptic loosening and osteolyses. Initially, the problem was believed to be on the cement, that's why at that time the term "cement disease" started being investigated⁽²⁾. The results of those studies showed that the reason for failures was not only on the cement, but also on a number of factors. At that time, THA's performance started being questioned on young patients⁽³⁾, due to the presence of osteolyses and the challenges in THA review surgeries. These events encouraged the search for biological solutions as an alternative in THA⁽⁴⁾.

Thus, in the late 1970's, THA indication with biological fixation (cement-free) started to grow. That period was marked by the emergence of a number of new implants with very different conceptions regarding material, format, coating type, and others⁽⁵⁾. The analysis of the preliminary outcomes with those new implants, when compared to the outcomes achieved by appropriately cemented prostheses, suggested that not all new conceptions would have support with follow-up, and this fact was well demonstrated by the range of models manufactured by renowned companies at the time^(6,7).

All of these drove us to share our 20-year experience with THA using the Spotorno® prosthesis, which has been available in the market since 1984, with no conceptual changes. The Spotorno® Cementless System (CLS) introduced quantitative and objective criteria for the indication of cement-free arthroplasty, such as: gender, age, Singh index⁽⁸⁾ and morphocortical index⁽⁹⁾.

The objective of this study is to present clinical and X-ray outcomes with the use of Spotorno® prosthesis with 17.5 years of mean follow-up.

MATERIALS AND METHODS

The present study is a mixed cohort of 53 patients (59 hips) submitted to THA using the Spotorno® cementless prosthesis, between 1985 and 1997, being followed-up until 2005 (average: 17.5 years). During that period, four patients missed follow-up; thus, they were not included in the study. Four patients died for reasons not related to the THA, but were not excluded from the study for having clinical and X-ray evaluation recorded close to the date of their death, taking into account, in this case, the last evaluation. Furthermore, one patient presented infection at early postoperative period requiring prosthesis review, was therefore, excluded. One patient showing loosening of the acetabular component was reviewed; however, his data were computed for the period previously to review. All patients were operated by the Hip Surgery team in our Hospital. A letter was sent to the Hip Surgery Reference Centers in our region, asking if any review or treatment was provided for complications on patients included in our study, who we could eventually have lost track of. Concerning conception, the femoral component of the Spotorno® prosthesis is made of titanium (Ti6Al7Nb), with a cervicodiaphyseal angle of 145° and wedge format at three planes, press-fit to the bone at metaphyseal region. The proximal plane of the nail presents anterior and posterior striae for preventing rotational movement and to favor the interdigitation and union to the bone. The coronal proximal cut of the nail was designed with a size sufficient to fulfill the entire femoral canal and to homogeneously distribute force vectors. The distal portion was build with a smaller diameter compared to the canal for preventing against distal anchorage, avoiding forces concentration at the tip of the nail.

The acetabular Spotorno® component is a titanium (Ti6Al7Nb) half-spherical slightly-flattened cup with six expansible wings and teeth set in three rows externally to each wing, placed after the last milling with the aid of a chuck jaw. After the jaw is opened, a tapered threaded expander which will restore the initial acetabular size. As a result of that expansion, a stable primary fixation occurs.

Study conducted at Hospital de Clínicas de Porto Alegre- RS-Brazil.

Correspondences to: Banco de Tecidos do Hospital de Clínicas de Porto Alegre- HCPA: Rua Ramiro Barcellos, 2350 – Largo Eduardo Zaccaro Faraco – CEP 90035-903 – Porto Alegre/RSBrasil -E-mail: rosito.ricardo@gmail.com

1. Associate Professor, Department of Surgery, Federal University of Rio Grande do Sul (UFRGS) Medical School, and Orthopaedics and Traumatology Service, Hospital de Clínicas de Porto Alegre (HCPA). Ph.D. in Surgery by UFRGS
2. Resident Doctor, Orthopaedics and Traumatology Service, Hospital de Clínicas de Porto Alegre (HCPA)
3. Resident Doctor, Orthopaedics and Traumatology Service, Hospital de Clínicas de Porto Alegre (HCPA)
4. Assistant Doctor, Orthopaedics and Traumatology Service, HCPA. Master in Surgery by UFRGS
5. Orthopaedic and Traumatology Doctor.
6. Delegate Professor, Department of Surgery, Federal University of Rio Grande do Sul (UFRGS) Medical School, and Orthopaedics and Traumatology Service, HCPA.

Received in 07/10/07 approved in 09/04/08

A secondary fixation is possible thanks to osteointegration on the titanium surface. Inside the titanium cup, the threaded polyethylene implant is inserted (UHMW-RCH-1000 Chirulen®). A broad distribution of implant forces on the bone is achieved by the mechanism of expansion and the resulting pressfit.

The interchangeable head is made of chrome-cobalt-molybdenum (CoCrMO-Protasul®) with 28 mm available with standard, medium and long neck (Figure 1).



Figure 1 - Spotorno® total hip prosthesis

The numeric criteria established by Spotorno® (Table 1), where gender, age, Singh's index and the morpho-cortical index are taken into account (Figure 2).

All patients have been called by the responsible team to present at the Service outpatient facility, where they responded to a pre-established assessment protocol, being submitted to X-ray image tests of the pelvic cavity (anteroposterior) and of the thigh-femur on the affected side (lateral) and to clinical examination. The medical files for these patients were reviewed as well.

The clinical evaluation was provided prior to the X-ray study, and these were performed by different investigators targeting to reduce any examination bias. The criteria proposed by Merle d'Aubigné and Postel⁽¹⁰⁾ for clinical evaluation assessing pain, gait and mobility. Special attention was given to the existence or not of thigh pain. For statistical analysis purposes, patients achieving a score between good and very good according to Merle d'Aubigné e Postel⁽¹⁰⁾'s functional scale were regarded as good outcomes (Table 2). The others were regarded as poor outcomes.

The X-ray evaluation of hip osteopenia was based on the criteria described by Zicat et al.⁽¹¹⁾ for kind (expansive or linear) and at the DeLee e Charley⁽¹²⁾ zones for location. On the femur, we used

the criteria described by Turíbio⁽¹³⁾ for the analysis of osteopenic cases, which have five types (0-4). The type 0-no osteopenia, 1-osteopenia restricted to the major trochanter region, 2-osteopenia extending from major trochanter to the minor trochanter region, 3-osteopenia on major and minor trochanter regions extending to the shaft medium third, 4-osteopenia throughout the extension of the femoral implant. During the X-ray evaluation, polyethylene wearoff and the migration of the femoral component (*subsidence*) were also assessed, both measured with the aid of a clear rule with mm increments. For statistical analysis, the Spotorno® BMI score was divided into two groups (Group 1 - Spotorno® score < two points; and Group 2 - with score > two points). After that division, we correlated the groups with the presence or absence of femoral migration. In addition to the topics mentioned, data concerning current age, follow-up, operated side, root disease were also assessed, in addition to other described on Table 5.

For statistical analysis purposes, the patients were divided into two groups: by age and by the functional score proposed by Merle d'Aubigné e Postel. The cutting age was 55 years, five years above the suggested zero score by Spotorno®, since it was the mean age found. We considered as good results those patients showing a score between good and very good, and, as poor, those with medium, fair and poor results.

The statistical analysis was conducted using the statistical software SPSS for windows, release 14.0 (SPSS Inc, Chicago, IL).

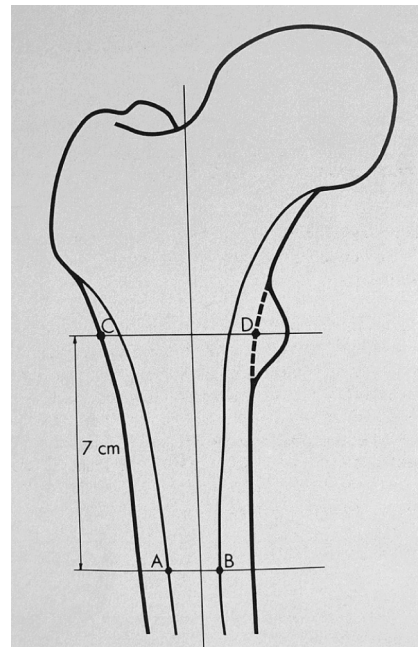


Figure 2 - Morphous-cortical index proposed by Spotorno (IMC): IMC: CD/AB

Gender		Age		Singh's Index		Morphous-cortical index	
	Score		Score		Score		Score
Male	0	< 50	0	6-0	0	>3	0
Female	1	51-60	1	5	1	3-2.7	1
		61-70	2	4-3	2	2.6-2.3	2
		>70	4	2-1	4	2.3	4
Scoring suggested for Spotorno cementless nail use							
0-4 Points				5 Points		> 6 Points	
Cementless				Discussible		Cemented	

Table 1 - Scoring for Spotorno cementless prosthesis indication

Normal or almost normal mobility (6.5)		
Pain (P)	Ability to ambulate (A)	
		Very good P + A = 11 or 12
6	6	Ambulate without crutches, pain or limping
6	5	Ambulate without crutches, pain, but with slight limping
5	6	Ambulate without crutches, but with mild pain at the beginning of the gait
		Good P + A = 10
5	5	Ambulate without crutches, with pain and slight limping
4	6	Ambulate without crutches, with pain, but without limping
6	4	Ambulate without crutches or pain; one crutch used to external activities
		Medium P + A = 9
5	4	Mild pain; one crutch is used to external activities
4	5	Pain after ambulating for a few minutes; no crutches, but with slight limping
6	3	No pain; one crutch used all the time
		Fair P + A = 8
5	3	Mild pain; one crutch used all the time
4	4	Pain after ambulating; one crutch is used to external activities
		Poor P + A = 7 or less
Reduced mobility (4,3,2,1,0)		
		If mobility is reduced to 4, the result will be downgraded by one degree
		If mobility is reduced to 3 or less, the result will be downgraded by 2 degrees

Table 2 – Functional grading of the hip according to Merle d'Aubigné and Postel

On the descriptive analysis, the following were used for quantitative variables: arithmetic average, standard deviation (SD), maximum, minimum and median values, and; for qualitative variables (categorical): percentages and wherever applicable.

In quantitative variables, the Student's t test was employed and, in asymmetry situations, the Mann-Whitney's U test and the Wilcoxon's test. On categorical variables, the Pearson's chi-squared χ^2 test was employed to compare clinical and X-ray characteristics between the groups with human and bovine grafts in order to test for the impact of these grafts on prognosis.

For checking for the association of the X-ray score with the clinical score, the Pearson's correlation coefficient was employed.

A p value below 0.05 was regarded as statistically significant.

The following endpoints were listed for statistical correlation check: presence of osteopenia with clinical outcome; clinical outcome and the indication criteria for Spotorno®; polyethylene wearoff and osteopenia; migration of the femoral nail with the Spotorno® criteria; age with clinical outcome and age with polyethylene wearoff. For such calculations, the Einfo software was employed as a database for cases operated on Table 5, on results.

RESULTS

The Spotorno® prosthesis was used on 53 patients (59 hips). Of these patients, four did not return for clinical evaluation and thus were excluded from the study. Other four patients evolved to death on late postoperative period of causes not related to the surgical procedure.

The study population was constituted of 48 patients (54 hips), six of them being submitted to bilateral arthroplasty. The sample was distributed as 28 (57.4%) male patients and 20 (42.6%) female patients, with mean age of 55 years preoperatively (22 to 76 years old). Concerning the operated side, in 35 patients (66%) the right side was operated, and (34%) on the left side. The mean follow-up and

the median value for patients were both 17.5 years (8 to 20 years).

There was one infection case (1.8%) requiring review. One case (1.8%) showed aseptic loosening of the acetabular component after 8 years of follow-up requiring review only on the acetabulum (Figure 3).

The most prevalent root disease related to arthroplasty indication was primary coxarthrosis, diagnosed in 38 patients (71.7%). The remaining showed avascular necrosis (six patients – 11.3%), rheumatoid arthritis (three patients – 5.7%), ankylosing spondylitis (two patients – 3.8%), femoral neck fracture (one patient – 1.9%), acetabular dysplasia (one patient – 1.9%), and acetabular sequel (two patients - 38%).

On the clinical results analysis, according to the functional scoring proposed by Merle d'Aubigné and Postel⁽¹⁰⁾, we found 50 hips (92.7%) with very good and good results, and four hips (7.5%) with medium, fair and poor results (Figure 4). Thigh pain was present in only two patients (3.7%).

Osteopenia was present on 24 acetabula (44.4%) all of these of the expansive type. Osteopenia cases were divided according to Table 3, being most frequently located on the zone two of DeLee and Charnley⁽¹²⁾.

Osteopenia was present on 30 femurs (55.6%). The condition was graded according to the criteria by Turíbio, as shown on Table 4: as type I, in 3.7 %; type II in 44.4% and type III in 7.4%.

The wearoff rate of the polyethylene material present in 43 acetabula (79.6%) was assessed with an average of 2 mm (0-5mm). If we consider the mean follow-up of 15 years, the average wearoff of the polyethylene material was 0.13 mm / year. The statistical analysis of the results suggested that the presence of osteopenia is not correlated to the clinical endpoint (p=0.75); the polyethylene material wearoff was more pronounced on patients below the age of 55 (p<0.05), RR of 1.34 (1.01 – 1.75), being statistically significant when calculated by the Fisher's exact test (p<0.05). The presence

1. Nr.	2. Sex	3. Side	4. Age	5. Doe	6. Singh	7. IMC	8. P.S.	9. F.up	10. Pain	11. Ma	12. Mo	13. Fc	14. Cox	15. Zicat DeLee	16. Desg Poli	17. Mig fem	18. Turibio
1	F	L	24/31	1	5	2.80	3	8	6	6	6	12	N	A	A	2mm	3
2	F	R	57/65	1	6	2.50	3	9	6	6	6	12	N	A	A	A	0
3	F	R	62/70	1	6	3.15	3	9	6	6	6	12	N	E-Z1,2	2mm	1mm	3
4	M	R	60/68	1	6	2.60	3	9	6	6	6	12	N	A	2mm	A	0
5	F	R	80/65	3	6	2.20	7	9	4	4	5	8	N	E-Z1,2,3	3mm	1mm	2
6	M	R	41/49	1	6	3.22	0	9	5	5	5	10	N	A	1mm	2mm	3
7	M	R	45/55	1	6	3.80	1	11	6	6	6	12	N	E-Z1,2	1mm	A	0
8	F	R	61/73	1	6	3.00	4	13	5	6	6	11	N	E-Z1,2,3	3mm	A	2
9	M	R	74/86	8	6	3.33	4	13	6	6	6	12	N	E-Z2,3	3mm	A	2
10	M	R	51/64	1	6	2.80	2	14	6	6	6	12	N	A	3mm	A	0
11	M	R	60/73	1	6	2.50	3	14	6	6	6	12	N	A	3mm	A	2
12	M	L	59/73	1	6	3.00	1	15	5	6	6	11	N	A	5mm	2mm	0
13	F	R	65/79	5	6	2.22	7	15	5	6	5	11	N	E-Z1,2	2mm	A	0
14	F	R	60/74	1	4	2.20	8	15	4	6	5	10	N	A	2mm	1mm	1
15	F	R	46/60	1	6	2.20	5	15	4	6	6	10	N	A	A	A	0
16	M	R	66/80	1	6	2.47	5	15	6	6	6	12	N	E-Z2	2mm	A	0
17	F	R	27/42	8	6	2.68	3	16	6	6	6	12	N	A	2mm	A	0
18	F	L	35/50	4	6	2.00	3	16	5	5	5	10	N	E-Z2	2mm	A	0
19	M	R	51/66	1	6	2.25	2	16	6	6	6	12	N	A	2mm	A	0
20	M	R	64/79	3	6	2.33	3	16	6	6	6	12	N	A	A	A	0
21	M	R	61/76	1	6	2.56	3	16	6	6	6	12	N	A	A	A	0
22	F	R	61/76	1	6	2.18	6	16	6	6	5	12	N	A	A	A	0
23	F	L	61/76	1	6	1.70	7	16	6	6	5	12	N	E-Z3	A	A	0
24	M	R	51/66	4	6	2.43	2	16	6	4	5	10	N	E-Z2	2mm	A	2
25	M	L	57/72	1	6	2.25	3	16	6	6	6	12	N	A	A	A	0
26	F	R	65/80	1	6	2.64	4	16	6	5	6	11	N	E-Z2	3mm	A	0
27	M	R	41/56	1	6	4.00	0	16	4	5	5	9	N	E-Z3	3mm	2mm	2
28	M	R	54/69	2	6	3.00	2	16	6	6	6	12	N	A	1mm	A	2
29	M	L	54/69	2	6	3.13	1	16	6	6	6	12	N	A	2mm	A	2
30	F	R	61/76	1	6	2.12	7	16	6	6	6	12	N	A	3mm	1mm	2
31	M	L	48/63	2	6	3.00	1	16	6	6	6	12	N	E-Z3	1mm	1mm	2
32	M	R	45/60	1	6	3.10	0	16	6	6	6	12	N	E-Z1,2	3mm	1mm	2
33	M	L	36/51	2	6	2.8	1	16	5	6	6	11	N	A	2mm	2mm	0
34	M	R	56/71	2	6	2.50	3	16	4	5	5	9	N	E-Z1	3mm	2mm	2
35	M	L	62/77	1	6	3.22	2	16	6	6	6	12	N	E-Z1,2	4mm	2mm	2
36	F	L	43/58	1	6	3.2	1	16	4	5	5	9	S	E-Z1,2	3mm	A	2
37	M	L	55/71	1	6	2.81	2	17	6	6	6	12	N	E-Z2	3mm	2mm	2
38	F	L	61/72	1	5	2.40	5	17	5	6	5	11	N	A	A	A	2
39	F	R	57/73	7	6	2.80	3	17	6	6	6	12	N	A	2mm	2mm	2
40	M	R	47/63	2	6	2.40	2	17	5	6	6	11	S	A	3mm	3mm	2
41	M	R	58/74	1	6	3.22	1	17	6	5	6	11	N	E-Z2,3	2mm	A	1
42	M	R	42/58	1	6	2.27	2	17	5	6	5	11	N	E-Z1,2,3	3mm	A	0
43	F	L	34/50	1	5	2.15	5	17	5	5	6	10	N	E-Z2	2mm	A	0
44	M	R	53/69	1	6	2.61	2	17	6	6	6	12	N	A	3mm	A	0
45	F	L	74/90	1	4	2.38	7	17	6	6	6	12	N	A	2mm	A	0
46	M	R	76/92	1	5	2.73	5	17	6	6	6	12	N	A	A	1mm	3
47	M	L	76/92	1	5	3.07	7	17	6	6	6	12	N	A	A	A	2
48	F	R	55/71	1	6	2.66	2	17	6	5	6	11	N	E-Z2,3	2mm	A	0
49	M	R	50/67	1	6	2.40	2	18	5	6	6	11	N	A	3mm	A	0
50	M	R	47/65	1	6	2.70	1	19	6	6	6	12	N	A	2mm	A	2
51	F	R	61/79	1	5	3.06	4	19	4	6	5	10	N	A	2mm	1mm	2
52	F	L	24/42	3	6	2.12	5	19	5	5	6	10	N	A	3mm	A	2
53	M	L	61/79	1	6	3.10	2	19	6	6	6	12	N	A	2mm	A	2
54	F	R	23/42	3	6	2.20	5	20	5	5	5	10	N	E-Z1,2,3	3mm	1mm	2

Table 5 – Operated cases sorted by follow-up time order

1 – Nr. (cases); 2 – Gender; 9 – Follow-up (years); 10 – Pain grading. Evaluation by Merle d'Aubigné and Postel; 11 – Gait grading. Evaluation by Merle d'Aubigné and Postel; 12 – Mobility grading. Evaluation by Merle d'Aubigné and Postel; 13 – Functional grading by Merle d'Aubigné and Postel; 14 – Presence of thigh pain; 15 – A (absent); Osteopenia: E (expansive type) Zicat et al's - Z(zones) 1, 2 & 3 of DeLee and Charnley; 17 – Polyethylene material wearoff in mm; 17 – Migration of the femoral component in mm; 18 – Femoral osteopenia according to Turibio (0-4); 43- Surgery side; 54- Preoperative and postoperative age.; 65- Root disease; 76- Singh's osteoporosis X-ray grading (1-6); 87-Morphous-cortical index ;98- Grading for Sportorno's cementless prosthesis indication.

of wearoff was present and correlated to the presence of osteopenia with RR of 1.37 (1.09-2.65).

According to Spotorno® criteria for the indication of cementless prosthesis, 39 patients (72.2%) showed a score lower or equal to four, eight patients (14.8 %) a score five, and seven patients (13%) a score six or above.

The presence of femoral nail migration occurred in 19 arthroplasties (35.2%), with 1.5 mm as the mean rate. The presence of migration was not correlated to a grade inferior to 2 IMC points recommended by Spotorno® with RR of 1.22 (0.78-2.34).

No statistically significant evidence was seen between age and clinical functional outcome (RR: 0.75 ranging from 0.32 to 1.75, with the Fisher's exact test ($p > 0.05$)).

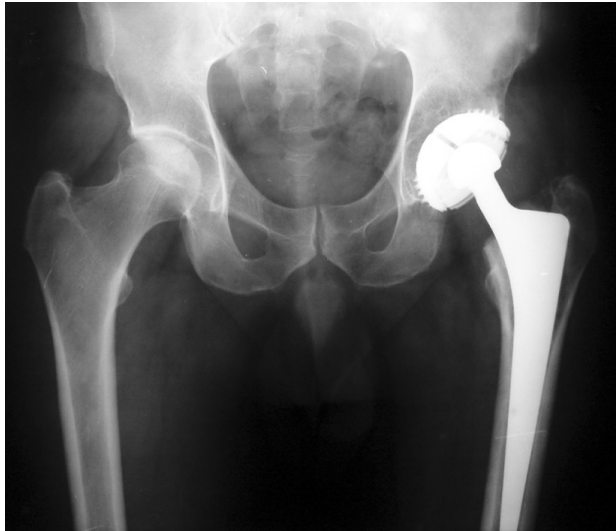


Figure 3 – Postoperative control X-ray image of case 51 (table 5) with 18 years of follow-up

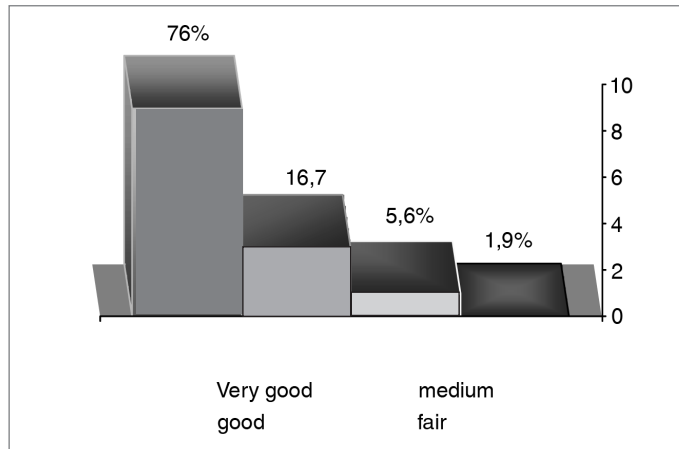


Figure 4 – Results of the functional evaluation according to Merle, d'Aubigné and Postel criteria

Zicat	Delee and Charnley
Incidence and Type	Zones
Present in 24 patients; expansive type (44.4 %)	I - 12 Patients (50 %)
	II - 20 Patients (83.3 %)
	III - 11 Patients (45.8 %)
Absent in 30 patients (55.6 %)	

Table 3- Distribution of acetabular osteopenia according to Zicat's criteria and to Delee and Charnley's zones.

Turibio grading	Nr. of patients
Grade 0: Absence of osteopenia	24 patients (44.4 %)
Grade 1: osteopenia restricted to the major trochanter region	2 Patients (3.7 %)
Grade 2: osteopenia extending from major trochanter to the minor trochanter region	24 Patients (44.4 %)
Grade 3: osteopenia on major and minor trochanter regions extending to the shaft medium third	4 Patients (7 %)
Grade 4: osteopenia throughout the extension of the femoral implant	0 Patient (0 %)

Table 4 – Distribution of femoral osteopenia cases according to Turibio's criteria

DISCUSSION

Our sample was consistent to the literature articles reviewed concerning gender, age, Singh's index and IMC^(14,15).

The clinical evaluation, according to the criteria described by Merle d'Aubigné and Postel, with 92.7% of good results shows similarities compared to other studies addressing the same prosthesis^(14,15). The special attention given to the existence or absence of thigh pain was aimed to compare our results with other cementless prosthesis conceptions, which, in some other studies^(8,16) showed a much higher incidence than the 3.7% rate found in our series. For being made of titanium alloy, the Spotorno® nail is sharp at its distal portion, and with no shaft anchorage makes us think like other authors who attribute thigh pain to distal fixation, to the elastic module of the material (CoCrMo) and to the stiffness created on the follow-up^(9,15,17).

The presence of osteopenia on acetabular (44.4%)^(27,32) and femoral (55.6%)^(8,18) regions, as well as on the zones and types ascertained, have been previously described by other authors who also found no correlation with the clinical outcome⁽¹⁹⁾. Most of these results, although previously described, were reported for shorter follow-up periods and should have had a longer follow-up time. The mean follow-up time of 15 years has contributed to our attempt to better understand the significance and evolution of such osteopenia or osteolysis as some articles suggest⁽²⁰⁾. We considered the grading used for osteopenia in the study as appropriate and feasible. However, we think that for better checking bone mass loss, a method that, in addition to categorize zones and kinds of osteopenia, could also differentiate its severity would be required. Thus, we could subdivide our groups and try to stratify our sample concerning magnitude (degree), for example: expansive-type osteopenia, on zone I and with severity degree (mild, moderate or severe). Another factor deserving attention is the fact that some articles show results for isolated components of the Spotorno® prosthesis in hybrid arthroplasties, thus allowing the potential of investigation biases concerning osteopenia, osteolysis and other endpoints. The correlation between polyethylene material wearoff and a higher incidence of osteopenia^(19,21), as well as a sharper polyethylene material wearoff on patients below the age of 55, has also been shown in previous studies, which suggest that younger patients tend to demand more from an implant^(17,21). The mean wearoff rate of 2 mm as measured in our mean follow-up (15 years) (0.13 mm / year), may offset the mean wearoff rate found in literature for cemented prostheses⁽²²⁾, being inferior to those described on articles assessing the wearoff rate on non-cemented acetabula (non-expansive) in shorter follow-up times⁽²³⁾. Like other authors, we believe that this is due to a number of aspects characteristic of the Spotorno® expansive acetabulum, such as: a better distribution of loads provided by the elasticity⁽⁹⁾

of the expanded wings; an increased minimum thickness of the polyethylene material (the narrower one is 14 mm) above the required as a minimum specification for other cementless prostheses conceptions (5-9mm) and a decreased thickness of the metalback. Femoral nail migration and accommodation in 19 patients (35.2%) (average: 1.5mm) are consistent to the biomechanical theory long advocated by Spotorno® for cementless wedge-like nails and, currently, very well recognized by advocates of the polished cemented collar-free wedge-like nails(9), making us believe that until secondary fixation is established by osteointegration the adjustment of the squared wedge-like nail may and should occur in bone sheath. No statistical difference was found in the comparison of clinical and X-ray outcomes to the criteria for Spotorno® surgery indication. This evaluation was possible due to the fact that, in our surgeries, we were not so strict to Spotorno® criteria for indication of cementless arthroplasty, with seven patients (13%) being operated with a score of six or above. However, some years of follow-up were required for us to agree with other authors who also consider a higher flexibilization of the indications⁽²⁴⁾.

The results found and assessed in our series reinforce the idea we had over this period, when, on an year basis, in our outpatient

facilities, the patients were reviewed by assessing their X-ray images. All of this makes us believe that the principles suggested by Spotorno® indeed can be supported by time, and that the concept of the prosthesis and its biomechanics contribute to the endurance of cementless prostheses and to the quality of life of our patients. We conclude that the selection made by the Spotorno® prosthesis in 1985 showed the expected endpoint and we feel very comfortable to know that the prosthesis is still available for occasional intercurrences that may happen over the follow-up of our patients.

CONCLUSIONS

- 1) Total hip arthroplasty with the Spotorno® prosthesis showed 92.7% of good results within a mean follow-up period of 17.5 years.
- 2) Although we have found osteopenia in 44.4% of the acetabular regions, and 55.6% of the femoral portions, these were not significant enough to change the clinical outcome.
- 3) The presence of thigh pain in 3.7% of the cases was lower in comparison to other cementless prosthesis concepts.

REFERÊNCIAS

1. Charnley J. The long-term results of low-friction arthroplasty of the hip performed as a primary intervention. *J Bone Joint Surg Br.* 1972; 54:61-76.
2. Jones LC, Hungerford DS. Cement disease. *Clin Orthop Relat Res.* 1987; (225):192-206.
3. Chandler HP, Reineck FT, Wixson RL, McCarthy JC. Total hip replacement in patients younger than thirty years old. *J Bone Joint Surg Am.* 1981; 63:1426-34.
4. Judet R, Siquier M, Brumpt B, Judet T. A noncemented total hip prosthesis. *Clin Orthop Relat Res.* 1978; (137):76-84.
5. Spotorno L, Romagnoli S, Ivaldo N, Grappiolo G, Bibbiani E, Blaha DJ, et al. The CLS system. Theoretical concept and results. *Acta Orthop Belg.* 1993; 59(Suppl1):144-8.
6. Zweymüller K, Semlitsch M. Concept and material properties of a cementless hip protheses. *Arch Orthop Trauma Surg.* 1982; 100:229-36.
7. Zweymüller K. A cementless titanium hip endoprosthesis system based on press-fit fixation: basic research and clinical results. *Instr Course Lect.* 1986; 35:203-25.
8. Singh M, Nagrath AR. Changes in trabecular pattern of the upper end of the femur as an index of osteoporosis. *J Bone Joint Surg Am.* 1970; 52:457-67.
9. Engh CA, Massin P. X-ray assessment of the biologic fixation of porous surfaced femoral components. *Clin Orthop Relat Res.* 1990; (257):107-28.
10. Merle d'Aubigné R, Postel M. Functional results of hip arthroplasty with acrylic prothesis. *J Bone Joint Surg Am.* 1954; 36:451-75.
11. Zicat B, Engh CA, Gokcen E. Patterns of osteolysis around total hip components inserted with and without cement. *J Bone Joint Surg Am.* 1995; 77:432-9.
12. DeLee JG, Charnley J. Radiological demarcation of cemented sockets in total hip replacement. *Clin Orthop Relat Res.* 1976; (121):20-32.
13. Turbío FM. Alterações radiográficas do fêmur nas artroplastias totais do quadril em prótese não cimentada de Parhofer-Mönch [tese]. São Paulo: Escola Paulista de Medicina - Universidade Federal de São Paulo; 1996.
14. Spotorno L, Schenk RK, Dietschi C. Usere erfahrungen mit nichtzementieren prothesen. *Orthopäde.* 1987; 16:225-38.
15. Bulow JU, Scheller G, Arnold P, Synatschke M. Follow-up (6-9 years) results of the uncemented CLS Spotorno stem. *Arch Orthop Trauma Surg.* 1996; 115:190-4.
16. Haddad RJ Jr, Skalley TC, Cook SD, Brinker MR, Cheramie J, Meyer R et al.. Clinical and roentgenographic evaluation of noncemented porous-coated medullary locking AML and porous coated anatomic PCA total hip arthroplasties. *Clin Orthop Relat Res.* 1990; (258):176-82.
17. Mallory TH, Head W, Lombardi AV Jr. Tapared desing for the cementless total hip arthroplasty femoral components. *Clin Orthop Relat Res.* 1997; (344):172-8.
18. Robinson RP, Lovell TP, Green TM. Hip arthroplasty using the cementless CLS stem. *J Arthroplasty.* 1994; 9:177-92.
19. Jasty MJ, Floyd WE, Schiller AL, Goldring SR, Harris WH. Localized osteolysis in stable non-septic total hip replacement. *J Bone Joint Surg Am.* 1986; 68:912-9.
20. Schmalzried TP, Jasty M, Harris WH. Periprosthetic bone loss in total hip arthroplasty. Polyethylene wear debris and the concept of the effective joint space. *J Bone Joint Surg Am.* 1992; 74:849-63.
21. Raymond PR, Gaston RD, Thomas MG. Uncemented total hip arthroplasty using the CLS Stem: a titanium alloy implant with a corundum blast finish. *J Arthroplasty.* 1996; 11:286-92.
22. Joshi RP, Eftekhari NS, McMahon DJ, Nercessian OA. Osteolysis after charnley primary low friction arthroplasty. A comparison of two matched paired groups. *J Bone Joint Surg Br.* 1998; 80:585-90.
23. Nashed RS, Becker DA, Gustilo RB. Are cementless acetabular components the cause of excess wear and osteolysis in total hip arthroplasty? *Clin Orthop Relat Res.* 1995; (317):19-28.
24. Bläsius K, Cotta H, Schneider U, Thomsen M. CLS-multicenter study-8 years results. *Z Orthop Ihre Grenzgeb.* 1993; 131:547-52.