

USE OF POLYGLYCOLIC ACID TUBE ASSOCIATED WITH FK506 IN REGENERATION OF PERIPHERAL NERVES

MÁRCIO PAULINO COSTA¹, ARMANDO DOS SANTOS CUNHA², CIRO FERREIRA DA SILVA³,
TARCÍSIO E. P. BARROS FILHO⁴, MARCUS CASTRO FERREIRA⁵

SUMMARY

Extensive losses of neural tissue preclude the repair performed by means of primary anastomosis. In those cases, nerve autograft is considered as the treatment of choice. The synthetic tube constituted by polyglycolic acid is an option for nerve graft. The FK506 is an immunosuppressive agent, which increases the neural regeneration rates *in vivo* and *in vitro*. The purpose of this study was to compare, in rats, the degree of neural regeneration, by using histological analysis, a count of the number of regenerated myelinated axons, and a functional analysis, obtained by interposing the autogenous graft (group A), polyglycolic acid tube (group B) and a combination of polyglycolic acid tube with FK506 (group C) in 5-

cm defects of the sciatic nerve. Neuroma formation was observed only in group A. Groups B and C presented similar histological patterns. The quantitative analysis of the number of regenerated myelinated axons has determined that: 1) group B presented, in average, a lower number when compared to the other groups; 2) there was no significant difference between control group A and group C. For functional recovery, there was no statistically significant change between the three groups, despite the qualitative and quantitative histological differences seen.

Keywords: Peripheral nerves / surgery; Nerve regeneration; Polyglycolic acid/therapeutic use; Immunosuppressive Agents/therapeutic use.

INTRODUCTION

Traumas and tumoral resections generally lead to large neural tissue losses, many times precluding primary anastomosis. In those cases, nerve graft is considered as the treatment of choice. It drives the axonal growth and links the ends of distal and proximal stumps, reducing tension at the suture line, a factor that could inhibit neural regeneration⁽¹⁾.

When using autografting, some factors must be considered: 1) it always produces morbidity of the donator area; 2) extensive neural tissue losses demand large amounts of autologous tissue, sometimes insufficient; 3) the use of synthetic materials reduces surgery time^(2,3).

Studies on large neural tissue losses and the need of bridges connecting proximal and distal ends have been conducted during the second half of Nineteenth Century⁽⁴⁾. Some authors used other materials in replacement of nerve graft, such as vessels^(5,6), fascia⁽⁷⁾, plastic tubes⁽⁸⁾, absorbable tubes, silicone tubes⁽⁹⁾, muscle⁽¹⁰⁾ and synthetic tubes⁽¹¹⁾.

The use of absorbable tube made of polyglycolic acid has been extensively investigated in literature⁽¹²⁾ and no statistically significant differences were observed between this approach and the nerve graft for peripheral nerves repair⁽¹³⁾.

Many substances have been assessed for peripheral nerves injuries treatment. Among those, the FK506 (Tacrolimus), an antibiotic isolated in 1984 for the bacteria *Streptomyces tsukubaensis*⁽¹⁴⁾.

Used in primary immunosuppressive therapy, it is the drug of choice as a replacement for cyclosporine in immunosuppression⁽¹⁵⁾. Its major advantage consists of its high immunosuppressive potential associated to few side effects⁽¹⁶⁾. In 1994, it has been shown that FK506 also increased the levels of neural regeneration "*in vivo*"⁽¹⁷⁾ and "*in vitro*"⁽¹⁸⁾. There are no studies in literature describing the use of neurotubes associated to this drug.

MATERIALS AND METHODS

Fifteen 8-week-old Lewis rats, weighing 200 g – 300 g have been used. With a microsurgical technique, 5 mm- extension defects were created on the sciatic nerve of the right foot. The animals were divided into 3 groups of five animals each. In animals from group A (control group), defect repair was performed by suturing the nerve segment removed (autograft), keeping the original direction. In animals from group B, a 10mm segment of a polyglycolic acid tube, with 2.3mm diameter (Neurotube, manufactured by Neurogen L.L.C., Baltimore/U.S.A.) was interposed between sectioned segments. In group C, a segment of polyglycolic acid tube with the same features as used in group B combined to subcutaneous injection of FK506 5mg/kg at the dorsal region of the neck, was interposed. Doses were initiated one hour after injury and then performed in a daily basis until the day of sacrifice⁽¹⁹⁾ (Table 1). For the surgical procedure, the animals were submitted to anesthesia with sodium pentobarbital (5m/kg) injected intraperitoneally.

Study developed at the Microsurgery Laboratory of the Discipline of Plastic Surgery, Medical College, USP.

Correspondences to: Rua Gabriel dos Santos, 759 12 andar - Santa Cecilia - CEP: 01231-011 São Paulo Brasil - E-mail: marciopaulinoc@aol.com

1. Assistant Professor of the Discipline of Plastic Surgery, Medical College, USP.
2. Resident doctor of the Discipline of Plastic Surgery, Medical College, USP.
3. Chairman of the Department of Cellular and Development Biology, Biomedical Sciences Institute, USP.
4. Chairman of the Department of Orthopaedics and Traumatology, Medical College, USP
5. Chairman of the Discipline of Plastic Surgery, Medical College, USP.

Received in: 07/19/05; approved in: 08/08/05

Through the dorsal port on right foot, sciatic nerve was dissected and 5mm of nerve segment were removed (Figures 1, 2 and 3). In group A, the removed segment was sutured in its normal position with 4 epineural separated stitches with mononylon 10.0 (Figure 4). In group B, the polyglycolic acid tube was positioned at 2.5 mm from each end, maintaining a 5-mm neural defect (Figures 5, 6 and 7). In group C, the same technique of polyglycolic acid tube interposition as in group B was used, and, one hour after injury, the FK506 (5 mg/kg) was subcutaneously injected at the dorsal region of the neck; a procedure repeated in a daily basis until the day of sacrifice⁽¹⁹⁾ (Figure 7).

The animals were supplied with water and food *ad libitum* and sacrificed 6 weeks after surgery for histological analysis and for counting the number of regenerated myelinated axons. The evaluation of the functional recovery was performed using a technique that analyzes the impression of posterior feet during walking ("walking track analysis) pre- and postoperatively, on the third week, and at the moment of sacrifice (6 weeks).

The animals were supplied with water and food *ad libitum* and sacrificed 6 weeks after surgery for histological analysis and for counting the number of regenerated myelinated axons. The evaluation of the functional recovery was performed using a technique that analyzes the impression of posterior feet during walking ("walking track analysis) pre- and postoperatively, on the third week, and at the moment of sacrifice (6 weeks).

RESULTS

During the 6 weeks of the study, all animals remained healthy, with no infection on surgical wound or plantar neurodystrophic ulcers.

Histological analysis

Microscopic analysis of Group A (autograft) slides showed that the graft was well bounded by an epineurium formed by fusiform-profile cells. Internally to the epineurium, there was a large amount of myelinated axons, with variable diameters and homogeneously distributed. Tissue reaction around the graft was greater when compared to the other groups. An escape of regenerated fibers exceeding epineurium boundaries was detected in the 5 animals of that group. A subtle amount of axonal bundles was seen (smaller, if compared to groups B and C and more signs of walleriana, if compared to groups B and C (Figures 8, 9 and 10).

Histological sections of the medial portion of regenerated nerve (osmium and toluidine blue), in 6 weeks postoperatively.

In Groups B (tAPG) and C (tAPG+FK506), histological findings were similar. In the 10 animals, tubes had a fusiform appearance, and contained tissue with a neural stroma pattern inside them, with a large amount of myelinated axons, of different sizes, grouped in minifascicles of variable sizes and heterogeneously distributed, presenting conjunctive tissue between them. Between the tube and the neural tissue, an intense neoangiogenesis was seen all around

it, with blood vessels penetrating transversally to the "meshwork" of the polyglycolic acid tube. The presence of a large amount of neoangiogenesis was shown inside regenerated nerve, but this has not occurred in Group A (autograft).

Groups B (tAPG) and C (tAPG+FK506) were

different because there was less neoangiogenesis between the tube and the regenerated nerve in Group C (tAPG+FK506) compared to Group B (tAPG). There was less reactive fibrosis around the tubes when compared to Group A (autograft). No escape of regenerated fibers out of the tube was detected. (Figures 11,12,13,14,15 and 16).

There was no difference in fibers diameter and in the degree of myelination presented by Groups A (autograft), B (tAPG) and C (tAPG+FK506).

Group	Defect	Treatment	Moment of Sacrifice
A (n = 5)	5 mm	Autograft (control)	6 weeks
B (n = 5)	5 mm	tAPG	6 weeks
C (n = 5)	5 mm	TAPG + FK506	6 weeks

Table 1 - Experimental groups features

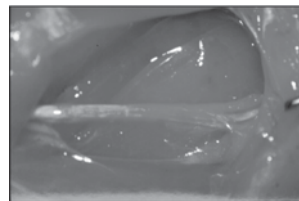


Figure 1 - Sciatic nerve exposed




Figure 2 - 5 mm-defect being performed on sciatic nerve

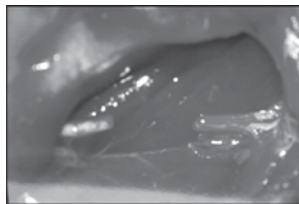


Figure 3 - 5 mm-defect on sciatic nerve

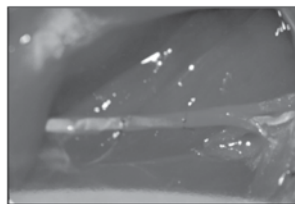


Figure 4 - Group A (autograft)

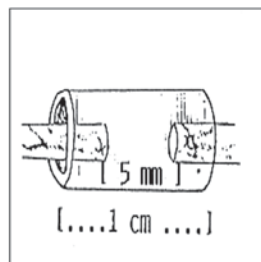


Figure 5- Interposition of the polyglycolic acid tube

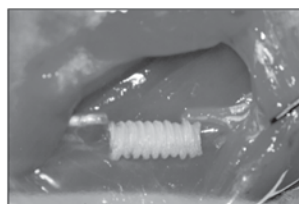

Figure 6 - Polyglycolic acid tube

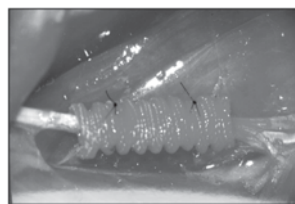


Figure 7 - Group B (tAPG) and Group C (tAPG + FK506)

COUNT OF THE NUMBER OF REGENERATED MYELINATED AXONS

The average number of regenerated myelinated axons, standard deviation and error for each group are represented on Graph 1 (average and standard error).

In group A, an average of $7,225.6 \pm 617.5$ regenerated myelinated axons were counted. In Groups B and C an average of $4,225.2 \pm 376.8$ and $6,459.8 \pm 630.9$ regenerated myelinated axons were observed, respectively. Variance analysis followed

by multiple comparisons by the Tukey method ($p < 0.05$), was used for evaluating data. No statistically significant differences were seen between groups A and C regarding the number of regenerated axons after 6 weeks of nerve sectioning. Group B presented, in average, a higher and statistically significant number of regenerated

myelinated axons when compared to groups A and C. Those data are summarized on Table 2.

FUNCTIONAL STUDY

Figure 17 shows the appearance of rats' footprints pre- and postoperatively for the four groups.

SFIs observed preoperatively were: in Group A, an average of -8.002 ± 5.26 ; in Group B, 928 ± 13.144 ; in Group C, -6.489 ± 7.011 . The statistical analysis by Kruskal-Wallis' method, with a significance level ($p < 0.05$), did not show statistically significant difference among the four groups for the sciatic function index (SFI) preoperatively.

Mean SFI (sciatic function index) postoperative values (immediate, 3 and 6 weeks), calculated for each group are presented on Table 3 (average and standard error).

Immediate postoperative SFIs were, respectively, in average: Group A (autograft) -83.149 ± 4.236 ; Group B (tAPG) -73.378 ± 1.109 ; Group C (tAPG+FK506) -81.050 ± 6.002 and Group D (tAPG+graft) -77.891 ± 1.379 .

SFIs of 3 weeks postoperatively were in average, respectively: Group A (autograft) -71.017 ± 6.240 ; Group B (tAPG) -53.139 ± 4.681 ; Group C (tAPG+FK506) -72.598 ± 7.665 and Group D (tAPG+graft) $-69,486 \pm 0,810$.

SFIs of 6 weeks postoperatively were in average, respectively: Group A (autograft) -51.052 ± 4.994 ; Group B (tAPG) -44.658 ± 2.870 ; Group C (tAPG+FK506) -53.811 ± 3.648 and Group D (tAPG+graft) -50.298 ± 1.585 .

Using the same data presented by the groups regarding postoperative SFI and submitting them to statistical analysis by the variance method with repeated measure (time) and factor (treatment), followed by multiple comparisons by Tukey's method and significance level of ($p < 0,05$), a SFI variation was seen regarding postoperative time, as we will describe below:

In the immediate postoperative time, there was no statistically significant difference among the four assessed groups.

After 3 weeks postoperatively, there was a statistically significant difference between Group B (tAPG) and the other groups (Group A (autograft) and Group C (tAPG+FK506)). There was no statistically significant difference between groups A and C. Those data are summarized on Table 4.

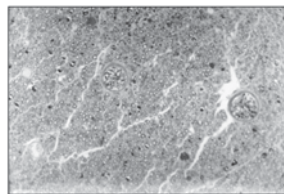


Figure 8 - Group A (autograft): axons of the neural stroma on autograft (200X).

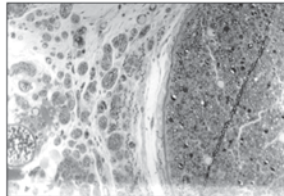


Figure 10 - Group A (autograft): regenerated fibers escaping out of the autograft epineurium boundaries (200X).

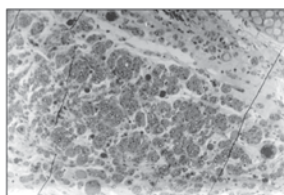


Figure 12 - Group B (tAPG): large amount of myelinated axons, with variable diameters, bundled in minifascicles of multiple sizes (200X).

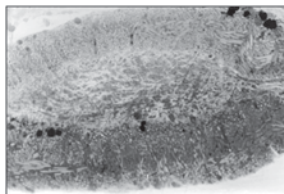


Figure 14 - Group C (tAPG+FK506): fusiform-like tube, containing tissue with neural stroma pattern inside it (50X).

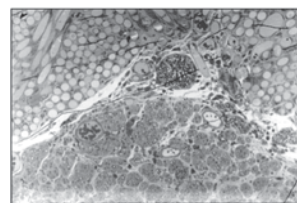


Figure 16 - Group C (tAPG+FK506): transition between tube and neural tissue (200X).

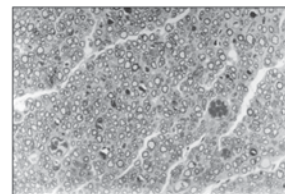


Figure 9 - Group A (autograft): large amount of myelinated axons on autograft, with variable diameters and homogeneously distributed (400X).

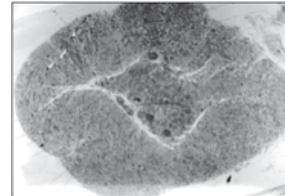


Figure 11 - Group B (tAPG): fusiform-like tube, containing tissue with neural stroma pattern inside it (50X).

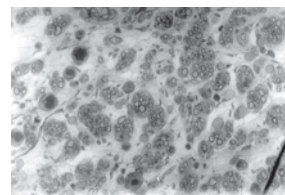


Figure 13 - Group B (tAPG): myelinated axons bundled in minifascicles (400X).

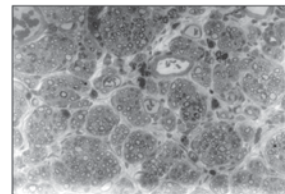


Figure 15 - Group C (tAPG+FK506): myelinated axons, bundled in minifascicles of multiple sizes (400X).

In the postoperative period of 6 weeks, there was no statistically significant difference among the four assessed groups.

DISCUSSION

In cases of peripheral nerves injury with tissue loss, where the extension of the defect precludes primary suture, the best method for repair seems to be the autograft^(2,20). Some factors regarding this topic are relevant, as follows:

1. the need to remove autologous tissue always produces morbidity to donor area; 2. large injuries require the removal of an extensive amount of autogenous tissue, sometimes unavailable; 3. the use of artificial materials does not require the time spent for removing the autograft⁽²⁾; 4. results achieved with the autograft are not fully satisfactory⁽²²⁾.

The interposition of tubular conductors as a bridge between stumps of an injured nerve is showing encouraging experimental and clinical outcomes. For fixing small defects, where the nerve distance is not sufficient to allow chemotactic and chemotropic attraction exerted by the distal stump on the axonal growth region, the results achieved are comparable to those of the autograft^(2,9,12,13,23). Recent studies have been demonstrating the polyglycolic acid tube as an alternative for nerve graft^(12,24,25). Synthetic tubes made

of absorbable material showed better results when compared to non-absorbable ones^(26,27). Absorbable materials cause little fibrotic reaction and the absorption of them do not preclude nerve diameter to grow⁽²⁶⁾, as opposite to what occurs with those made of non-absorbable materials.

The use of substances associated to tubing chambers shows an important role in the development of better functional results after peripheral nerve

injury. The FK506 is a new immunosuppressive agent^(15,28) 10 to 100 times more powerful than cyclosporine⁽²⁹⁾. It presents fewer side effects⁽¹⁹⁾ and is being used successfully in heart, kidney and liver transplants^(15,30,31). Some explanations have been suggested by biochemists for understanding neurons regeneration and growth process with the FK506. This antibiotic causes an immunosuppressive effect, inhibiting calcineurine activity (it plays an important role in the T-cells proliferation regulation). In addition, the FK506 bonds to the immunophilin FKBP-12 enhancing "Gap-43" (asso-

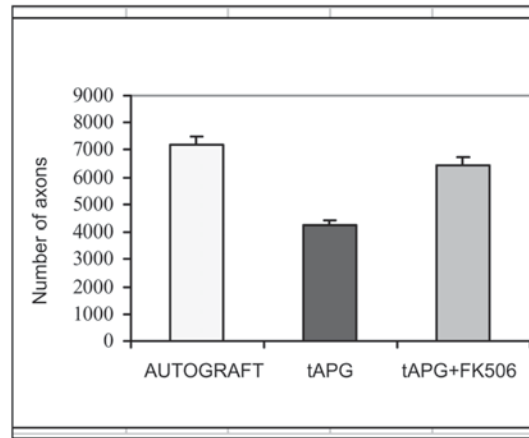
ciated growth protein 43) phosphorylation, activating it. "Gap-43" plays a relevant role in the axonal elongation process⁽¹⁸⁾. Therefore, the FK506 could hasten axonal regeneration through a direct effect over axonal buds growth.

In group A, the use of an autograft is considered as the treatment of choice for the repair of neural defects with tissue loss^(2,32). In group B, the polyglycolic acid tube has already been used as an alternative for nerve graft in primates when tissue loss is less than 30 mm^(12,24,25,33). In group C, the tube was associated to a drug enhancing neural growth^(17,34,35). The development of neuroma was seen only in rats submitted to autografts⁽³⁶⁾. No tube collapse was observed in groups B and C, although this complication has been described^(2,12).

In group A, fibers out of the epineurium boundaries and neuroma formation along suture lines were observed. Those changes have previously been mentioned by other authors^(9,36). No fibers out of the boundaries of the epineurium were seen in the groups using tubes.

Regarding histological aspects, groups B and C presented with similar patterns. It is known that FK506 increases axonal regeneration rates^(17,19,35,37). When administered during different periods, it proportionally increases the number of myelinated fibers^(19,37,38), more extensive axons^(19,37), longer fibers⁽³⁷⁾ and a more advanced maturation period^(17,37,38).

Hypotheses intending to explain those properties are focused on a reduced level of regenerative buds destruction⁽¹⁹⁾ and on an increase of the myelination process, leading to the formation of thicker fibers and an increased speed towards target organs^(37,38).



Graph 1 - Number of Axons
Graph 1- Number of regenerated myelinated axons compared to the kind of treatment employed

Number	of	Axons
autograft (A)	=	tAPG + FK506 (C)
autograft (A)	≠	tAPG (B)
tAPG(B)	≠	tAPG + FK506 (C)

≠ denotes a statistically significant difference

Table 2 - Variance analysis with one factor (treatment), followed by multiple comparisons by Tukey's method and with a significance level ($p < 0.05$) of the number of regenerated myelinated axons.

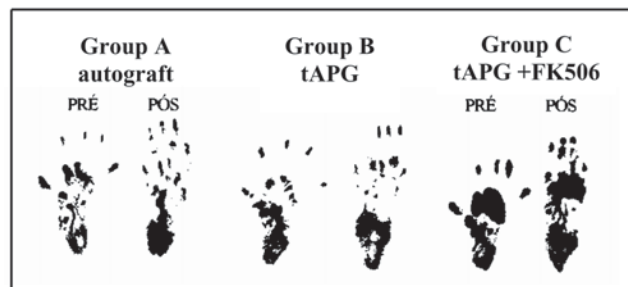


Figure 17 - Rats' footprints appearance at pre-operative and post-operative periods in the three groups.

TREATMENT	POSTOPERATIVE SFI					
	IMMEDIATE	3 weeks	6 weeks	SE - IMM	SE - 3w	SE - 6w
Autograft	-83.149	-71.015	-51.052	4.236	6.240	4.994
TAPG	-73.378	-53.139	-44.658	1.109	4.681	2.870
tAPG+FK506	-81.050	-72.598	-53.811	6.002	7.665	3.648

Table 3 - Postoperative SFI (immediate, 3 and 6 weeks) according to the kind of treatment employed.

TAPG	≠	autograft
tAPG	≠	tAPG + FK506
autograft	=	tAPG + FK506

≠ denotes a statistically significant difference, showing a better SFI in group B.

Table 4 - Statistical analysis of 3-week postoperative SFI by the variance method with repeated measurement (time) and one factor (treatment) followed by multiple comparisons by Tukey's method and significance level of ($p < 0.05$).

Despite FK506's properties related to neural regeneration described in literature, a great difference between groups B and C was not seen. The variation of the fiber diameter, distribution in variable-sized minifascicles heterogeneously located, neoangiogenesis, degree of Wallerian degeneration, absence of escape, cicatricial reaction, and the amount of axons bundles behaved similarly regarding the presence of myelinated axons. The difference between groups B and C was a lower degree of neoangiogenesis between the tube and the regenerated nerve in group C.

The average number of regenerated myelinated axons in group B was the lowest. The combination of FK506 with the polyglycolic acid tube increased the average number of regenerated myelinated axons, but did not show a statistically significant difference when compared to control group. This potential to increase the average number of regenerated axons corroborates literature findings^(37,38).

Regarding functional evaluation, there were no differences between the immediate and the late postoperative periods. However, in the 3-week period, the SFI average for group B was the best, if compared to other groups, and there was no difference between groups A and C. The difference between functional findings and axons counts may be explained by the importance of re-established connections accuracy of the regenerated axons with target organs and not to the total number of fibers verified^(40,41). Expectations are indeed very good for further researches with the neurotubes, considering more adequate and cheaper materials to be used in lar-

ge scale yielding better functional outcomes, as well as the search for substances that might hasten neural regeneration and iatrogenic effects prevention processes.

CONCLUSIONS

The combination of FK506 to a polyglycolic acid tube did not cause changes to histological patterns when compared to the

polyglycolic acid tube alone. Furthermore, there was no significant increase of the number of myelinated axons when compared to control group. In the group where the polyglycolic acid tube alone was used, in average, a lower number of regenerated myelinated axons were seen if compared to the other two groups, but there wasn't any statistically significant functional difference among the three groups.

REFERENCES

1. Terzis J, Faibisoff B, Williams HB. The nerve gap: suture under tension vs. graft. *Plast Reconstr Surg.* 1975; 56:166-70.
2. Brunelli GA, Vigasi A, Brunelli GR. Different conduits in peripheral nerve surgery. *Microsurgery.* 1994; 15:176-8.
3. Keeley RD, Nguyen KD, Stephanides MJ, Padilla J, Rosen JM. The artificial nerve graft: a comparison of blended elastomer-hydrogel with polyglycolic acid conduits. *J Reconstr Microsurg.* 1991;7:93-100.
4. Glück T. Ueber neuropastik auf dem weg der transplantation. *Arch Klinik Chirurg.* 1880; 25:606-16.
5. Foramitti C. Zur Technik der Nervennaht. *Arch Klinik Chirurg.* 1904; 73: 643-8.
6. Swan JJ. Discussion on injuries to the peripheral nerves. *Proc R Soc Med.* 1941; 34:521-32.
7. Kirk EG, Lewis D. Fascial tubulization in the repair of nerve defects. *JAMA.* 1915; 65:486-92.
8. Garrity RW. The use of plastics and rubber tubing in the management of irreparable nerve injuries. *Surg Forum.* 1955; 6:517-20.
9. Lundborg G, Gelberman RH, Longo RM. In vivo regeneration of cut nerves encased in silicone tubes: Growth across a six millimeter gap. *J Neuropathol Exp Neurol.* 1982; 41:412-22.
10. Sanes J, Marshall LM, Mc Mahan UJ. Reinnervation of muscle fiber basal lamina after removal of myofibres. Differentiation of regenerating axons at original synaptic sites. *J Cell Biol* 1978; 78:176-8.
11. Molander H, Olsson Y, Engkvist O, Bowald S, Eriksson I. Regeneration of peripheral nerve through polyglactin tube. *Muscle Nerve.* 1982; 5:54-7.
12. Mackinnon SE, Dellon AL. Clinical nerve reconstruction with a bioabsorbable polyglycolic acid tube. *Plast Reconstr Surg.* 1990; 85:419-24.
13. Hentz VR, Rosen JM, Xiao SJ, McGill KC, Abraham G. A comparison of suture and tubulization nerve repair technique in a primate. *J Hand Surg Am.* 1991; 16: 251-61.
14. Kino T, Hatanaka H, Hashimoto M, Nishiyama H. Fk506, a novel immunosuppressant isolated from a streptomycetes. Fermentation, isolation and physiochemical na biological characteristics. *J Antibiot.* 1987; 40:1249-55.
15. Jain LF, Fung JJ. Cyclosporin and tacolimus in clinical transplantation. A comparative review. *Clin Immunother.* 1996; 5:351-73.
16. Starzl TE, Todo S, Fung J, Demetris AJ, Venkataraman R, Jain A. FK506 for liver, kidney and pancreas transplantation. *Lancet.* 1989; 2:1000-4.
17. Gold BG, Storm-Dickerson T, Austin DR. The immunosuppressant FK506 increase functional recovery and nerve regeneration following peripheral nerve injury. *Restor Neurol Neurosci.* 1994; 6:287-96.
18. Lyons WE, George EB, Dawson TM, Steiner JP, Snyder SH. Immunosuppressant FK506 promotes neurite outgrowth in cultures of PC12 cells and sensory ganglia. *Proc Natl Acad Sci USA.* 1994; 91:3191-5.
19. Wang MS, Zeleny-Pooley M, Gold BG. Comparative dose-dependent study of FK506 an cyclosporine A on the rate of axonal regeneration in the rat sciatic nerve. *J Pharm Exp Ther.* 1997; 282:1084-93.
20. Sunderland S. Nerves and nerve injuries. New York: Churchill Livingstone; 1978.
21. Keeley R, Atagi T, Sahelmann E, Padilla J, Kadloik S, Keeley K, Nguyen K, Rosen J. Peripheral nerve regeneration across 14mm gaps: a comparison of autograft and entubulation repair method in the rat. *J Reconstr Microsurg.* 1993; 9: 349-59.
22. Kitahara AK, Nishimura Y, Shimizu Y, Endo K. Facial nerve repair accomplished by interposition of a collagen nerve guide. *J Neurosurg.* 2000; 93: 113-20.
23. Muller H, Dombert T, Terzis J, Arnold H. Axonal growth on laminin containing substrats. *Microsurgery.* 1993; 14:33.
24. Dellon AL, Mackinnon SE. An alternative to the classical nerve graft for the management of the short nerve gap. *Plast Reconstr Surg.* 1988; 82:849-56.
25. Pham HN, Padilla JA, Nguyen KD, Rosen JM. Comparison of nerve repair techniques: suture vs avitene-polyglycolic acid tube. *J Reconstr Microsurg.* 1991; 7: 31-6.
26. Madison R, Da Silva CF, Dikkes P, Chiu TH, Sidman RL. Increased rate of peripheral nerve regeneration using bioresorbable nerve guides and a laminin containing gel. *Exp Neurol.* 1985; 76:767-72.
27. Nyilas E, Chiu TH, Sidman RL. Synthetic bioresorbable polymers: 1. Polyester and polyester-composite guidance channels for peripheral nerve repair. *Trans Am Soc Artif Intern Organs.* 1983; 6:85.
28. Goto T, Kino T, Hatanaka T. Discovery of FK-506, a novel immunosuppressant isolated from *Streptomyces tsukubaensis*. *Transplant Proc.* 1987;19:4-8.
29. Kino T, Goto T. Discovery of FK-506 and update. *Ann NY Acad Sci.* 1993; 685: 13-21.
30. Shapiro HJ, Jordan M, Fung J. Kidney transplantation under FK-506 immunosuppression. *Transplant Proc.* 1991; 23: 920-23.
31. Starzl TE, Abu-Elmagd K, Tzakis A. Selected topics on FK-506, with special references to rescue of extrahepatic whole organ grafts, transplantation of "forbidden" organs, side effects, mechanisms, and practical pharmacokinetics. *Transplant Proc.* 1991; 23, 914-9.
32. Rosen JM, Hentz VR, Kaplan EN. Fascicular tubulization: a cellular approach to peripheral nerve repair. *Ann Plast Surg.* 1983; 11: 397.
33. Gold BG, Densmore V, Shou W, Matzuk MM, Gordon HS. Immunophilin FK506-binding protein 52 (not FK506 binding protein 12) mediates the neurotrophic action of FK506. *J Pharm Exp Term.* 1999; 289: 1202-10.
34. Fansa H, Keilhoff G, Altmann S, Plogmeier K, Wolf G, Schneider W. The effect of the immunosuppressant FK506 on peripheral nerve regeneration following nerve grafting. *J Hand Surg.* 1999; 24:38-42.
35. Bora Jr FW, Bednar JM, Osterman AL, Brown MJ, Summer AJ. Prosthetic nerve grafts: a resorbable tube as an alternative to autogenous nerve grafting. *J Hand Surg Am.* 1987; 12: 685-92.
36. Gold BG, Katoh K, Storm-Dickerson T. The immunosuppressant FK 506 increases the rate of axonal regeneration in rat sciatic nerve. *J Neurosci.* 1995; 15: 7509-16.
37. Doolabh V, Mackinnon SE. FK506 accelerates functional recovery following nerve grafting in a rat model. *Plast Reconstr Surg.* 1999; 103:1928.
38. Cole JS, Messing A, Trojanowski JQ, Lee VM. Modulation of axon diameter and neurofilaments by hypomyelinating Schwann cells in transgenic mice. *J Neurosci.* 1994; 14: 6956-66.
39. Thomas PK. The cellular response to nerve injury. The effect of repeated crush injuries. *J Anat.* 1970; 106:463-70.
40. De Medinaceli L. Interpreting nerve morphometry data after experimental traumatic lesions. *J Neurosci Methods.* 1995; 58:29-37.