

TOMOGRAPHIC CORRELATION FOR MAGERL'S TECHNIQUE IN C1-C2 ARTHRODESIS IN CHILDREN

BÁRBARA CAMARGO CHIARAMONTI¹, SO YEON KIM¹, LUIZ ROBERTO DELBONI MARCHESI¹, OLAVO BIRAGHI LETAIF¹, RAPHAEL MARTUS MARCON¹, ALEXANDRE FOGAÇA CRISTANTE¹

ABSTRACT

Objective: To analyze through tomographic studies, the morphology and dimensions of the C1-C2 vertebrae in pediatric patients, to evaluate the possibility of application of Magerl's technique in these patients, and to contribute with data for the usage of the technique in safety. **Method:** Forty normal cervical tomographies, from patients at an age range of 24-120 months of age and from both genders, were retrospectively analyzed. Data was statistically analyzed to obtain mean value and variations of each measurement: length from the C2's pedicle to C1's lateral mass, thickness of the pedicle of C2,

the attack angle of the screw at the C2 isthmus with the horizontal axis and the distance from the odontoid to the anterior arch of C1. **Results:** The mean values obtained were: length right 30.86 mm, left 31.47 mm; thickness right 5.28 mm, left 5.26 mm; attack angle right 46.25^o, left 44.50^o; distance from odontoid to anterior arch of C1 2,17 mm. **Conclusion:** The Magerl technique, after tomographic study, seems to be a viable option to be used in pediatric patients. **Level of Evidence IV, Case Series.**

Keywords: Spinal fusion. Child. Tomography, x-ray computed.

Citation: Chiaramonti BC, Kim SY, Marchese LRD, Letaif OB, Marcon RM, Cristante AF. Tomographic correlation for Magerl's technique in C1-C2 arthrodesis in children. *Acta Ortop Bras.* [online]. 2013;21(5):255-7. Available from URL: <http://www.scielo.br/aob>.

INTRODUCTION

Countless conditions can affect the atlantoaxial anatomical complex: traumatic, degenerative, inflammatory, neoplastic or even congenital.¹ Atlantoaxial instability is a rare condition in the pediatric population. There are some characteristics that predispose to this lesion: greater ligament laxity, more horizontally oriented facets, premature ossification, higher fulcrum of cervical movement, greater deforming force due to the disproportionate head/body ratio.²⁻⁶

Several techniques were described for the treatment of C1-C2 instability. In 1910, Mixter and Osgood⁷ described the use of silk threads to wire the spinous processes of C1 and C2 together. Some years later in 1939, Gallie⁸ described the C1 and C2 laminar encircling technique. Later in 1978, Brooks and Jenkins⁹ described a modified C1-C2 laminar wiring technique, which was once again modified by Dickman *et al.*¹⁰ Encircling techniques have the disadvantages of presenting a risk of neurological lesions in the passage of the wires, the need to use a rigid external orthosis, and high rates of non-consolidation.^{7,11-13}

The Jeanneret and Magerl,¹⁴ Wright,¹⁵ Harms and Melcher¹⁶ techniques were described recently. They are posterior fixation techniques with C1-C2 transarticular screws; screws in the C1 lateral masses, in the C2 lamina and in the C2 pedicle. Transarticular screw fixation is being used with greater frequency, with good results shown in the literature.¹⁷

The treatment of C1-C2 instability in children remains controversial.¹⁷ Some techniques initially described for treatment in adults were recently employed in the pediatric population with a satisfactory outcome.¹⁸ It is essential to have anatomical knowledge of pediatric cervical structures to be able to use this technique safely.¹⁹

This study aimed to evaluate the dimensions of the anatomical structures of C1 and C2 in the Brazilian pediatric population, and to enable more in-depth discussions regarding the technique used to stabilize these vertebrae, as well as to provide data for performance of Magerl's technique while ensuring greater patient safety, taking into account both the anatomy and the screws available in the market.

All the authors declare that there is no potential conflict of interest referring to this article.

1. Institute of Orthopedics and Traumatology of Hospital das Clínicas da Faculdade de Medicina da Universidade de São Paulo, São Paulo – SP, Brazil.

Work performed at LIM 41 – Laboratory of Medical Investigation of the Musculoskeletal System of the Department of Orthopedics and Traumatology of Faculdade de Medicina da Universidade de São Paulo, São Paulo, SP, Brazil.
Corresponding: Rua Dr. Ovidio Pires de Campo, 333. Centro de Atendimento ao Traumatizado Raquimedular – CENATRA do IOT/HC/FMUSP05403-010, São Paulo, SP, Brazil.
bchiara@uoi.com.br

Article received on 6/11/2013 and approved on 7/12/2013.

Acta Ortop Bras. 2013;21(5):255-7

METHODS

We retrospectively analyzed 40 cervical tomography scans of patients between 24 and 120 months of age, of both sexes and without cervical deformities. The tomography scans were acquired through all the patient consultations performed at the complex of Hospital das Clinicas FMUSP, both outpatient and emergency room. The dimensions and angulations of the cervical laminae were evaluated using the ImageJ® imaging program. All the measurements were made in millimeters. The inclusion criteria were: age between 24 and 120 months and without deformities in the cervical spine, while the exclusion criteria were: age (under 24 months and over 120 months) and alterations in the computed tomography of the cervical spine. The data obtained by the study were submitted to statistical analysis to obtain mean values and the variation for each measurement taken.

The measurements of the C1 and C2 cervical vertebrae were taken in the sagittal section in the following manner, as shown by the model below. (Figure 1)

Measurement A: anterior arch - dens (from the posterior cortex of C1 anterior arch and anterior dens cortex);

Measurement B: Length of the C2 pedicle (from the posterior cortex of the C2 pars, obliquely in the direction of the anterior cortex of the C1 lateral mass);

Measurement C: Thickness of the C2 pedicle (at the narrowest point of the pedicle and at a 90 degree angle with its long measurement, from the posterior superior pedicular cortex to the anterior inferior pedicular cortex);

Measurement D: Angle of attack of C2 with the horizon (angle of attack for the insertion of the screw in the posterior cortex of the C2 pars, crossing the pedicle and approaching the anterior cortex of the C1 lateral mass);

Individual measurements were taken for the right and left sides for measurements B, C and D.

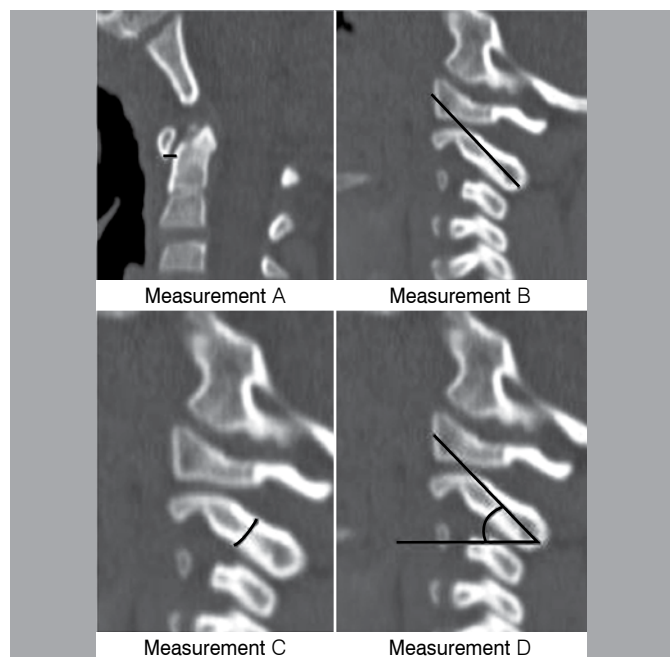


Figure 1. Model of obtention of the measurements in the sagittal section of the C1-C2 tomography.

RESULTS

The 40 tomographies included in the study were analyzed and the mean value of the measurements obtained. Their respective standard deviations are represented in Table 1.

The values were submitted to the Kolmogorov-Smirnov Test and it was concluded that the sample distribution is normal. The comparative analysis between left and right sides for the measurements of C2 pedicle length, C2 pedicle diameter and angle of attack of the screw with the horizontal axis did not reveal significant difference ($p < 0.05$) through the t-test. The maximum and minimum values obtained for these measurements were included in Table 2.

Comparatively between the sexes, of the 40 tomographies analyzed, 26 patients were male and 14 female and the statistical analysis carried out using the t-test revealed that there is no difference between the sexes for the aforesaid measurements ($p < 0.05$), except for the measurement of distance from the dens to the C1 arch which presented a $p = 0.03$ in the t-test. In spite of a difference in age, among the men the average age was 6.04 years and among the women, 7.19 years. This difference was not significant ($p < 0.05$) according to the t-test. Table 3 shows the data obtained. The values are not discriminated according to their side, since based on the above, it is concluded that there is no difference between sides.

The data were also stratified into two groups: 24 to 72 months (15 patients) and 73 to 120 months (25 patients). The Kolmogorov-Smirnov Test was applied as before, and it was concluded that the distribution is normal. Table 4 shows the mean values obtained and their respective standard deviations. The statistical analysis of the data revealed significant difference ($p < 0.05$) between the two groups for the values of C2 pedicle length to

Table 1. Mean values obtained for each side.

	Length from the C2 pedicle to the C1 mass	Thickness of the C2 pedicle in the direction of the C1 lateral mass	Angle of attack of the screw with the horizontal axis
Right	30.68 mm (\pm 3.75)	5.28 mm (\pm 0.64)	46.24 (\pm 8.31)
Left	31.47 mm (\pm 3.65)	5.26 mm (\pm 0.75)	44.5 (\pm 8.24)

Table 2. Maximum and minimum values obtained for each side.

	Length from the C2 pedicle to the C1 mass		Thickness of the C2 pedicle in the direction of the C1 lateral mass		Angle of attack of the screw with the horizontal axis	
	Right	Left	Right	Left	Right	Left
Maximum value	36.2 mm	37.0 mm	6.6 mm	6.5 mm	64	58
Minimum value	22.3 mm	22.3 mm	3.9 mm	3.4 mm	29	25

Table 3. Mean values obtained between the sexes.

	Length from the C2 pedicle to the C1 mass	Thickness of the C2 pedicle in the direction of the C1 lateral mass	Angle of attack of the screw with the horizontal axis	Distance from the dens to the C1 anterior arch
Male	31.43 mm (\pm 3.6)	5.34 mm (\pm 0.69)	45.03 (\pm 8.76)	2.27 mm (\pm 0.47)
Female	30.41 mm (\pm 3.85)	5.13 mm (\pm 0.69)	46 (\pm 7.19)	1.99 mm (\pm 0.31)

Table 4. Mean values obtained and their standard deviations discriminated between ages.

	Length from the C2 pedicle to the C1 mass	Thickness of the C2 pedicle in the direction of the C1 lateral mass	Angle of attack of the screw with the horizontal axis	Distance from the dens to the C1 anterior arch
24 to 72 months	29.49 mm (± 3.53)	4.82 mm (± 0.56)	45.23 (± 8.02)	2.35 mm (± 0.46)
73 to 120 months	32.02 mm (± 3.5)	5.54 mm (± 0.63)	45.46 (± 8.4)	2.07 mm (± 0.39)

the C1 mass and of C2 pedicle thickness through the t-test. For the values of the angle of attack and distance from dens to C1 arch there was not any statistically significant difference ($p > 0.05$) through the t-test between the two groups.

DISCUSSION

Instability in the C1-C2 cervical vertebrae can be treated conservatively, with a cervical collar, or surgically, depending on clinical and radiographic parameters. Once surgical treatment has been decided on, there is a variety of options of techniques to perform arthrodesis. As they present greater stability, the recent techniques of fixation with screws confer high rates of consolidation, do not need a postoperative collar, and are the method of choice at present.

Magerl's technique stabilizes the C1-C2 joint with the use of transarticular screws.^{17,20} The screws are inserted 2 mm medial to the spinous process and 3 mm above the articular process of C2 with C3. They should be passed through the C2 isthmus with a verticalized insertion angle in the direction of the C1 lateral

mass. This technique uses 3.5 mm screws, and this diameter is the minimum condition for their use.

Based on the results obtained, the mean value of the pedicle thickness was 5.28 mm for the side right and 5.26 mm for the left, with a minimum value of 3.4 mm and maximum of 6.6 mm. In our study, all the values of the pedicle diameter admit insertion of the 3.5 mm screw, except for the measurement of 3.4 mm, which may be due to a measurement error or anatomical variation.

The laminar length did not show statistically significant differences (averaging 30.68 mm on the right and 31.47 mm on the left) comparing side and sex in our study, showing statistically significant differences only when subdivided by age (24-72 months and 72-120 months), but both mean values found are compatible with the screws available for use.

The angle of attack had mean values of 46.25° for the side right and 44.5° for the side left, without statistically significant difference when compared between sex, age and side. The value of the angle is compatible with the value used in clinical practice. Based on the results shown in our study, Magerl's technique is viable in the pediatric population, using screws available in the market. The literature contains few tomographic anatomical studies of the cervical spine for use of arthrodesis techniques in the pediatric population,¹⁹ and our study is one of the pioneers in the area. Future studies will be able to study the validation of the technique in this population in more depth and endorse its safety.

CONCLUSION

According to the anatomical measurements taken, through analysis by computed tomography, Magerl's technique is viable in the pediatric patients studied.

REFERENCES

- Clark CR. The cervical spine. 4th ed. Philadelphia: Lippincott Williams & Wilkins; 2005.
- Hadley MN, Zabramski JM, Browner CM, Rekate H, Sonntag VK. Pediatric spinal trauma. Review of 122 cases of spinal cord and vertebral column injuries. *J Neurosurg.* 1988;68(1):18-24.
- Heffez DS, Ducker TB. Fracture and dislocations of the pediatric spine. In: Pang D, editor. Disorders of the pediatric spine. New York: Raven Press; 1995. p. 517-29.
- Hill SA, Miller CA, Kosnik EJ, Hunt WE. Pediatric neck injuries. A clinical study. *J Neurosurg.* 1984;60(4):700-6.
- Powers B, Miller MD, Kramer RS, Martinez S, Gehweiler JA Jr. Traumatic anterior atlanto-occipital dislocation. *Neurosurgery.* 1979;4(1):12-7.
- Ruge JR, Sinson GP, McLone DG, Cerullo LJ. Pediatric spinal injury: the very young. *J Neurosurg.* 1988;68(1):25-30.
- Mixter SJ, Osgood RB. IV. Traumatic Lesions of the Atlas and Axis. *Ann Surg.* 1910;51(2):193-207.
- Gallie W. Fractures and dislocations of the cervical spine. *Am J Surg.* 1939;46:495-9.
- Brooks AL, Jenkins EB. Atlanto-axial arthrodesis by the wedge compression method. *J Bone Joint Surg Am.* 1978;60(3):279-84.
- Dickman CA, Sonntag VK, Papadopoulos SM, Hadley MN. The interspinous method of posterior atlantoaxial arthrodesis. *J Neurosurg.* 1991;74(2):190-8.
- Dickman CA, Crawford NR, Paramore CG. Biomechanical characteristics of C1-2 cable fixations. *J Neurosurg.* 1996;85(2):316-22.
- Hanley EN Jr, Harvell JC Jr. Immediate postoperative stability of the atlantoaxial articulation: a biomechanical study comparing simple midline wiring, and the Gallie and Brooks procedures. *J Spinal Disord.* 1992;5(3):306-10.
- Glaser JA, Whitehill R, Stamp WG, Jane JA. Complications associated with the halo-vest. A review of 245 cases. *J Neurosurg.* 1986;65(6):762-9.
- Jeanneret B, Magerl F. Primary posterior fusion C1/2 in odontoid fractures: indications, technique, and results of transarticular screw fixation. *J Spinal Disord.* 1992;5(4):464-75.
- Wright NM. Posterior C2 fixation using bilateral, crossing C2 laminar screws: case series and technical note. *J Spinal Disord Tech.* 2004;17(2):158-62.
- Harms J, Melcher RP. Posterior C1-C2 fusion with polyaxial screw and rod fixation. *Spine (Phila Pa 1976).* 2001;26(22):2467-71.
- Finn MA, Apfelbaum RI. Atlantoaxial transarticular screw fixation: update on technique and outcomes in 269 patients. *Neurosurgery.* 2010;66 (3Suppl):184-92.
- Rahimi SY, Stevens EA, Yeh DJ, Flannery AM, Choudhri HF, Lee MR. Treatment of atlantoaxial instability in pediatric patients. *Neurosurg Focus.* 2003;15(6):ECP1.
- Cristante AF, Torelli AG, Kohlmann RB, Dias da Rocha I, Biraghi OL, Lutaka AS, et al. Feasibility of intralaminar, lateral mass, or pedicle axis vertebra screws in children under 10 years of age: a tomographic study. *Neurosurgery.* 2012;70(4):835-8.
- Magerl F, Seemann P. Stable posterior fusion of the atlas and axis by transarticular screw fixation. In: Kehr P, editor. Cervical spine. Austria: Springer-Verlag; 1987. p. 322-7.