

COMPARISON OF LCP AND INTRAMEDULLARY NAIL OSTEOSYNTHESIS IN CALCANEAL FRACTURES

COMPARAÇÃO ENTRE PLACA DE OSTEOSSÍNTESE E HASTE INTRAMEDULAR EM FRATURA DO CALCÂNEO

JAROSLAV ZEMAN¹, PETR ZEMAN¹, TOMAS MATEJKA¹, JAROSLAV BELATKA¹, JIRI MATEJKA¹

1. Charles University, Faculty of Medicine in Pilsen, Department of Orthopaedics and Locomotive Apparatus Traumatology, Pilsen, Czech Republic.

ABSTRACT

Objective: This study compared groups of patients with calcaneal fractures of Sanders types II and III. One group was treated with ORIF using an LCP (plate), while the second was treated with a minimally invasive method using a C-Nail. **Methods:** The study included 217 patients in the ORIF group and 19 patients in the minimally invasive nail osteosynthesis group. **Results:** In the LCP group, the outcomes were excellent for 35.7% of the patients; good, 38.9%; satisfactory, 19.7%; and poor, 5.7%. In the C-Nail group, the outcomes were excellent for 36.9% of the patients; good, 31.6%; satisfactory, 21%; and poor, 10.2%. The mean values of the restoration of Böhler's angle from post-injury were 6.8° to 32.3° in the LCP group and 7.1° to 33.3° in the C-Nail group. After 12 months, there was only a minimal decrease in Böhler's angle to 29.2° in both the LCP and C-Nail groups. **Conclusion:** The outcomes obtained with C-Nail fixation are statistically identical to those obtained with LCP fixation. We conclude that osteosynthesis with a C-Nail is suitable as the first-choice treatment for Sanders types II and III fractures. **Level of evidence IV, retrospective observational study.**

Keywords: Minimally Invasive Surgery. Heel Bone. Bone Nail. Bone Plate.

RESUMO

Objetivo: Comparar grupos de pacientes com fratura intra-articular do calcâneo tipos II e III de Sanders. **Métodos:** Estudo retrospectivo que incluiu 217 pacientes no grupo tratado por redução aberta e fixação interna com placa de compressão (Grupo PC) e 19 pacientes que seguiram um método minimamente invasivo com C-Nail. **Resultados:** No Grupo PC, os resultados foram excelentes em 35,7%, bons em 38,9%, satisfatórios em 19,17% e ruins em 5,7%. Os resultados registrados no grupo que recebeu implante de unha foram excelentes em 36,9%, bons em 31,6%, satisfatórios em 21% e ruins em 10,2%. Os valores médios do restauro do ângulo de Böhler desde o pós-ferimento variaram entre 6,8° e 32,3°, no Grupo PC, e entre 7,1° e 33,3°, no grupo tratado com C-Nail. Ao fim de 12 meses, apenas se observou redução mínima do ângulo de Böhler para 29,2° nos dois grupos. **Conclusão:** Os resultados do método recentemente introduzido de osteossíntese minimamente invasiva com C-Nail são estatisticamente idênticos aos obtidos pela redução aberta e fixação interna com placa de compressão. Assim, o novo tipo de osteossíntese com C-Nail é adequado como primeira escolha em fraturas do tipo Sanders II e III. **Nível de evidência IV, Estudo retrospectivo de observação.**

Descritores: Procedimentos cirúrgicos minimamente invasivos. Calcâneo. Pinos ortopédicos. Placas ósseas.

Citation: Zeman J, Zeman P, Matejka T, Belatka J, Matejka J. Comparison of LCP and intramedullary nail osteosynthesis in calcaneal fractures. Acta Ortop Bras. [online]. 2019;27(6):288-93. Available from URL: <http://www.scielo.br/aob>.

INTRODUCTION

Calcaneal fractures are injuries resulting in long-term disqualification of patients from their usual way of life. The objective of surgical treatment is anatomical restoration of all articular surfaces, above all the posterior heel area, restoration of the height, length, width and axis of the calcaneus and primarily stable osteosynthesis. Since 2005 has been using the method of open reduction and internal fixation with a Locking Calcaneal Plate (DePuy Synthes, 325 Paramount Drive, Raynham, MA 02767, USA) in our department. These pointed to good results and an adequate number of

complications.^{1,2} We added a minimally invasive osteosynthesis technique using the intramedullary C-Nail (Medin, a.s., Vlachovicka 619, 592 31 Nove Mesto na Morave, Czech Republic) to our surgical portfolio in 2014.

MATERIALS AND METHODS

The sample included only intra-articular fractures treated with plates of nails. Our surgical sample included 212 patients with 236 calcaneus fractures. These included 30 women (14.1%) and 182 men (85.9%), mean age 39.2 years (12 - 62 years).

All authors declare no potential conflict of interest related to this article.

The study was conducted at the Faculty of Medicine in Pilsen, Charles University, Pilsen, Czech Republic. Correspondence: Jiri Matejka, Pod Vsemlí svatými 75, CZ 30100 Pilsen, Czech Republic. matejka@fnplzen.cz



The 236 fracture operations consisted in the use of the open reduction internal fixation (ORIF) method with plate in 217 and miniinvasive osteosynthesis using nail in 19 cases.

Of the 217 patients treated with LCP, the following patients were included in Sanders classification groups and types. (Table 1)

From August 2005 to June 2017 we treated types II and III intra-articular calcaneal fractures using the method of open reduction internal fixation (ORIF) Locking Calcaneal Plate (LCP). Starting in early 2014 till June 2017 we also treated type II Sanders fractures with the calcaneal C-Nail method. The nail is made of steel, 65 mm long and 8 mm in diameter. Using an end cap it can be extended in 5 mm steps up to 85 mm. The nail comes in left and right modalities.

The fractures were classified based on the CT acc. to Sanders into type I – IV. Therapy with ORIF from an extended lateral approach was indicated in patients with intra-articular calcaneal fracture with dislocation of the articular surface of more than 1 mm, fractures with shortening of the axial deviation of the calcaneus (more than 10 degrees valgus / more than 5 degrees varus), i.e., types II and III fractures acc. to Sanders. So far, we indicate surgical treatment with minimally invasive access and C-Nail osteosynthesis only for Sanders type II fractures, but we know that other authors also indicate types III and IV here.^{3,4}

Contraindications are age above 70 years, uncooperative individuals (alcoholics, drug addicts), heavy smokers, patients with peripheral vascular bed diseases.-

The group of patients undergoing surgery was evaluated using the Clinical Rating System AOFAS (American Orthopaedic Foot and Ankle Society), and the Ankle-Hindfoot Scale⁴ for the heel region. The system evaluates foot function assigning 50 points, 40 points for pain, and 10 points for axial foot position. The result is considered excellent for 90 - 100 points, good for 80 - 89 points, acceptable for 70 - 79 points, and poor for lower than 69 points. The AOFAS functional evaluation score was recorded every six months and one year for both LCP osteosynthesis and C-Nail technique.

Our evaluation in the samples also included the influence of posterior articular area incongruence on the overall results, the impact of Böhler's angle and last but not least also the influence of patient age. All this was compared with the Sanders system used to classify the fractures. Articular area incongruence and disturbance of Böhler's angle were, without greater differences, in degrees II and III of the Sanders classification, so we presumed to evaluate the groups jointly for the ORIF and the minimally invasive methods. We finally evaluated the occurrence of infectious complications and surgical wound healing.

Surgery

The surgical procedure was performed after the restoration of "skin wrinkle", i.e., after reduction of the calcaneal oedema. (Figures 1-6) Patients were operated on in the lateral decubitus position with a tourniquet. Patients after surgery were mobilized in crutches as

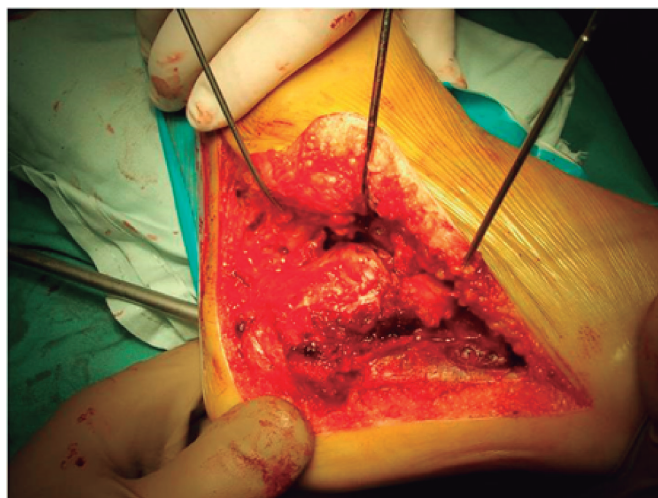


Figure 1. Extended lateral approach – LCP.

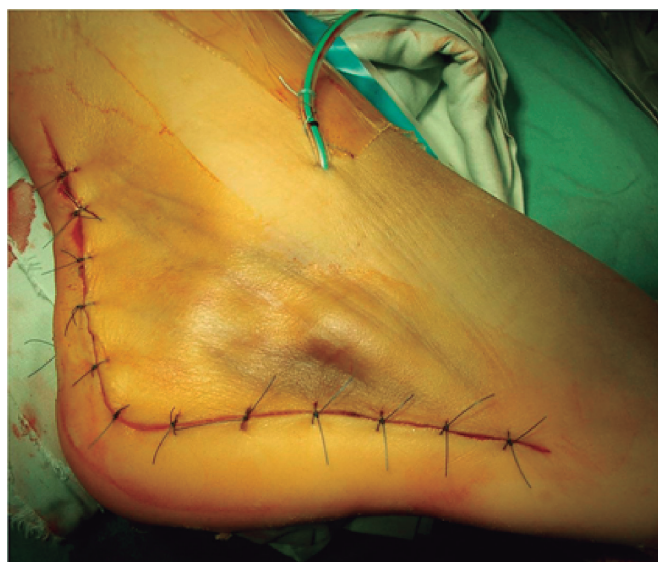

Figure 2. Extended lateral approach – postoperatively.

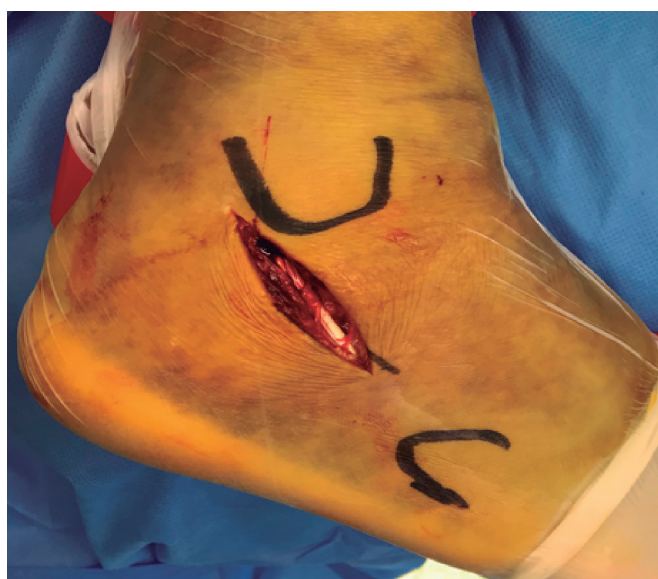


Figure 3. Miniinvasive approach.

Table 1. Distribution of fractures by Sanders classification.

Sanders	LCP 217	%	C-Nail 19	%	Fisher 2x2
I	29	13,4	4	21	0,486554
IIA	67	30,9	9	47,5	0,198468
IIB	33	15,2	4	21	0,510894
IIC	14	6,4	2	10,5	0,625011
III AB	31	14,3	0	0	0,146217
III AC	22	10,1	0	0	0,229755
III BC	13	6	0	0	0,401485
IV	8	3,7	0	0	1

soon as possible after the procedure. Passive physiotherapy in the ankle joint was initiated in most cases on day 1 after surgery. All patients underwent follow-up X-ray or CT investigation, no later than within five days after surgery. Patients were allowed to walk with a light load starting in week 6 and with full load three months after surgery. The patients came for regular follow-ups after 6 weeks, in months 3, 6 and 12 after surgery, and then on an annual basis.

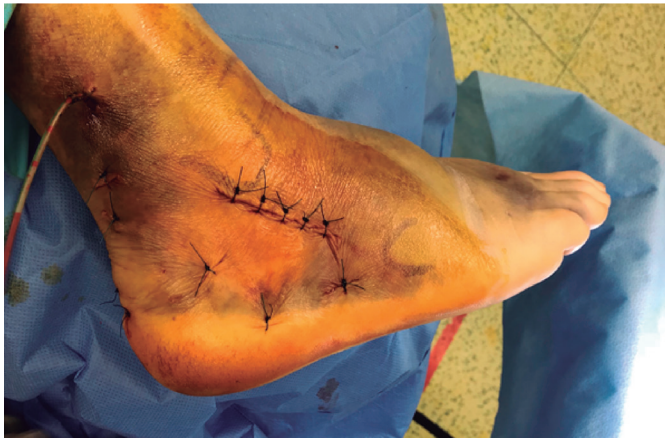

Figure 4. Miniinvasive approach – postoperatively.

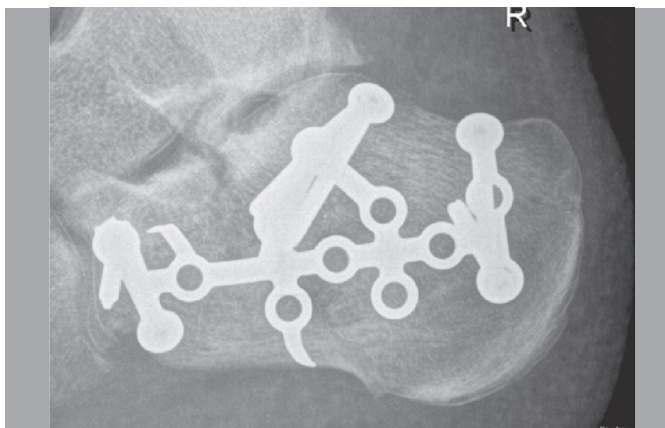

Figure 5. Lateral X-ray postoperatively LCP.

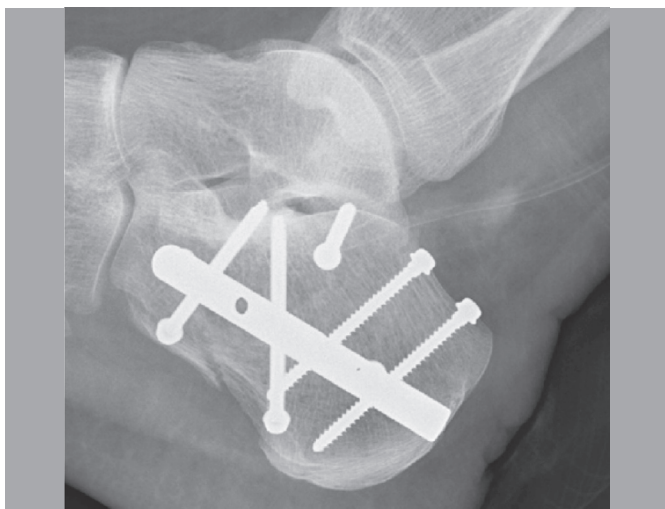


Figure 6. Lateral X-ray postoperatively C – nail.

Statistics

For statistical analyses we used Pearson's chi-squared test and Fisher's exact test.

Ethics

Each patient provided a detailed informed consent. The patients and their families were informed that data from the case would be submitted for publication, and gave their consent.

RESULTS

The surgery was performed after a mean interval of 11 days from injury in the ORIF group (3-26 days), and after 9 days (3-16) in the minimally invasive approach group. Mean duration of hospital stay was 18.2 days (6-38) in the LCP implant group and 14.3 days (7-21) in the group with C-Nail. The AOFAS functional evaluation score outcomes are described in Figure 7 and Table 2.

Mean values of the restoration of Böhler's angle was from post-injury 6.8° to 32.3° in the LCP group and from 7.1° to 33.3° in the C-Nail group. (Tables 3, 4) Only a minimal decrease of Böhler's angle to 29.2° was recorded after one year in both the LCP and nail groups. Values of articular area incongruence and the influence to the functional result are described in Figures 8, 9. Improvement of Böhler's angle on the functional result is seen in Figures 10, 11. Complication in skin healing and infection is described in Table 5.

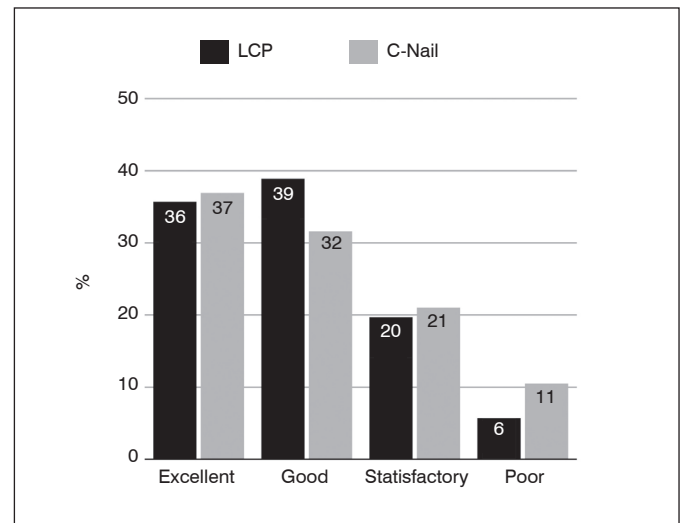


Figure 7. Results according to AOFAS.

Table 2. Results according to AOFAS.

Results	LCP		C-Nail	
	Number of patients	%	Number of patients	%
Excellent	69	35,7	7	36,9
Good	75	38,9	6	31,6
Satisfactory	38	19,7	4	21,0
Poor	11	5,7	2	10,5

Table 3. Preoperative Böhler's angle in individual groups.

	B angle < 15°		B angle 15-30°		B angle > 30°		p ² 3x2
	Number	%	Number	%	Number	%	
LCP	15	7,8	97	50,3	81	42,0	0,7978
C-Nail	1	5,3	11	57,9	7	36,9	
p Fisher 2x2	1,0000		0,6329		0,8086		Fisher 3x2 0,8669

Table 4. Postoperative Böhler's angle in individual groups.

	B angle < 10°		B angle 10-15°		B angle > 15°		p ² 3x2
	Number	%	Number	%	Number	%	
LCP	96	49,7	64	33,2	33	17,1	0,2142
C-Nail	6	31,6	10	52,6	3	15,8	
p Fisher 2x2	0,1536		0,1281		1,0000		Fisher 3x2 0,2307

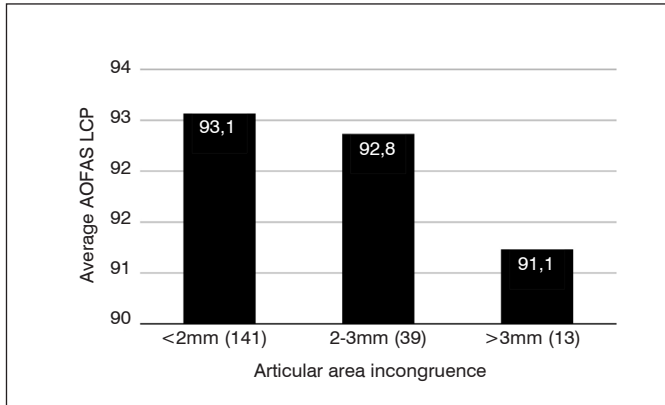


Figure 8. Influence of articular area incongruence on the functional result in fractures treated with LCP.

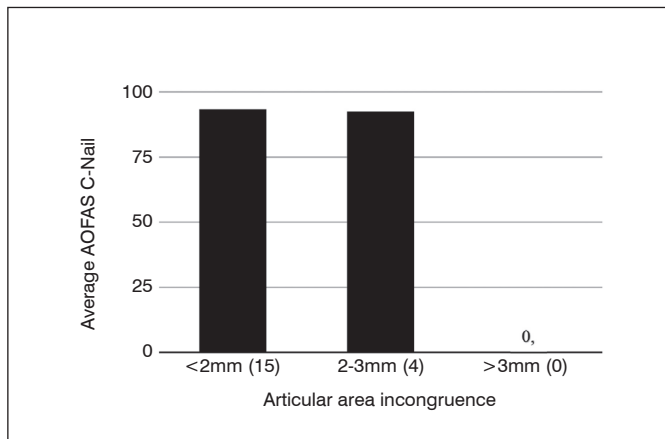


Figure 9. Influence of articular area incongruence on the functional result in fractures treated with C-Nail.

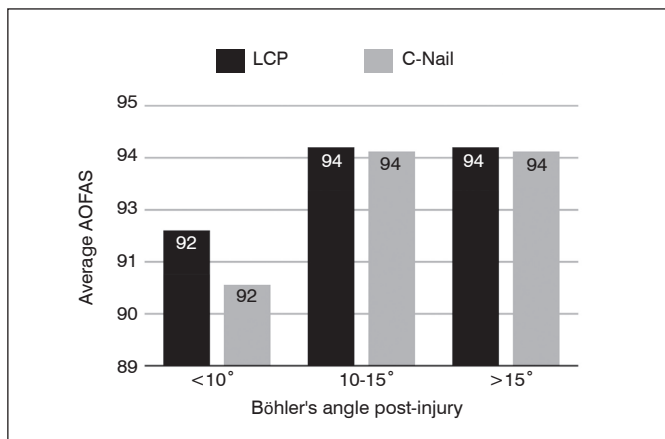


Figure 10. Influence of preoperative Böhler's angle on the functional result.

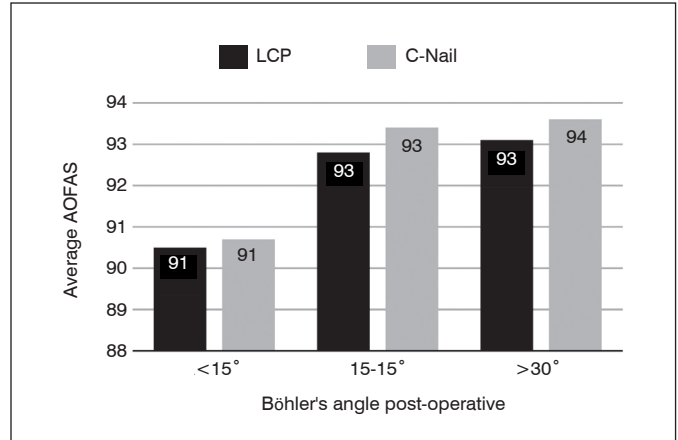


Figure 11. Influence of postoperative Böhler's angle on the functional result.

Table 5. Percentage rates of infectious complications.

	marginal skin necrosis		deep wound infection		p Fisher 2x2	p Fisher 2x2
	Number	%	Number	%		
LCP	13	6,1	4	1,9	1,0000	1,0000
C-Nail	1	5,2	0	0		

22 patients (9.3%) had to undergo arthrodesis as a result of pain in the subtalar joint and development of post-traumatic arthritis in the same joint. So far we have not recorded any development of post-traumatic arthritis in the group treated with C-Nail. It was also not necessary to remove the nail. These are, however, only short-term results and post-traumatic arthritis of the subtalar joint may still be expected.

A statistically significant difference was recorded only for the comparison of treatment results acc. to the AOFAS evaluation and the occurrence of marginal necrosis. In terms of complications or treatment results, the fractures treated with the C-Nail method statistically did not differ markedly from the group treated with the LCP method. The result could be due to the differing numbers of patient in the samples.

DISCUSSION

We approach fracture treatment either conservatively, with closed or combined reductions and K-wire transfixation^{5,6} using various types of minimally invasive,⁷ frequently arthroscopically-assisted⁸ procedures, open procedures and internal fixation.^{9,10} Our department uses the Sanders classification based on CT as indication schema.¹¹ Similar to other authors we indicate ORIF for fractures of Sanders types II, III, and exceptionally IV.^{2,12,13} As an implant we use the LCP plate as part of the extended lateral approach. Sanders type I is treated conservatively. For fractures of type IV acc. to Sanders and for some patients who are contraindicated for ORIF with calcaneal LCP we prefer the method of combined reduction and internal stabilization with K-wires.⁶ Since 2014 we have indicated type II Sanders fractures for minimally invasive osteosynthesis as well. In conformity with the literature we use the "sinus tarsi approach" and use the C-Nail implant for osteosynthesis.^{3,4} As a rule we rely on CT scans conducted in the sagittal, coronal and transverse sections. CT 3D reconstructions are not absolutely necessary. We agree with the authors,¹¹ that native X-rays in the lateral and axial views are not sufficient for comminuted intra-articular fractures where depression of Böhler's angle is found.

Related to the risk of early complications and compartment syndrome, consistent preoperative evaluation of soft tissue condition, correct timing of surgery and thorough assessment of other indication criteria are necessary.^{14,15} In recent years, our indications for surgical solution also include patients deemed in the past to be very risky. This is the age group above sixty years, smokers, patients with diabetes and sometimes even patients with signs of beginning peripheral arterial disease. For these patients we now use the minimally invasive sinus tarsi approach with nail osteosynthesis. This is due to both the literary results published by other authors and to our own accumulating experience from minimally invasive procedures in general.^{3,4,6} So far, indication for C-Nail osteosynthesis includes only patients with type II Sanders fractures.

Zwipp presents one of the largest patient cohort with calcaneal fractures and includes a detailed description of healing complications as well.² The cohort includes 496 patients with 553 fractures of whom 90% were treated conservatively and 95% of these were treated from the lateral approach, 1.5% with the bilateral approach and only 1% with the medial approach. Percutaneous mini-osteosynthesis was used in 2.2% of cases and 0.3% of patients underwent primary fusion. Perioperatively he uses open arthroscopy to check articular area reduction. The use of LCP has resulted in a significant decrease in the use of bone grafting from 53% to 3.8%. Marginal necrosis occurred in 6.7% of the 453 fractures treated with ORIF, haematoma was observed in 4.7%, soft tissue infection in 4.3%, and bone infection in 2.2%. The authors did not have to conduct any amputations, but recorded compartment syndrome in 5.5% cases. They had excellent and good results in 72% of patients. This is comparable to our results with the LCP method reported above. In 2016, however, Zwipp et al. published a group of 106 patients with C-Nail implant osteosynthesis where the proportion of infectious complications was only 1.9%, with the other results being comparable.³ In 2015 Pompach published a similar group where superficial skin necroses are reported in 1.9% and deep infection in 0.9% in C-Nail implant osteosynthesis,³ similar to our group of patients. Goldzak does not report greater differences between intramedullary nail and angular stable plate stabilities in the biomechanical model.⁷ Zwipp uses the medial approach in simple extra-articular fractures or in combination with the extended lateral approach in markedly displaced fractures. This approach consists in surgical incision on the medial side of the calcaneus halfway between the medial malleolus and medial edge of the foot. Burdeaux used this approach with very good results in 51 patients with 60 displaced fractures treated from the medial approach.¹⁶

Štehlík and Štulík obtain excellent results in the treatment of displaced calcaneal fractures using their own combined method, consisting in direct or indirect reduction and K-wire stabilisation.⁶ We ourselves use this method only in very high risk patients and for Sanders IV. A frequently discussed topic is the filling of calcaneus body defects. Brodt et al. report statistically higher calcaneal stability after osteosynthesis with augmentation, but do not use an angular stable plate.¹³ There is no difference even in the complication rate in their patients when osteosynthesis with filling is used. At the same time, they do not report any advantages when tricalcium phosphate is used, and do not recommend full loading before 3 months after osteosynthesis. In his work Longino compares the results of calcaneal osteosynthesis with spongioplasty using a pelvic graft and without spongioplasty, without any pronounced differences in the final results in his sample.¹⁰ Elsner evaluates the results of 18 patients in whom he used augmentation with calcium phosphate cement as part of osteosynthesis.¹⁷ Over a three-year interval no increased percentage of complications occurred. Schildhauer evaluates early calcaneus loading with tricalcium phosphate cement augmentation. After three weeks of full loading he found no reduction loss.¹⁸

In our group of patients we have not recorded differences in results of patient on whom we either performed or did not perform defect augmentation in the neutral triangle region. There was no increase in the percentage of complications in patients with defect filling in the calcaneus. Coincidentally with that there was no extension of bone healing or the need to delay full limb load in patients where the defect was left unaugmented. Neither did we record any more pronounced reduction loss, i.e., reduced calcaneal height, or shortening or redisplacement in the posterior articular heel area. This is certainly the result of the strict use of an angular stable implant (plate, nail) the rigidity of which ensures sufficient osteosynthesis stability and enables the use of relatively early loading without the need for defect augmentation.

Another slightly controversial point is indication of primary talocalcaneal arthrodesis when treating comminuted intra-articular calcaneal fractures of Sanders type IV. Clare and Sanders defend primary subtalar arthrodesis in these cases.⁹ It is true, however, that one alternative is to perform standard ORIF from the extended lateral approach using an angular stable plate and postponing subtalar arthrodesis to second-stage surgery when the patient develops post-traumatic arthritis of the talocalcaneal joint and suffers progression of pain.¹⁹

We do not use arthroscopically-assisted minimally invasive procedures for calcaneal fractures. It is our view that arthroscopy is useful in controlling reduction and posterior articular heel area compression after osteosynthesis, as described by Zwipp and Rammelt.² Neither do we use the method of indirect reduction with Kirschner wire transfixation acc. to Stehlík and Štulík.⁶ The reason is the necessity to exactly reduce the fragments in articular area regions, above all in the posterior articular heel area when its part becomes rotated and impacted into the neutral triangle region. Closed reduction is almost impossible in this case.

It has been found that the severity of damage to the posterior articular area as expressed in the Sanders classification is proportional to the AOFAS functional scoring system where there is a proportional decrease in the AOFAS result as related to fracture severity. This is connected with the AOFAS score being lower in larger postoperative posterior calcaneal articular area incongruence, that is, the lower the quality of the reduction, the worse the functional result. AOFAS tends to be lower with lower Böhler's angle values after injury. The same holds in postoperative follow-up when it can be seen that the value of AOFAS improves after reduction and restoration of Böhler's angle. Again, the more Böhler's angle comes to its values prior to injury, the better the result.²⁰

CONCLUSION

Calcaneal fractures continue to be some of the most complicated problems of post-traumatic surgery and an ideal treatment method is yet to be found. We succeeded in demonstrating in our sample that the rate of successful treatment (as evaluated with the AOFAS scale) declines with increasing fracture severity acc. to the Sanders classification, with both preoperative and postoperative Böhler's angle values, age, and less than perfect reduction of the posterior articular area of the calcaneus.

The results of the recently introduced method of minimally invasive C-Nail osteosynthesis are identical to those obtained with the ORIF LCP method; on the other hand, its use is associated with lower occurrence rates of superficial skin necroses and deep infections. Obtaining a significant difference will require a larger patient sample, but already now it is possible to state that the new method with C-Nail can be successfully used as the method of first choice in Sanders type II and III fractures.

AUTHORS' CONTRIBUTIONS: Each author contributed individually and significantly to the development of this article.

JZ (0000-0002-6944-860X)* contributed to the concept and design of the article, performed the surgeries, drafted the text, analyzed the data and wrote the article; PZ (0000-0002-8557-8236)* drafted the text, analyzed the data; TM (0000-0000-0000-0000)*, performed the surgeries, analyzed the data; JB (0000-0000-0000-0000)* performed the surgeries, analyzed the data; JM (0000-0003-4698-7640)* participated in drafting and reviewed the text, contributed to the intellectual concept of the study, head of the study. *ORCID (Open Researcher and Contributor ID).

REFERENCES

1. Svatoš F, Bartoška R, Skála-Rosenbaum J, Douša P, Pacovský V, Krbec M. Zlomeniny patní kosti léčené dlahovou osteosyntézou-prospektivní studie. Část I: Základní analýza souboru pacientů. *Acta chir Orthop Traum čech.* 2011;78:126-30.
2. Zwipp H, Rammelt S, Barthel S. Calcaneal Fractures- Open Reduction and Internal Fixation (ORIF). *Injury Int J Care Injured.* 2004;35(Suppl 2):46-54.
3. Pompach M, Carda L, Žilka L, Amlang M, Zwipp H. H ebování patní kosti C-Nail. *Úraz Chir.* 2015;23(2):31-8.
4. Simon P, Goldzak M, Eschler A, Mittlemeier T. Reduction and internal fixation of displaced intra-articular calcaneal fractures with a locking nail: a prospective study of sixty nine cases. *In Orthop.* 2015;39(10):2061-7.
5. Fernandez DJ, Koella CH. Combined Percutaneous and Minimal Internal Fixation for Displaced Articular Fractures of the Calcaneus. *Clin Orthop.* 1993;(290):108-16.
6. Stehlík J, Štulík J. Kombinovaná metoda léčení zlomenin patní kosti. *Acta Chir orthop Traum čech.* 2002;69:209-18.
7. Goldzak M, Simon P, Mittlemeier T, Chaussemier M, Chiergatti R. Primary stability of an intramedullary calcaneal nail and an angular stable calcaneal plate in a biomechanical testing model of intraarticular calcaneal fracture. *Injury.* 2014;45(Suppl 1):S49-53.
8. Rammelt S, Gavlik JM, Barthel S, Zwipp H. The value of subtalar arthroscopy in the management of intra-articular calcaneus fractures. *Foot ankle Int.* 2002;23(10):906-16.
9. Clare MP, Sanders RW. Open Reduction and Internal Fixation With Primary Subtalar Arthrodesis for Sanders Type IV Calcaneus Fractures. *Techn Foot Ankle Surg.* 2004;10:963-73.
10. Longino D, Buckley R. Bone graft in the operative treatment of displaced intra-articular calcaneal fractures: is it helpful? *J Orthop Traum.* 2001;15(4):280-6.
11. Sanders R, Fortin P, DiPasquale A. Operative Treatment in 120 Displaced Intra-Articular Calcaneal Fractures. Results Using a Prognostic Computed Tomography Scan Classification. *Clin Orthop Relat Res.* 1993;(290):87-95.
12. Bernischke SK, Sangrozan BJ. Extensive Intraarticular Fractures of the Foot. Surgical Management of Calcaneal Fractures of the Foot. *Clin Orthop.* 1993;(292):128-34.
13. Brodt S, Gise A, Schwieger K, Suhm N, Appelt A. Festkörperaugmentation bei Kalkaneustrümmerfrakturen. *Unfallchirurg.* 2007;110(12):1013-20.
14. Al-Mudhafaffar M, Mofidi A. Wound Complications Following Operative Fixation of Calcaneal Fractures. *Injury.* 2000;31(6):461-4.
15. Myerson M, Manoli A. Compartment Syndrome of the Foot After Calcaneal Fractures. *Clin Orthop Rel Res.* 1993;(290):142-50.
16. Burdeaux BD Jr. The Medial Approach for Calcaneal Fractures. *Clin Orthop Rel Res.* 1993;(290):96-107.
17. Elsner A, Jubel A, Prokop A, Koebeke J, Rehm KE, Andermah J. Augmentation of intraarticular calcaneal fractures with injectable phosphate cement: densitometry, histology, and functional outcome of 18 patients. *J Foot Ankle Surg.* 2005;44(5):390-5.
18. Schildhauer TA, Baer TW, Josten C, Muhr G. Open reduction and augmentation of internal fixation with an injectable skeletal cement for the treatment of complex calcaneal fractures. *J Orthop Traum.* 2000;14(5):309-17.
19. Myerson M, Quill GE. Late Complications of Fractures of the Calcaneus. *J Bone Joint Surg.* 1993;75(3):331-41.
20. Böhler L. Diagnosis, Pathology and Treatment of Fractures of the Calcis. *J Bone Joint Surg.* 1931;13(1):75-89.