

# Pain as symptom of threaded acetabular cup loosening

CELSO HERMÍNIO FERRAZ PICADO<sup>1</sup>, FLÁVIO LUIS GARCIA<sup>2</sup>, CYRO KANABUSHI<sup>3</sup>, SÍLVIO CESAR CARVALHO<sup>4</sup>

## SUMMARY

37 cementless CO-10 total hip replacements were clinically and radiographically evaluated, with a minimum follow-up of 60 months. 23 cups were found to be fixed and 14 presented signs of loosening. Nine patients (26%) with an obviously fixed cup presented some degree of pain, a symptom also referred by ten patients (36%) with signs of cup loosening, but in this latter group pain varied from mild (5/10) to moderate (3/10) and severe (2/10).

Interestingly, four patients with a loose cup had no pain at all. The authors concluded that pain is not a symptom present in the majority of the patients with a loose threaded CO-10 cup and that a significant number of patients with fixed cups can present pain.

**Keywords:** Arthroplasty, Replacement, Hip; Prosthesis Failure; Pain.

## INTRODUCTION

The loosening of acetabular component has been classically described as a more frequent complication than the loosening of femoral component, specially in cemented prostheses<sup>(7)</sup>. Such description induced the popularization of the usage of non-cemented acetabular components of different designs and materials; at the same time, it became more difficult to distinguish patients with loosened components from those with pain induced by other causes<sup>(2)</sup>.

Results obtained with threaded non-cemented acetabular components was disappointing in many series<sup>(4,10,13,15)</sup>. In Brazil, the primary total non-cemented hip prosthesis of the CO-10 type (Baumer<sup>®</sup>), which presents an acetabular component of this type, was widely employed during the last decade and their long- and middle-term results are not yet known. In a clinical and radiographic survey of this type of prosthesis carried out at our department, we observed a high rate of acetabular loosening through comparison of serial radiographic images. The present study aims to evaluate and compare the presence and characteristics of pain in patients presenting a fixed acetabular component with those found in patients with radiographically loose acetabular component.

## MATERIALS AND METHODS

Between November 1989 and December 1995 our service performed 65 total primary non-cemented hip replacements of the CO-10 type (Baumer<sup>®</sup>).

We completed the clinic and radiographic protocol for 37 arthroplasties with 5- to 10-year follow-up. Arthroplasty patients

were excluded in the following cases: postoperative infection, no follow-up, incomplete radiological file, and presence of radiographic signs of femoral loosening. The average age of patients was 49.3 years with an average follow-up of 94.43 months.

The radiographic evaluation of the acetabular component measured the acetabulum slope and position, these measurements being related to the teardrop. All radiographic measurements were made on a immediate postoperative radiography and on another one with at least 5 years of follow-up; the values obtained were compared for each patient. Correction for the magnification of the radiographies was required. A loose component was defined as that for which measurements, together with observations of the induced bone reaction, indicated component migration<sup>(4,8,11)</sup> with acetabular component displacement higher than 10% of the value found in the initial radiography.

Pain was clinically evaluated according to the system suggested by Johnston and others<sup>(11)</sup>, pain being graded as:

- Absent: no pain
- Mild: light and occasional pain not affecting activities or work
- Moderate: pain that made the patient change habits or give up some activities; the patient, however, is still active.
- Severe: strong pain causing important limitation

Besides gradation, the pain occurrence was checked as:

- No pain
- Pain at first steps that soon disappears
- Pain starting after more than 30 minutes of walking
- Pain during the whole walk
- Pain all the time

Study performed at the Department of Biomechanics, Medicine, and Rehabilitation of the Locomotor System of the Clinic Hospital of the Medicine School of Ribeirão Preto, São Paulo University - USP

1. PHD Professor
2. Assistant Doctor
3. Special Training Doctor
4. Member of the SBOT.

**Mail Address:**  
Av. Bandeirantes, 3.900, University Campus of USP –  
ZIP Code 14048-900  
Ribeirão Preto – SP – Brasil  
E-mail: cfpicado@fmrp.usp.br

Received on February 04, 2003 and approved on December 15, 2004

## RESULTS

Out of the 37 cases evaluated, 23 replacements were fixed and 14 showed signs of acetabular loosening. (Table and Graph 1).

Among the patients presenting the fixed acetabular component, absence of pain was found in 14 patients, mild and moderate pain was found in 6 and 3 patients, respectively, and no patient had severe pain.

As to the occurrence of pain in these patients, 14 had no pain, 3 had pain at the first steps while walking, 3 after more than 30 minutes of walking while no patient had pain during the whole walk and 3 had pain all the time (Table and Graph 2).

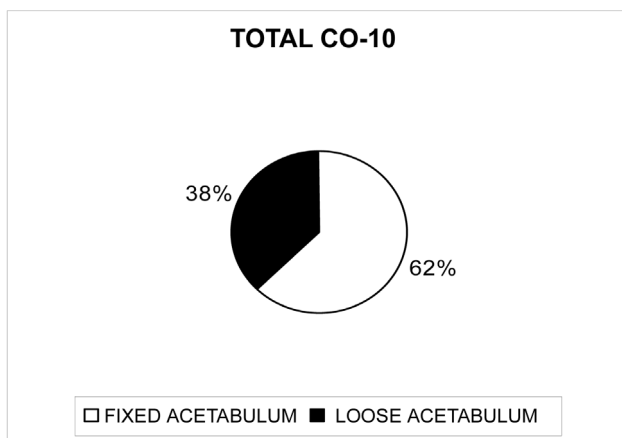
Among the patients presenting radiologically loose acetabular component, 4 had no pain while 4, 5 and 3 patients had mild, moderate and severe pain, respectively.

Among the patients who presented a loose acetabular component in the radiographic examination, 4 had no pain in the concerned hip, 4 had pain at the first steps, no patient developed pain after walking more than 30 minutes, 3 had pain during the whole walk, and 3 had pain all the time (Table and Graph 3).

Tables and Graphs 4 and 5 show the comparison of pain intensity and occurrence between the two groups.

FIXED ACETABULUM	23
LOOSE ACETABULUM	14
TOTAL	37

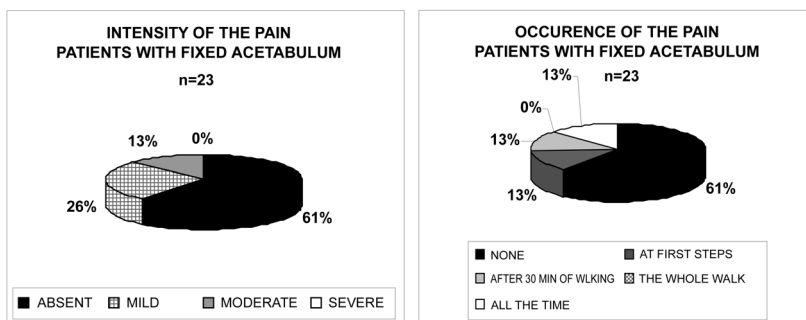
Table 1 - Total #of prostheses CO-10



Graph 1-Results in percentage of total number of CO-10 acetabula

PAIN INSTENSITY	NONE	FIRST STEPS	PAIN OCCURS AFTER 30 MINUTES OF WALKING	ALL THE WALK	ALL THE TIME
ABSENT	14	0	0	0	0
MILD	6	3	1	0	2
MODERATE	3	0	2	0	1
SEVERE	0	0	0	0	0
TOTAL	23	3	3	0	3

Table 2 - Fixed Acetabulum



INTENSITY OF PAIN	NONE	FIRST STEPS	PAIN OCCURS AFTER 30 MINUTES WALK	ALL THE WALK	ALL THE TIME
ABSENT	4	0	0	0	0
MILD	5	4	0	0	1
MODERATE	3	0	0	2	1
SEVERE	2	0	0	1	1
TOTAL	14	4	0	3	3

Table 3 - Loose Acetabulum

## DISCUSSION

It is assumed that clinically the loose acetabular component causes localized pain in the inguinal area or thigh when walking with load, being worse at the first steps<sup>(7)</sup>, or pain in the area of the gluteus<sup>(2)</sup>.

Several authors have reported high rates of loose acetabular components of the threaded non-cemented type<sup>(4,10,13,15)</sup>, a finding confirmed in our study (38%), while others have shown good results<sup>(3,6,9)</sup>.

Pain is also evaluated through different scores for the study of results following hip replacement procedures<sup>(8,13)</sup> and is generally shown in a general context. Some studies report rates of 86% in patients with no pain following non-cemented hip replacement<sup>(5)</sup>, while others show rates of 36% and 60% in patients with pain following this procedure<sup>(1,12)</sup>.

In 1991, Puppuro and Engh<sup>(14)</sup> published a study where they verified loosening of 16 units (28.75%) out of a total of 56 threaded acetabula after two to four years of follow-up. Of the 16, 11 patients (68.75%) had pain and 5 patients (31.25%) had no pain.

Our survey showed a high number of patients with radiologically loose acetabular component.

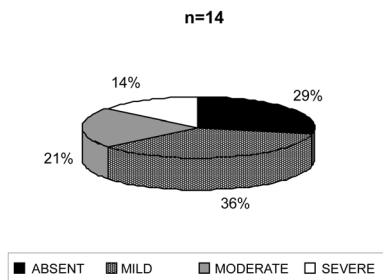
The comparison of the characteristics of grade and occurrence of pain among the patients with the loose acetabular component showed that we cannot trust the pain symptom as an indication of loose acetabular component of the threaded prosthesis of the CO-10 type.

Pain was absent or discrete in 65% of the patients with loose acetabulum. As it would be expected, this percentage was higher for the patients with fixed acetabulum.

If the degree of pain was considered in the diagnostics of these patients, 65% would have been diagnosed as not having a loose acetabulum, since they did not feel pain or had it light and occasional without changing their activities. We should also take into consideration that 35% of the patients with loose acetabulum complained of severe pain, but 13% of the patients with fixed acetabulum also had this type of complaint.

The analysis of pain occurrence showed that 58% of the patients with loose acetabulum had no pain or had it only during the first steps and therefore, this symptom cannot be considered characteristic of the loosening. Although 42% of this group

**INTENSITY OF THE PAIN PATIENTS WITH LOOSE ACETABULUM**

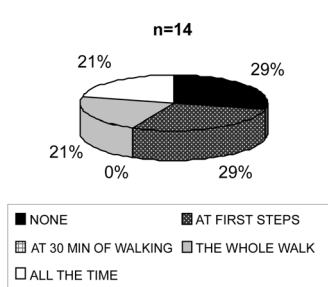


**Graph 3 - Results, in percentage, of the loose acetabulum**

	FIXED	LOOSE
ABSENT	61%	29%
MILD	26%	36%
MODERATE	13%	21%
SEVERE	0%	14%
TOTAL	100%	100%

**Table 4 - Intensity of the pain - Comparison between fixed and loose acetabulum**

**OCCURENCE OF THE PAIN PATIENTS WITH LOOSE ACETABULUM**



**Table 5 - Occurrence of the pain - Comparison between fixed and loose acetabulum**

	FIXED	LOOSE
NONE	61%	29%
FIRST STEPS	13%	29%
AFTER 30 MIN. OF WALKING	13%	0%
ALL THE WALK	0%	21%
ALL THE TIME	13%	21%
TOTAL	100%	100%

practically no pain; however, our results show that this should be the preferred choice.

## CONCLUSION

On the face of the data presented, the authors conclude that, in the total hip non-cemented arthroplasty of the CO-10 type, the pain, alone, is not a symptom of a loose acetabular component and its presence also should not be considered a constant and essential element for this diagnostics.

the pain occurred during the whole walk or all the time, 13% in the group of patients of fixed acetabulum had the same complaint.

The acetabulum loosening is accompanied by loss of the acetabular osseous case, and the larger the loss the more difficult becomes the surgical revision. Every time, it becomes more important the decision of the orthopedist to do a precocious revision of the loose acetabula to avoid an increased osseous destruction. This decision is of greater responsibility when a major surgery is indicated for a patient who has

## REFERENCES

1. Apal DM, Smith DG, Schwartz CM, Paprosky WG. Threaded cup acetabuloplasty. Early clinical experience. Clin Orthop 241:183-189, 1989.
2. Berry JD. Evaluation of the painful total hip arthroplasty. In: Morrey BF. Joint replacement arthroplasty. 3<sup>rd</sup> ed. Philadelphia: Churchill Livingstone, 2003. p.811-823.
3. Delaunay CP, Kapandji A. Survivorship of rough-surfaced threaded acetabular cups. 382 consecutive primary Zweymüller cups followed for 0.2-12 years. Acta Orthop Scand 69:379-383, 1998.
4. Engh CA, Griffin WL, Marx CL. Cementless acetabular components. J Bone Joint Surg Br 83:1598-1610, 2001.
5. Garcia-Cimbrello E, Pardos AC, Madero R, Andreu MO. Total hip arthroplasty with use of the cementless Zweymüller alloclassic system. A ten to thirteen-year follow-up study. J Bone Joint Surg Am 85:296-303, 2003.
6. Gröbl A, Chiari C, Gruber M, Kaider A, Wolf FG. Cementless total hip arthroplasty with a tapered rectangular titanium stem and threaded cup. A minimum ten-year follow-up. J Bone Joint Surg Am 84:425-431, 2002.
7. Harkess JW. Arthroplasty of hip. In: Canale ST. Campbell's Operative Orthopaedics. 10<sup>th</sup> ed. Philadelphia: Mosby, 2003. p.315-482.
8. Harris WH. Traumatic arthritis of the hip after dislocation and acetabular fractures: treatment by mold arthroplasty. J Bone Joint Surg Am 51:737-755, 1969.
9. Hartley WT, McAuley JR, Culpepper WJ, Engh Jr CA. Osteonecrosis of the femoral head treated with cementless acetabular components. J Bone Joint Surg Am 82:1408-1413, 2000.
10. Havelin LI, Vollset SE, Engesaeter LB. Revision for aseptic loosening of uncemented cups in 4.352 primary total hip prostheses. A report from the Norwegian Arthroplasty Register. Acta Orthop Scand 66:494-500, 1995.
11. Johnston RC, Fitzgerald RB, Harris WH, Poss R, Muller ME, Sledge CB. Clinical and radiographic evaluation of total hip replacement. A standard system of terminology for reporting results. J Bone Joint Surg Am 72:161-168, 1990.
12. Kawamura H, Dunbar MJ, Murray P, Bourne RB, Rorabeck CH. The porous coated anatomic total hip replacement. J Bone Joint Surg Am 83:1333-1338, 2001.
13. Merle d'Aubigné R, Postel M. Functional results of hip arthroplasty with acrylic prosthesis. J Bone Joint Surg Am 31:451-475, 1954.
14. Puppato F, Engh CA. Comparison of porous-threaded and smooth-threaded acetabular components of identical design. Two- to four- year results. Clin Orthop 271:201-205, 1991.
15. Sismank HG, Brocai DRC, Reiser D, Thomsen M, Sabo D, Lukoschek M. Middle-term results of threaded acetabular cups. J Bone Joint Surg Br 79:366-370, 1997.