

Interference and characteristics of periorbital edema in pupil examination after craniotomy

Interferência e características do edema periorbital no exame pupilar após craniotomia

Analuiza Candido Torres¹

Maria Laura Iervolino Penteadó Siciliano²

Solange Diccini¹

Keywords

Craniotomy/adverse effects; Edema/etiology; Neurologic examination; Pupil; Nursing assessment

Descritores

Craniotomia/efeitos adversos; Edema/etiologia; Exame neurológico; Pupila; Avaliação em enfermagem

Submitted

October 14, 2014

Accepted

November 3, 2014

Abstract

Objective: To assess the interference and the characteristics of periorbital edema in pupil examination with patients who underwent anterior craniotomy.

Methods: Prospective cohort study conducted postoperatively in an intensive care unit and neurosurgery ward. Interference and characteristics of periorbital edema in pupil examination were assessed between patients' admission and the seventh day of the postoperative period. Pupil examination was performed by nurses.

Results: One hundred patients were examined and the incidence of periorbital edema was 80%. Pupil examination was not performed by a nurse in 24 patients (30%). The characteristics that influenced the performance of pupil examination were purplish coloration and severe periorbital edema.

Conclusion: Periorbital edema was found in most postoperative craniotomy patients and pupil examination was not performed in 30% of them. The presence of severe periorbital edema and purplish coloration were the factors that hampered pupil examination.

Resumo

Objetivo: Avaliar a interferência e características do edema periorbital no exame pupilar, em pacientes submetidos a craniotomia por via anterior.

Métodos: Estudo de coorte prospectivo realizado em pacientes no pós-operatório na unidade de terapia intensiva e internação de neurocirurgia. A interferência e características do edema periorbital no exame pupilar foram avaliados da admissão do paciente até sétimo dia de pós-operatório. O exame pupilar foi realizado por enfermeiros.

Resultados: Foram avaliados 100 pacientes e a incidência de edema periorbital foi de 80%. O enfermeiro não realizou o exame pupilar em 24 (30%) pacientes. As características que influenciaram na realização do exame pupilar foram coloração arroxeada e intenso edema periorbital.

Conclusão: O edema periorbital estava presente na maioria dos pacientes no pós-operatório de craniotomia e o exame pupilar não foi realizado em 30% dos pacientes. A presença de intenso edema periorbital e de coloração arroxeada foram características que prejudicaram o exame pupilar.

Corresponding author

Solange Diccini
Napoleão de Barros street, 754, São Paulo SP, Brazil. Zip Code: 04024-002
solange.diccini@unifesp.br

DOI

<http://dx.doi.org/10.1590/1982-0194201500003>

¹Escola Paulista de Enfermagem, Universidade Federal de São Paulo, São Paulo, SP, Brazil.

²Hospital São Paulo, São Paulo, SP, Brazil.

Conflicts of interest: there are no conflicts of interest to declare.

Introduction

The scalp is a vascularized structure that surrounds the skull and is composed of five layers: skin, subcutaneous tissue, epicranial aponeurosis, loose connective tissue and pericranium. During craniotomy, the pericranium is detached and the veins crossing the loose connective tissue are severed. After suturing the scalp, there is an accumulation of liquid between the galea aponeurosis and the pericranium called subgaleal collection. In anterior craniotomies, subgaleal collection can be large due to the section of draining veins in the frontal region.

With the presence of subgaleal collection, patients can feel pain, have periorbital edema with or without hematoma in one or both eyes, ecchymosis and report difficulty to see.⁽¹⁾ The incidence of subgaleal collection can vary from 7% to 33%, and periorbital edema from 2.8% to 100%.^(2,3)

During the immediate postoperative period of craniotomy, patients can have neurosurgery complications, such as hematomas and cerebral edema as a result of surgical trauma. These situations result in the increase of intracranial pressure with changes in consciousness level, in pupil diameter and pupillary light reflex. Nurses perform a neurological examination in order to detect alterations that may put patients' lives at risk in the craniotomy postoperative period. Despite the importance of pupil examination, this parameter can be impaired in patients with periorbital edema.

The objective of this study was to assess the interference and the characteristics of periorbital edema in pupil examination with patients who underwent anterior craniotomy.

Methods

Prospective cohort study conducted in intensive care unit (ICU) and neurosurgery ward (NW) of Hospital São Paulo, a university hospital of Universidade Federal de São Paulo, in São Paulo, Brazil.

Inclusion criteria were: patients aged 18 or over and who underwent elective anterior craniotomy. Exclusion criteria were: patients with oculomotor

nerve lesion prior to surgery, anisocoria and/or abnormally shaped pupils, eye socket tumor and/or proptosis, previous craniotomy, surgical procedures such as trepanning, stereotactic biopsy and transphenoidal surgery, and patients with subgaleal drainage or with cerebrospinal fluid leakage in postoperative period.

In preoperative, the following variables were collected: gender, age and diagnosis. In intraoperative period, the following variables were collected: type of surgical incision on the scalp, anesthesia time (in hours) and surgery time (in hours). In postoperative period, the following variables were collected: subgaleal collection (presence or absence); periorbital edema (presence or absence); affected eyelid (unilateral or bilateral); color of periorbital edema (absence, clear, rosy, reddish or purplish); severity of periorbital edema (absent, slight, moderate or severe) and pupil examination (performed or not).

The variables of preoperative period were collected at hospital admission. Intraoperative variables were collected from the patient's medical record after ICU admission and postoperative variables were collected in ICU and NW.

The presence of subgaleal collection was assessed once a day, during the application of head bandage, from day 1 to 7 of the postoperative period. The color of periorbital edema was defined as clear, when the content was aqueous; rosy when it was serosanguineous, reddish when the color was red as blood and purplish when it was purple. The severity of the edema was defined as absent, as slight when the eyelid edema did not cover the iris edge, as moderate when it extended past the iris edge and as severe when the periorbital edema kept the eyelid closed.⁽⁴⁾ The presence of periorbital edema, the affected eyelid, the severity and coloration of the eyelid edema were assessed every 12 hours from patient's admission at ICU to the third postoperative day (0, 12, 24, 36, 48, 60, 72 hours) and every 24 hours from the third to the seventh postoperative day (96, 120, 144, 168, 192 hours). Pupil examination was considered as performed when the nurse managed to open the patient's eyelid, with or without periorbital edema, and when it was possible to assess the pupil diameter and

light reflex Pupil examination was considered as not performed when the nurse was able to open the patient's eyelid partially but was not possible to assess the pupil diameter and light reflex, or was not able to open the patient's eyelid.

Sample size calculation was based on a pilot sample composed by 39 patients, in which the incidence of periorbital edema was found in the first 24 hours of the postoperative period of anterior craniotomy. The incidence of periorbital edema during the postoperative period was 79.5%. Considering this figure as the incidence of periorbital edema, a sample of 100 patients would give an estimate that differs from this number in 8% at the most, with a 95% confidence interval. This sample size was sufficient to estimate the incidence of periorbital edema between 71.5% and 87.5%, with a 95% confidence interval.

The statistical analysis was performed using the SPSS® software, version 14.0. Qualitative variables were given in numbers (n) and percentages (%). Quantitative variables were expressed by means of position measures: median and minimum and maximum values. The incidence of periorbital edema was calculated during the 192 postoperative hours and its confidence interval was 95%. Techniques of survival analysis were used by means of Kaplan-Meier estimate in order to assess the probability of a patient not having periorbital edema for a period of time. The chi-square test was used to check the association between pupil examination and demographic clinical data. For cases in which at least one of the values was lower than five, Fischer's exact test was used. Medians were compared by means of Mann-Whitney U test. A value of $p < 0.05$ was considered statistically significant.

The development of this study complied with national and international ethical guidelines for research involving human subjects.

Results

Of the 100 patients who underwent anterior craniotomy, 61% were women, median age of 45.5 years, varying from 18 to 82 years old. As for diag-

nosis, 55% of patients had intracranial tumor, 28% had epilepsy, 14% had intracranial aneurysm and 3% had arteriovenous malformation.

In intraoperative period, the type of surgical incision performed on the scalp was frontotemporal (46%), temporoparietal (11%), frontoparietal (10%), frontotemporoparietal (9%), frontal (8%), temporal (3%), hemicoronal and $\frac{3}{4}$ of hemicoronal (2%) and bicoronal (1%). The median of anesthesia time was 7 hours, varying from 3.5 to 15.2 hours, whereas the median of surgery time was 5.4 hours, varying from 2.2 to 13.8 hours.

During postoperative period, the incidence of periorbital edema in patients who underwent anterior craniotomy was 80%. Periorbital edema peak occurred in the first 12 hours of postoperative period. The intervals of 24 and 36 hours of postoperative period were the moments when the highest number of patients presented periorbital edema. After 48 hours in the postoperative period, no cases of patients with periorbital edema occurred. The median time for periorbital edema recovery was 120 hours.

Figure 1 presents the distribution of patients according to the appearance of periorbital edema in postoperative period of anterior craniotomy.

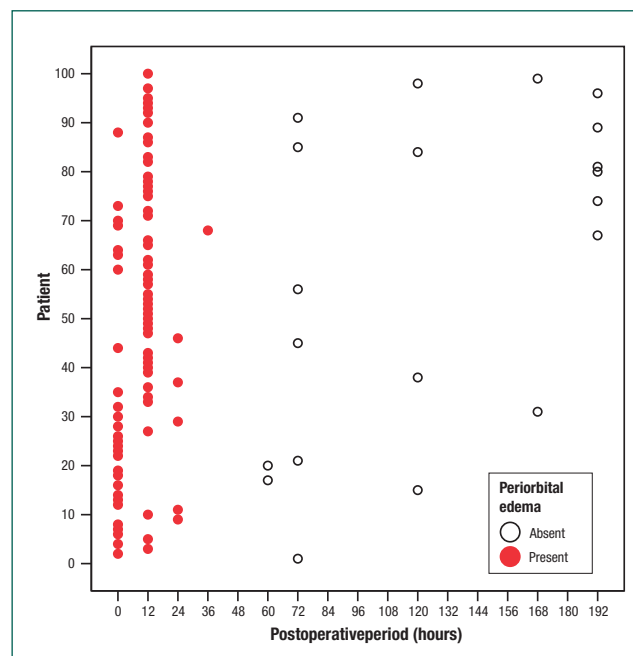


Figure 1. Presence or absence of periorbital edema in postoperative period of anterior craniotomy

Of the 80 patients who had periorbital edema in postoperative period, pupil examination was not performed by a nurse in 24 patients (30%). There was no association between the following variables: age ($p=0.24$), gender ($p=0.39$), diagnosis ($p=0.46$), type of surgical incision ($p=0.99$), surgery time ($p=0.80$) and anesthesia time ($p=0.99$), and the performance or not of pupil examination.

Figure 2 presents the probability of the nurse not performing pupil examination on patients who had periorbital edema in the postoperative period of anterior craniotomy.

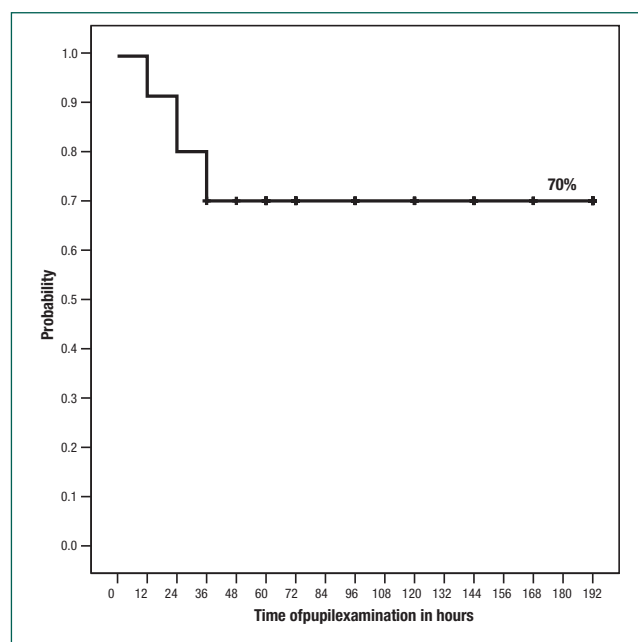


Figure 2. Kaplan-Meier curve in relation to the probability of the nurse not performing pupil examination on patients who had periorbital edema in the postoperative period of anterior craniotomy

At patients’ admission in ICU, the risk of not having pupil examination was estimated in 1.3%; in the first 12 hours of the postoperative period, the risk was 8.7%; in the first 24 hours it was 20%, and in the first 36 hours, 30%. After 60 hours in the postoperative period, it was possible to carry out a pupil examination with all patients, even with those who had periorbital edema.

The clear color of periorbital edema prevailed from admission in ICU (0 time) to 12 hours of postoperative period, affecting 82.2% and 63.5% of patients, respectively. Purplish periorbital edema was

observed at ICU admission and prevailed in 24 and 36 hours’ time range, in 38.9% and 35% of patients, respectively. Severe periorbital edema prevailed in 24, 36 and 48 hours of postoperative period.

Table 1 presents the analysis of variables related to periorbital edema such as subgaleal collection, affected eyelid, color and severity of periorbital edema regarding pupil examination performed or not by a nurse in patients who underwent anterior craniotomy.

Table 1. Variables related to the periorbital edema in which pupil examination was either performed or not in patients in the postoperative period of anterior craniotomy by a nurse

Periorbital edema	Pupil examination		p-value
	Performed n(%)	Not performed n(%)	
Subgaleal collection			0.84
Present	20(35.7)	8(33.3)	
Absent	36(64.3)	16(66.7)	
Affected eyelid			0.57
Unilateral	20(35.7)	7(29.2)	
Bilateral	36(64.3)	17(70.8)	
Color			0.002**
Clear	19(33.9)	-	
Rosy	9(16.1)	6(25.0)	
Reddish	5(8.9)	2(8.3)	
Purplish	23(41.1)	16(66.7)	
Severity			<0.001**
Slight	6(10.7)	-	
Moderate	33(58.9)	-	
Severe	7(30.4)	24(100.0)	

*Chi-square Test; **Fisher’s Exact Test

As for the color of the periorbital edema, a greater number of patients with a purplish color edema was found among those who could not have a pupil examination performed. All patients who had a pupil examination performed had severe periorbital edema.

Discussion

The limitations of this study are related to the absence of a comparison, regarding the pupil examination, between groups of patients with periorbital edema, conscious or with changes in consciousness level. On the other hand, the method allowed outlining an evolution profile and its interference in pupil examination during the postoperative period.

Patients who underwent neurosurgery may have neurological and systemic complications during the postoperative period. The most feared complications after craniotomy are intracranial hematoma formation on the surgical site and cerebral edema as a result of surgical trauma, leading to an increase in intracranial pressure.⁽⁵⁻¹⁰⁾ The performance of a bedside neurological examination is one of the possible evaluations for early detection of intracranial hypertension.

Subgaleal collection is a complication of surgical technique, but it also has its implications on the postoperative period due to the formation of periorbital edema. This in turn can make pupil examination difficult during neurological examination. In the first few hours of craniotomy postoperative period, patients can be under the effects of anesthesia or sedation, so it is not possible to evaluate consciousness or apply the Glasgow Coma Scale.^(11,12) In this situation, pupil examination becomes an important parameter for neurological examination.

Despite neurosurgical technical progress, problems of subgaleal collection and periorbital edema formation persist, which can have serious implications for patients. Subgaleal collection can result in pain, and make scalp adhesion to osteomuscular surface and surgical incision healing difficult. If subgaleal collection is infected, patients can have infection and wound dehiscence, osteomyelitis and meningitis. Neurosurgeons can place a suction drain on the subperiosteum in order to prevent subgaleal collection. On the one hand, this procedure presents a risk of infectious complications and an increase in surgical costs. On the other hand, the eyelid edema harms patients' vision,⁽¹⁾ causes pain, hampers eye hygiene and sometimes results in restlessness.

It was difficult to find studies in literature that assessed the formation of periorbital edema in anterior craniotomies and its interference in pupil examination. Generally, periorbital edema is not considered as a post-surgery complication when it is reduced after three to five days after surgery.⁽²⁾

The variation in the incidence of periorbital edema in anterior craniotomies is high, between 2.8 to 100%.^(2,3) Of the total number of patients assessed,

80% had periorbital edema between admission in ICU and 36 hours after surgery. After 48 hours in the postoperative period, no cases of patients with periorbital edema occurred. These are unprecedented results regarding periorbital edema formation.

Pupil examination was not performed in 30% of patients with periorbital edema. From admission to the first 24 hours after surgery, the probability of not performing pupil examination varied from 1.3% to 20% of patients. A study carried out in the postoperative period of elective craniotomy revealed that 1% of patients remained unconscious in the first 24 hours after surgery.⁽¹²⁾ In clinical practice, the loss of parameters of consciousness assessment and pupil examination at the same time results in difficulties for bedside surgical evaluation of patients during the postoperative period.⁽¹³⁾

Approximately 2% of patients who underwent elective craniotomy can have intracranial hematomas, thus making a new surgical intervention necessary. It is important to highlight that most hematomas appear in less than six hours after surgery, with quick and progressive neurological deterioration.^(7,14-16) At this moment of the postoperative period, patients can be under the residual effect of anesthesia, which hampers the assessment of consciousness. In the presence of a severe periorbital edema, it is not possible to perform pupil examination. The request for a computerized tomography can be postponed due to the lack of neurological changes, which can contribute to these patients' morbidity and mortality.

Preventive measures such as compressive dressing and cryotherapy can reduce the formation of subgaleal collection and periorbital edema, respectively. However, studies relating head dressing, subgaleal collection and periorbital edema were not found. This can be explained by the fact that an excessive compression on the frontal skin or on the scalp can be a risk factor for the development of pressure ulcers.

A clinical study carried out in craniotomy postoperative patients assessed the effects of cryotherapy on operative wound pain, eyelid edema and facial ecchymosis. Ninety-seven patients were examined, of which 48 were submitted to cryotherapy and 49

belonged to the control group. Cryotherapy began three hours after surgery, for 20 minutes, until the third day of the postoperative period. Cryotherapy reduced pain intensity over time, as well as the periorbital edema and facial ecchymosis. However, in this study, no correlation was found between the reduction of the eyelid edema through cryotherapy and pupil examination.

Conclusion

Periorbital edema was found in most postoperative craniotomy patients and pupil examination was not performed in 30% of them. The presence of severe edema periorbital and purplish coloration were the factors that hampered pupil examination.

Collaborations

Torres AC contributed to the project conception, research execution, analysis and interpretation of data, and writing of the article. Siciliano MLIP collaborated with the interpretation of data and writing of the article. Diccini S contributed to the project conception, research execution, analysis and interpretation of data, and writing of the article.

References

1. Shin YS, Lim NYL, Sung-Cheol Y, Park KO. A randomised controlled trial of the effects of cryotherapy on pain, eyelid oedema and facial ecchymosis after craniotomy. *J Clin Nurs*. 2009; 18(21):3029-36.
2. Beseoglu K, Lodes S, Stummer W, Steiger H, Hänggi D. The transorbital keyhole approach: early and long-term outcome analysis of approach-related morbidity and cosmetic results. *J Neurosurg*. 2011; 114(3):852-6.
3. Hafez MM, Bary TH, Ismail AS, Mohammed MA. Frontolateral keyhole craniotomy approach to anterior cranial base. *ZUMJ*. 2013; 19(1):91-9.
4. Kara CO, Gokalan I. Effects of single-dose steroid usage on oedema, ecchymosis, and intraoperative bleeding in rhinoplasty. *Plast Reconstr Surg*. 1999; 104(7):2213-8.
5. Beauregard CL, Friedman WA. Routine use of postoperative ICU care for elective craniotomy: a cost-benefit analysis. *Surg Neurol*. 2003; 60:483-9.
6. Mutlu LK, Woiciechowsky C, Bechmann I. Inflammatory response after neurosurgery. *Best Pract Res Clin Anaesthesiol*. 2004; 18(3):407-24.
7. Chernov MF, Ivanov PI. Urgent reoperation for major regional complications after removal of intracranial tumors: outcome and prognostic factors in 100 consecutive cases. *Neurol Med Chir (Tokyo)*. 2007; 47(6):243-8. discussion 248-9.
8. Bui JQH, Mendis RL, van Gelder JM, Sheridan MMP, Wright KM, Jaeger M. Is postoperative intensive care unit admission a prerequisite for elective craniotomy? *J Neurosurg*. 2011; 115(6):1236-41.
9. Hanak BW, Walcott BP, Nahed BV, Muzikansky A, Mian MK, Kimberly WT, Curry WT. Postoperative intensive care unit requirements after elective craniotomy. *World Neurosurg*. 2014; 81(1):165-72.
10. Hecht N, Spies C, Vajkoczy P. Routine intensive care unit - level care after elective craniotomy: time to rethink. *World Neurosurg*. 2014; 81(1):66-8.
11. Dawes E, Durham L, Lloyd H. Monitoring and recording patients' neurological observations. *Nurs Stand*. 2007; 22(10):40-5.
12. Xu M, Lei YN, Zhou JX. Use of cerebral state index to predict long-term unconsciousness in patients after elective craniotomy with delay recovery. *Neurology*. 2011; 11(15):2-7.
13. Pritchard C, Radcliffe J. General principles of postoperative neurosurgical care. *Anaesth Intensive Care Med*. 2008; 9(6):231-6.
14. Khaldi A, Prabhu VC, Anderson DE, Oigitano TC. The clinical significance and optimal timing of postoperative computed tomography following cranial surgery. *J Neurosurg*. 2010; 113(5):1021-1025.
15. Seifman MA, Lewis PM, Rosenfeld JV, Hwang PYK. Postoperative intracranial haemorrhage: a review. *Neurosurg Rev*. 2011; 34(4):393-407.
16. Adelmann D, Klaus DA, Illievich UM, Krenn CG, Krall C, Kozek-Langenecker S, Schaden E. Fibrinogen but not factor XIII deficiency is associated with bleeding after craniotomy. *Br J Anaesth*. 2014; 113(4):1-6.