



## Histological characterization of oocyte developmental stages of suruvi *Steindachneridion scriptum* kept in captivity

Mariana Roza de Abreu<sup>1\*</sup>, Patrícia Garcia<sup>2</sup> and Evoy Zaniboni-Filho<sup>3</sup>

<sup>1</sup>Departamento de Aquicultura, Universidade Federal de Santa Catarina, Rod. Admar Gonzaga, 1346, 88034-000, Itacorubi, Florianópolis, Santa Catarina, Brazil. <sup>2</sup>Laboratório de Sanidade de Organismos Aquáticos, Universidade Federal de Santa Catarina, Florianópolis, Santa Catarina, Brazil. <sup>3</sup>Laboratório de Biologia e Cultivo de Peixes de Água Doce, Universidade Federal de Santa Catarina, Florianópolis, Santa Catarina, Brazil. \*Author for correspondence. E-mail: marirozaabreu@hotmail.com

**ABSTRACT.** Stages of oocyte development were described for suruvi females (*Steindachneridion scriptum*) kept in captivity. Oocytes of 21 mature or maturing females and ovaries of 12 immature females were fixed in Karnovsky solution for 4 and 12 hours, respectively. After, they were processed for routine histology, embedded in paraffin and stained with hematoxylin-eosin. Slides were examined under a light microscope and the oocytes were measured using the LAS EZ software, using the average between the largest and the smallest diameter of each oocyte for representation. There were six types of oocytes: Chromatin nucleolus: found in immature females, with average diameter of  $9.5 \pm 4.46 \mu\text{m}$ ; Perinucleolar: present in all developmental stages with average diameter of  $67.6 \pm 15.61 \mu\text{m}$ ; Cortical alveolar: measuring  $175.6 \pm 56.58 \mu\text{m}$ ; Vitellogenic: average diameter of  $797.65 \pm 136.10 \mu\text{m}$ ; Mature: with average diameter of  $1184.98 \pm 171.13 \mu\text{m}$  and Atretic, which were found in mature or maturing females of suruvi.

**Keywords:** histology, oogenesis, fish reproduction, vitellogenesis.

### Caracterização histológica das fases de desenvolvimento ovocitário de suruvi *Steindachneridion scriptum* em condições de cativeiro

**RESUMO.** As fases de desenvolvimento ovocitário de fêmeas de suruvi (*Steindachneridion scriptum*) mantidas em cativeiro foram descritas. Ovócitos de 21 fêmeas maduras ou em maturação e ovários de 12 fêmeas imaturas foram fixados em solução de Karnovsky por 4 e 12 horas, respectivamente. Em seguida, foram processados por meio das técnicas rotineiras da histologia, com inclusão em parafina e coloração em hematoxilina-eosina. As lâminas foram analisadas em microscópio de luz e os ovócitos foram medidos por meio do software LAS EZ, usando-se a média entre o maior e o menor diâmetro de cada ovócito para representá-lo. Foi possível caracterizar seis tipos de ovócitos: Cromatina-nucléolo: observado nas fêmeas imaturas, com diâmetro médio de  $9,5 \pm 4,46 \mu\text{m}$ ; Perinucleolar: presente em todas as fases de desenvolvimento e com diâmetro médio de  $67,6 \pm 15,61 \mu\text{m}$ ; Alvéolo-cortical: medindo  $175,6 \pm 56,58 \mu\text{m}$ ; Vitelogênico: com diâmetro médio de  $797,65 \pm 136,10 \mu\text{m}$ ; Maduro: com diâmetro médio de  $1184,98 \pm 171,13 \mu\text{m}$  e Atrésico, o qual foi observado em amostras obtidas de fêmeas de suruvi em maturação e maduras.

**Palavras-chave:** histologia, ovogênese, reprodução de peixes, vitelogênese.

#### Introduction

Most fish species native to Brazil with potential for cultivation migrates towards the source of the river in the breeding season (Paulino, Miliorini, Murgas, Lima & Felizardo, 2011). This migratory behavior is restricted in fish ponds, preventing these fish reach the physiological preparation for reproduction (Pereira et al., 2009). The animals do not receive certain external stimuli and lose endocrine response appropriate for inducing final gonadal maturation. Thus, the ovaries develop only partially (complete vitellogenesis) and enters the 'dormant stage' (Andrade & Yasui, 2003).

During the 'dormant stage', there is reduced ovarian activity and adjustments to the environment

for the release of oocytes when environmental conditions are more favorable to the development and survival of the offspring (Zaniboni Filho & Weingartner, 2007). This stage can persist for several months before spawning and if the changes in the environment are not sufficient to cause the final maturation and release of oocytes, there will be follicular atresia. Some factors are known for inducing atresia, such as stress caused by critical environmental factors (e.g. oxygen, temperature, etc.) or by inadequate management during the dormancy period (Murgas, Drumond, Pereira & Felizardo, 2009; Zaniboni Filho & Weingartner, 2007).

The successful captive breeding requires the selection of mature fish showing higher chances to respond positively to induction of final maturation and spawning, comprising the selection of individuals that completed vitellogenesis and with ovaries in the 'dormant stage'. In this way, the identification of the oogenesis stage is critical to the proper selection of mature animals.

Suruvi (*Steindachmeridion scriptum*) of the order Siluriformes and family Pimelodidae, is found in the Uruguay and upper Paraná river basins (Garavello, 2005), and is one of the species listed in the Red Book of endangered species in Brazil, showing important characteristics for inclusion in the South American fish farming. Studies have demonstrated great difficulty in selecting mature suruvi females, because they do not have significant external signs indicating their gonadal development stage.

Histological studies provide knowledge and more detailed observation of the oogenesis process, assisting in the identification of reproductive mechanisms in fish, which is key to understanding the life cycle, the establishment of guidelines to work with spawning induction in fish farming and control standards to fisheries exploitation (Zaniboni-Filho & Resende, 1988).

In this context, this study provides the first histological characterization of the oocyte development of *S. scriptum* females kept in captivity, with observations in different months of the year. In this way, it will be possible to obtain samples of all oocyte developmental stages, enabling their description so as to they can serve as reference for future work on the reproduction of this species.

## Material and methods

The suruvi females analyzed in this study are derived from the first filial generation (F1) of wild broodstock caught in the upper Uruguay river and from the same spawning with induced reproduction held in September 2009 by the Laboratory of Freshwater Fish Biology and Culture (LAPAD/UFSC) (Authorization 016/2011 – NUPESC/IBAMA/SC). All specimens are individually identified with internal marks PIT-tag (Passive Integrated Transponder).

To obtain oocytes at all maturity stages, females stocked in two different rearing systems were evaluated in different months of the year. Immature females kept in the laboratory (n = 12) had weight and length (mean  $\pm$  standard deviation) of  $302.63 \pm 76.53$  g and  $31.71 \pm 2.59$  cm, respectively. Maturing and mature females kept in ponds (n = 21) had weight and length

of  $1921.21 \pm 47379$  g and  $54.14 \pm 7.13$  cm, respectively.

Immature females were killed for the removal of the ovaries in July 2013. In mature or maturing females, oocytes were taken through ovarian biopsy performed between September and December 2013, using a plastic cannula 10. The decision for biopsy to obtain these samples was to avoid the need to sacrifice these animals, which would compromise the stock of breeders of this species in LAPAD. Both ovaries and oocytes were fixed in modified Karnovsky's solution (2% Paraformaldehyde + 2% Glutaraldehyde + 0.1 M phosphate buffer - pH 7.4) and kept for 12 and 4h, respectively (Karnovsky, 1965). After, they were transferred to 70% alcohol. The material was subjected to histological dehydration in different alcohol solutions, clearing and paraffin embedding. Sections were cut in a Minot microtome to a thickness of 4 and 2  $\mu$ m for gonads and oocytes, respectively, and stained with hematoxylin-eosin and mounted with Erv-Mount.

Slides were photographed under a light microscope (Leica ICC50 HD) and oocytes were measured using the LAS EZ software, using the average between the largest and the smallest diameter of each oocyte for representation (Zaniboni-Filho & Resende, 1988). The developmental stages of the oocytes were described using as suggested by Grier, Uribe-Aranzábel and Patiño (2009).

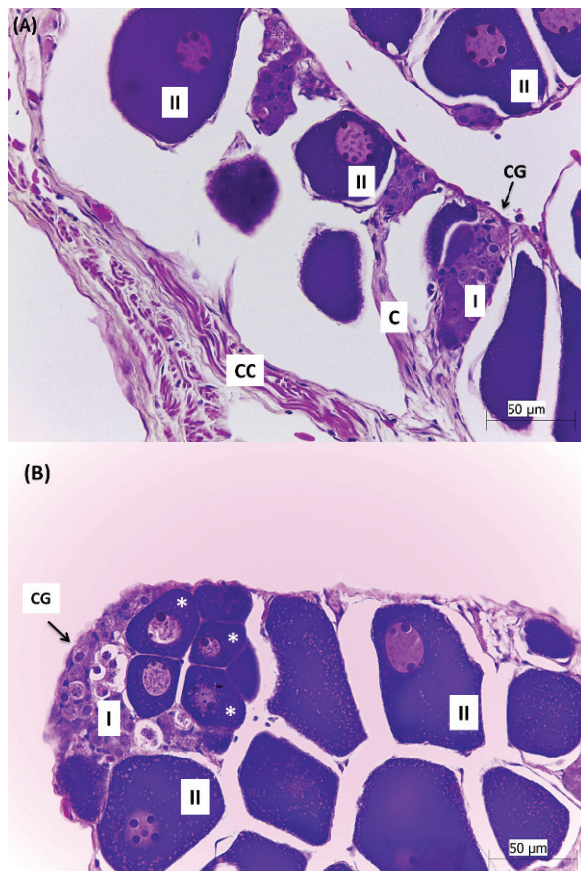
## Results and discussion

Histological observations of germ cells in suruvi, at the level of light microscopy, allowed the characterization of six types of oocytes.

The number of oocyte developmental stages may vary according to species and the criteria used by the authors. For *S. scriptum*, the oogenesis process was divided into five stages, considering the oogonia as STAGE I. Some authors consider the oogonia as the initial cells in the oogenesis process (Fávaro, Frehse, Oliveira & Júnior, 2005; Santos et al., 2006), however, other authors do not include oogonia as a developmental stage (Gonçalves, Bazzoli & Brito, 2006; Núñez & Duponchelle, 2009).

The Chromatin nucleolus oocytes (STAGE I) (Figure 1) were the smallest oocytes, appearing grouped in 'clusters of germ cells' (CG) inserted in ovigerous lamellae in vascularized areas, with average diameter ( $\pm$  SD) of  $9.5 \pm 4.46$   $\mu$ m (Figure 5). The cytoplasm of these cells is thin and the nucleus is large and rounded, with little affinity for dyes, usually with a single central and slightly

basophilic nucleolus. In turn, Perinucleolar oocytes (STAGE II) appeared generally separated from the 'cluster', probably due to their increased volume (Figure 1). The cytoplasm is more basophilic than in the previous stage, with a gradual decrease in this characteristic according to the increase in cell size. There was a reduction in the nuclear-cytoplasmic ratio. The average diameter ( $\pm$  SD) of these oocytes was  $67.6 \pm 15.61 \mu\text{m}$  (Figure 5). The nucleus of smaller diameter oocytes has one or two spherical and intensely basophilic nucleoli (Figure 1B), which become larger and more numerous in accordance with increase in cell size, gradually migrating to the nuclear periphery. These oocytes showed many different shapes, round, triangular, rectangular or oval.



**Figure 1.** Cross section of the ovary of *Steindachneridion scriptum* at immature stage. A- Ovary with Chromatin nucleolus oocytes (I) and perinucleolar oocytes (II): Chromatin nucleolus oocytes forming clusters of germ cells (CG) inserted in ovigerous lamellae; Perinucleolar oocytes (II), with gradual increase in nucleus size and in number of nucleoli, as they grow; Connective cells (CC); Capillaries (C). B- Detail of Perinucleolar oocytes (II) with varied sizes and shapes, the nucleus displaced to the periphery of the cell; (\*) Perinucleolar oocytes with one or two nucleoli.

In the stage II, the oocytes had highly basophilic cytoplasm and nucleoli, associated with intense

protein synthesis (Takahashi, Gointein & Nakaghi, 2008). Oocytes at this stage were found in slides made from tissues of females in all maturity stages, unlike the Chromatin nucleolus oocytes, which were observed only in immature females. The occurrence of oocytes stage II in all maturity stages was expected, because they represent oocytes of the 'reserve stock', which will give rise to cell populations that will begin vitellogenesis in the next breeding season (Ganeco, Nakaghi, Urbinati, Dumont-Neto & Vasques, 2001). Figure 1A and B illustrate samples taken in July. All 12 females evaluated in this period presented primarily oocytes at stages I and II, with few exceptions given the appearance of a small number of oocytes at the beginning of the Cortical alveolar stage. Thus, the oocytes that represent the subsequent stages in the other figures were all obtained from ovarian biopsy.

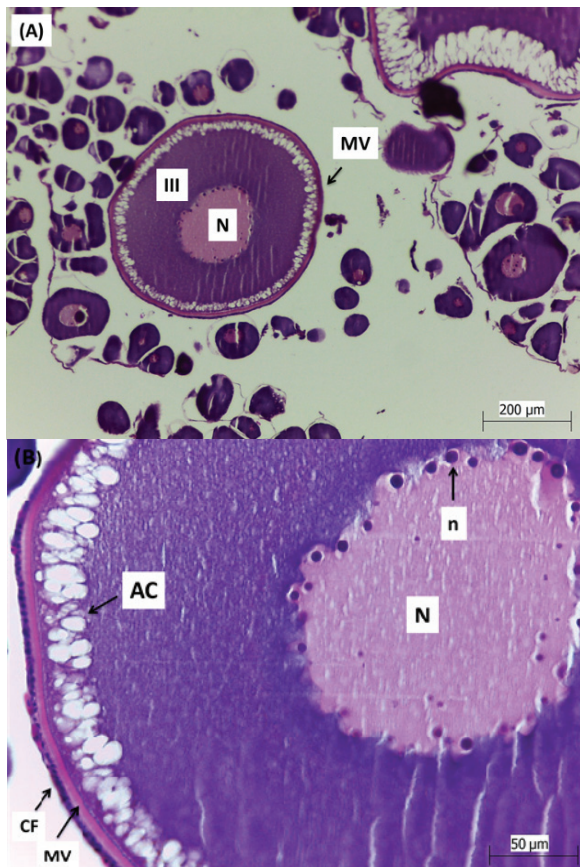
In Cortical alveolar oocytes (STAGE III), cortical alveoli appeared arranged in the periphery of the cytoplasm, with translucent granules advancing into the cell with the development of the oocyte (Figure 2), as observed for *Brycon orbignyanus* (Ganeco et al., 2001), *Cathorops spixii* (Fávaro et al., 2005) and *Brycon orthotaenia* (Gonçalves et al., 2006) and unlike that found for *Katsuwonus pelamis* (Grande, Murua, Zudaire & Korta, 2012) and *Hypostomus strigaticeps* (Takahashi et al., 2008), where the appearance of these structures began around the nucleus and was displaced to the cell periphery according to the oocyte development. The nucleus and cytoplasm increased compared to the previous stage; however, the cytoplasm increased at a greater extent. Oocytes presented an average diameter ( $\pm$  SD) of  $175.6 \pm 56.58 \mu\text{m}$  (Figure 5).

The cytoplasm in the perinuclear region continues basophilic. The nucleus is weakly stained with multiple nucleoli occupying the periphery. There is the appearance of a continuous acidophilic layer, the vitelline membrane, which is surrounded by a layer of follicular cells. The appearance of the vitelline membrane and follicular cell layer assists the identification of this developmental stage, as reported for *Hypostomus strigaticeps* (Takahashi et al., 2008).

Vitellogenic oocytes (STAGE IV) showed average diameter ( $\pm$  SD) of  $797.65 \pm 136.10 \mu\text{m}$  (Figure 5). This stage was observed at the onset of deposition of yolk granules from the periphery of the cytoplasm, which become pinkish by eosin (Figure 3). The nucleus keeps the characteristics of the previous stage. The vitelline membrane becomes

thicker and follicular cells grow and become more elongated and evident (Figure 3B).

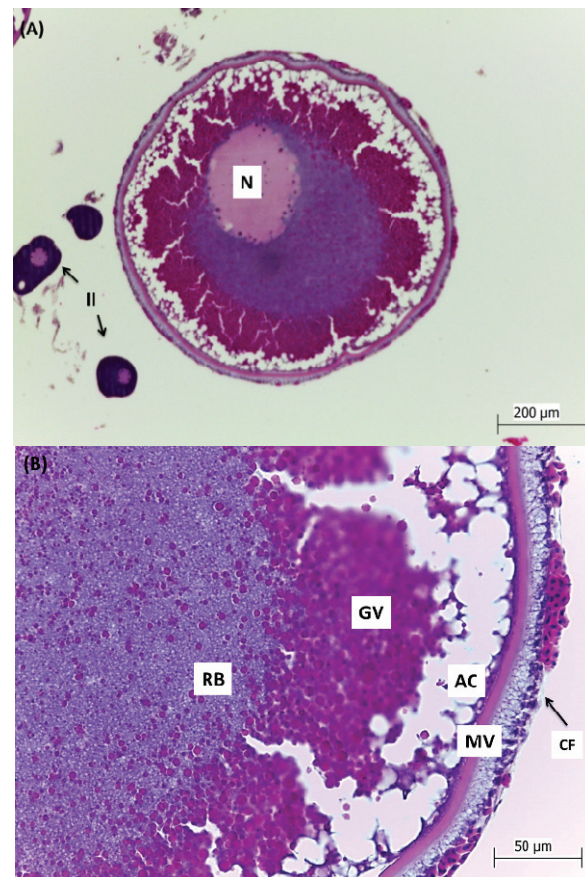
Oocytes of this stage were characterized by the presence of highly acidophilic yolk granules; the vitelline membrane and the follicle cells become more evident. The oocytes more developed of this stage will evolve to complete vitellogenesis and will be released in the next spawning (Núñez & Duponchelle, 2009).



**Figure 2.** Oocytes of *Steindachneridion scriptum*, obtained by ovarian biopsy, in histological sections. A- Oocytes in section, with Perinucleolar oocytes and Cortical alveolar oocyte (III). Nucleus of Cortical-alveolar Oocyte (N) and vitelline membrane (MV). B- Detail of Cortical alveolar oocyte, showing cortical alveoli (AC) with the vitelline membrane (MV); nucleus (N); nucleoli near the nuclear membrane (n) and follicular cells (CF) surrounding the vitelline membrane.

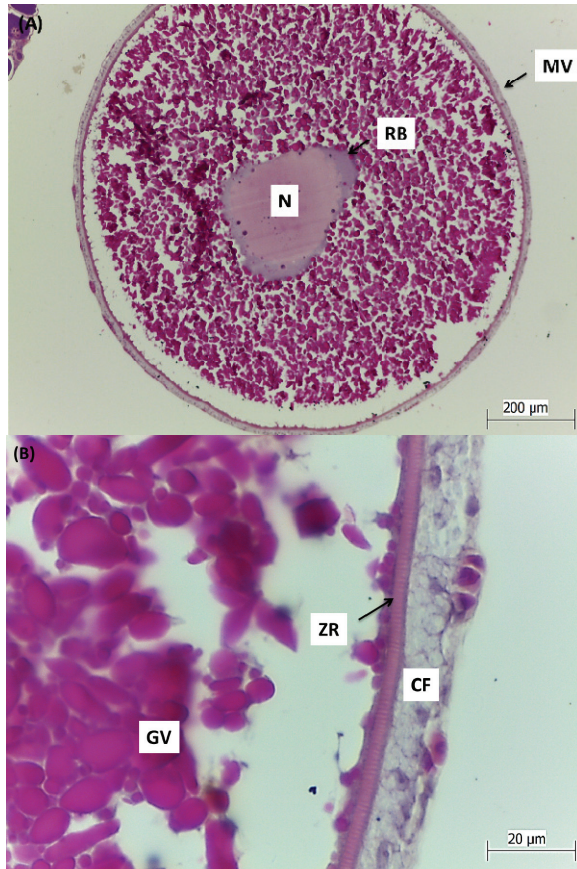
In Mature oocytes (STAGE V), basophilia disappears almost completely (Figure 4). The nucleus kept its characteristics with very small nucleoli, lost its spherical shape and shrunk. The vitelline membrane was radially arranged around the oocyte (zona radiata) (Figure 4B). Apparently, they are more mature cells observed in the germ line, occurring only in mature ovaries. Oocytes have an average diameter of  $1184.98 \pm 171.13 \mu\text{m}$  (Figure 5).

In oocytes of Stage V, the cytoplasm was filled with acidophilus yolk granules, similar to that observed for various freshwater fish (Gonçalves et al., 2006; Núñez & Duponchelle, 2009; Zaniboni-Filho & Resende, 1988). At this stage, freshwater fish oocytes are ready to be released from the follicle (Brown-Peterson, Wyanski, Saborido-Rey, Macewicz & Lowerre-Barbieri, 2011). When vitellogenesis is completed, ovarian activity starts to decrease until the environmental conditions are favorable for the development of eggs and survival of the offspring, when ovulation and spawning occur (Zaniboni Filho & Weingartner, 2007).

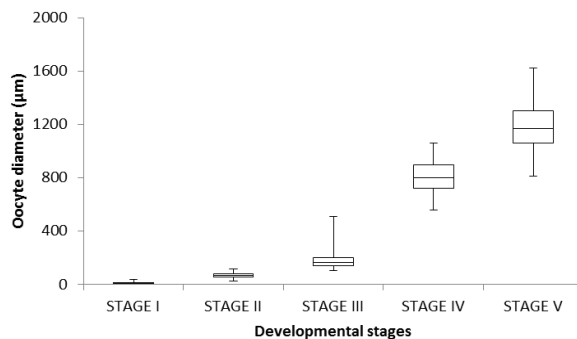


**Figure 3.** Oocytes of *Steindachneridion scriptum*, obtained by ovarian biopsy. A- General aspect of the vitellogenic oocyte with evident nucleus (N) compared to Perinucleolar oocytes (II). B- Detail of the Vitellogenic oocyte, showing the follicular cells (CF); vitelline membrane (MV); cortical alveoli (AC); yolk granules (GV) and perinucleolar basophilic region (RB), typical of Stage IV of oocyte development.

Atretic oocytes were not classified as a developmental stage, being considered structures derived from the oogenesis process (Figure 6). These oocytes exhibited the disruption of the vitelline membrane and the yolk granules lost their individuality, turning into an acidophilic mass (Figure 6B). The nucleus was no longer visible.

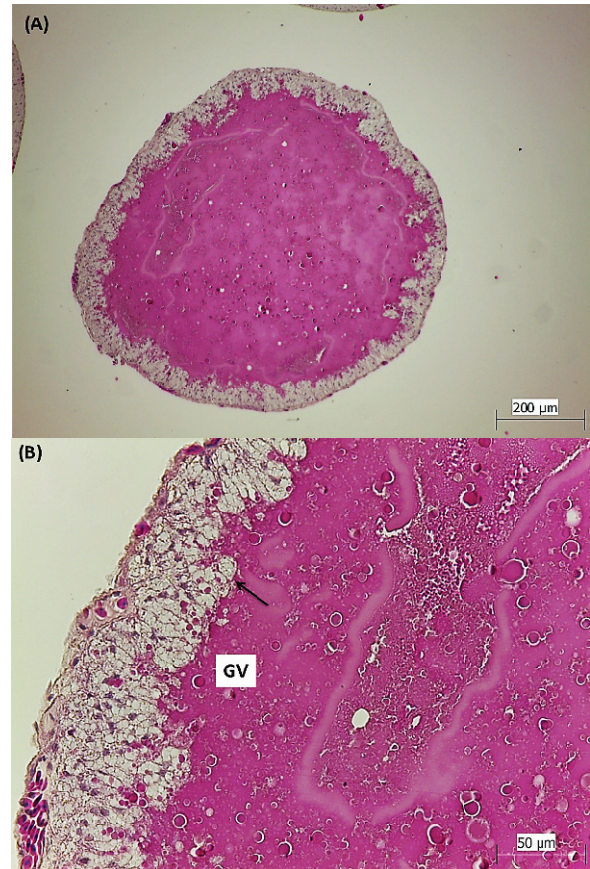


**Figure 4.** Mature oocyte of *Steindachneridion scriptum*, obtained by ovarian biopsy. A- General aspect of the Mature oocyte showing vitelline membrane (MV); basophilic cytoplasm (RB) and nucleus (N). B- Detail of the oocyte Stage V, showing the follicular cells (CF); zona radiata (ZR) and yolk granules (GV).



**Figure 5.** Minimum, maximum and average diameter of oocytes of *Steindachneridion scriptum* in each developmental stage. STAGE I: Chromatin nucleolus; STAGE II: Perinucleolar; STAGE III: Cortical alveolar; STAGE IV: Vitellogenic; STAGE V: Mature.

Atretic follicles are formed by oocytes that started the process of oocyte development, and may have completed it or not, but are reabsorbed before release. The follicular development stops and begins the degenerative processes that are most often seen in vitellogenic oocytes (Miranda, Bazzoli, Rizzo & Sato, 1999).



**Figure 6.** Atretic oocyte of *Steindachneridion scriptum*, obtained by ovarian biopsy. A- General aspect of the atretic oocyte, with no visualization of the nucleus. B- Detail of this follicle showing yolk granules (GV) losing their individuality and disruption of the vitelline membrane (arrow).

These atretic follicles were found in oocyte samples from mature or maturing females. The presence of follicular atresia is usually observed in ovarian vertebrates, both in natural environment and under captive conditions (Saidapur, 1978), nevertheless, some factors may increase the frequency of follicular atresia and may even adversely affect fecundity (Sharma & Bhat, 2014).

### Conclusion

Samplings conducted in different months of the year enabled the characterization of the five types of oocytes that make up the complete oocyte development cycle of *Steindachneridion scriptum* females kept in captivity, namely: Chromatin nucleolus, Perinucleolar, Cortical alveolar, Vitellogenic and Mature. In addition, atretic oocytes were also found in mature or maturing females.

### References

Andrade, D. R., & Yasui, G. S. (2003). Manejo da reprodução natural e artificial e sua importância na

- produção de peixes no Brasil. *Revista Brasileira de Reprodução Animal*, 27(2), 166-172.
- Brown-Peterson, N. J., Wyanski, D. M., Saborido-Rey, F., Macewicz, B. J., & Lowerre-Barbieri, S. K. (2011). A standardized terminology for describing reproductive development in fishes. *Marine and Coastal Fisheries*, 3(1), 52-70.
- Fávaro, L. F., Frehse, F. A., Oliveira, R. N., & Júnior, R. S. (2005). Reprodução do bagre amarelo, *Cathorops spixii* (Agassiz) (Siluriformes, Ariidae), da Baía de Pinheiros, região estuarina do litoral do Paraná, Brasil. *Revista Brasileira de Zoologia*, 22(4), 1022-1029.
- Ganeco, L. N., Nakaghi, L. S. O., Urbinati, E. C., Dumont-Neto, R., & Vasques, L. H. (2001). Análise morfológica do desenvolvimento ovocitário de piracanjuba, *Brycon orbignyanus*, durante o ciclo reprodutivo. *Boletim do Instituto de Pesca*, 27(2), 131-138.
- Garavello, J. C. (2005). Revision of genus *Steindachneridion* (Siluriformes: Pimelodidae). *Neotropical Ichthyology*, 3(4), 607-623.
- Gonçalves, T. L., Bazzoli, N., & Brito, M. F. G. (2006). Gametogenesis and reproduction of the matrinxã *Brycon orthotaenia* (Günther, 1864) (Pisces: Characidae) in the São Francisco river, Minas Gerais, Brazil. *Brazilian Journal of Biology*, 66(2), 513-522.
- Grande, M., Murua, H., Zudaire, I., & Korta, M. (2012). Oocyte development and fecundity type of the skipjack, *Katsuwonus pelamis*, in the Western Indian Ocean. *Journal of Sea Research*, 73, 117-125.
- Grier, J. H., Uribe-Aranzábel, M. C., & Patiño, R. (2009). The ovary, folliculogenesis and oogenesis in teleosts. In: Jamieson, B. J. M. (Org.). *Reproductive Biology and Phylogeny of Fishes* (Agnathans and Neoteleostomi) (pp. 25-84). New Hampshire: Science Publishers, Enfield.
- Karnovsky, M. J. (1965). A formaldehyde glutaraldehyde fixative of high osmolality for use in electron microscopy. *Journal of Cell Biology*, 27(2), 137-139.
- Miranda, A. C., Bazzoli, N., Rizzo, E., & Sato, Y. (1999). Ovarian follicular atresia in two teleost species: a histological and ultrastructural study. *Tissue and Cell*, 31(5), 480-488.
- Murgas, L. D. S., Drummond, M. M., Pereira, G. J. M., & Felizardo, V. O. (2009). Manipulação do ciclo e da eficiência reprodutiva em espécies nativas de peixes de água doce. *Revista Brasileira de Reprodução Animal*, (sup. 6), 70-76.
- Núñez, J., & Duponchelle, F. (2009). Towards a universal scale to assess sexual maturation and related life history traits in oviparous teleost fishes. *Fish Physiology and Biochemistry*, 35(1), 167-180.
- Paulino, M. S., Miliorini, A. B., Murgas, L. D. S., Lima, F. S. M., & Felizardo, V. O. (2011). Desempenho reprodutivo do pacu, piracanjuba e curimba induzidos com extrato de busserelina. *Boletim do Instituto de Pesca*, 37(1), 39-45.
- Pereira, G. J. M., Murgas, L. D. S., Silva, J. M. A., Miliorini, A. B., Logato, P. V. R., & Lima, D. (2009). Indução da desova de curimba (*Prochilodus lineatus*) utilizando eCG E EBHC. *Revista Ceres*, 56(2), 156-160.
- Saidapur, S. K. (1978). Follicular atresia in the ovaries of nonmammalian vertebrates. *International Review of Cytology*, 54, 225-244.
- Santos, J. E., Padilha, G. E. V., Bomcompagni-Júnior, O., Santos, G. B., Rizzo, E., & Bazzoli, N. (2006). Ovarian follicle growth in the catfish *Iheringichthys labrosus* (Siluriformes: Pimelodidae). *Tissue and Cell*, 38(5), 303-310.
- Sharma, R. K., & Bhat, R. A. (2014). Histomorphology of atretic follicles in rainbow trout (*Oncorhynchus mykiss*) from Kashmir. *Journal of Entomology and Zoology Studies*, 2(4), 21-26.
- Takahashi, E. L. H., Gointein, R., & Nakaghi, L. S. O. (2008). Maturidade do ovário no cascudo *Hypostomus strigaticeps* (Siluriformes, Loricariidae). *Acta Scientiarum. Biological Sciences*, 30(1), 107-112.
- Zaniboni-Filho, E., & Resende, E. K. (1988). Anatomia de gônadas, escala de maturidade e tipo de desova do matrinxã, *Brycon cephalus* (Günther, 1869) (Teleostei: Characidae). *Revista Brasileira de Biologia*, 48(4), 833-844.
- Zaniboni Filho, E., & Weingartner, M. (2007). Técnicas de indução da reprodução de peixes migradores. *Revista Brasileira de Reprodução Animal*, 31(3), 367-373.

Received on April 27, 2015.

Accepted on August 26, 2015.

License information: This is an open-access article distributed under the terms of the Creative Commons Attribution License, which permits unrestricted use, distribution, and reproduction in any medium, provided the original work is properly cited.