



The effects of intratesticular injection of sodium chloride on liveweights, reproductive characteristics, and histological appearance of testes in goat kids

Özdal Gökdal^{1,2*}, Vadullah Eren¹, Ülker Eren³, Ali Kemali Özüğür¹ and Okan Atay¹

¹Çine Vocational School, Aydın Adnan Menderes University, 09500 Çine, Aydın, Türkiye. ²Faculty of Agriculture, Sabbatical Leave at University of Szeged, H-6800 Hódmezővásárhely, Hungary. ³Department of Histology and Embryology, Faculty of Veterinary Medicine, Aydın Adnan Menderes University, Aydın, Türkiye. *Author for correspondence. E-mail: ogokdal@adu.edu.tr

ABSTRACT. The aim of this study was to investigate the effectiveness of intratesticular injection (ITI) of sodium chloride (NaCl) at two different concentrations for suppressing reproductive development in goat kids at two months of age. The experiment was carried out at the experimental unit of Aydın Adnan Menderes University, Çine Vocational School, located in Çine, Aydın, Turkey. The experimental groups were control (C, n = 9), a single ITI of 20% NaCl (T1, n = 8) or 40% NaCl (T2, n = 8). The growth, reproductive characteristics, and histological appearance of the testis in the kids were examined up to nine months of age in different periods. The live weights, scrotal circumference, semen and sexual behavior characteristics were not different among groups. The histological findings were observed in both testes at nine months of age. Greater intensity of destruction was observed in the testes of T1 and T2 kids than that of C kids. High levels of tubular degeneration were detected in testicular tissue samples in T1 and T2 groups. Based on the results, however, it was concluded that neither 20 nor 40% concentrations of NaCl did ensure the castration effect in the goat kids.

Keywords: scrotal circumference; chemical castration; behaviour; semen; histology.

Received on February 11 2022.

Accepted on October 4 2022.

Introduction

Castration is widespread used in livestock production in various countries to reduce aggressive behaviour, remove unpleasant male odor, and improve carcass and meat quality. For the castration of male animals, one of the immunological, physical, and chemical castration methods can be used. It has been reported, however, that physical castration including methods such as elastrator, burdizzo clamp, and surgical castration (orchietomy) has adverse effects on feed conversion, growth rate and carcass quality of animals (Daley, Adams, Daley, Patton, & Evens, 1995; Ülker et al., 2002; Haddad, Husein, & Sweidan, 2006; Zamiri, Eilami, & Kianzad, 2012). Besides, acute and chronic pain and different levels of stress caused by physical castration methods lead to questioning of these methods in terms of animal welfare (Mellema, Doherr, Wechsler, Thuerer, & Steiner, 2006; Melches, Mellema, Doherr, Wechsler, & Steiner, 2007; Becker et al., 2012). Physical castration is prohibited by pressure of several non-governmental organizations in the UK and Ireland, but is routinely used in some EU member states.

If castration needs to be done, techniques should be used that will not adversely affect the animal welfare and various performance characteristics such as growth, feed conversion efficiency and carcass characteristics. To this end, studies have focused on immunocastration and chemical castration methods for the castration of male animals (Needham, Lambrechts, & Hoffman, 2019a; Paranzini et al., 2019). Researchers have reported that immunization against Gonadotropin-Releasing Hormone (GnRH) may be one of the effective methods to reduce reproductive functions without orchietomy. The technique is based on inducing antibodies against GnRH, resulting in a suppression of spermatogenesis and testosterone production (Gökdal et al., 2010). It has been showed that immunization against GnRH could be an alternative castration technique to surgical castration in small ruminants without negatively affecting daily weight gain, carcass, and meat quality characteristics (Gökdal et al., 2010; Needham, Lambrechts, & Hoffman, 2017; 2019b). But there is no commercial product available for small ruminants (Needham et al., 2017). Furthermore, there is a high cost of the technique, and studies are underway to develop standard procedures.

As an alternative to castrating the male animals by physical methods, the effect of various chemical solutions is also being investigated (Oliveira et al., 2017; Paranzini et al., 2019). It has been observed that several chemical solutions that were tested had caused adverse effects on animal welfare, such as pain and discomfort (Okwee-Acai, Ojok, & Acon, 2008; Zedan & Al-Badrany, 2012). It has been reported (Kwak & Lee, 2013; Neto et al., 2014; Oliveira et al., 2017), however, that ITI of hypertonic saline solutions could be an alternative approach to surgical castration in males. Nevertheless, to the best of our knowledge, there is no report on the effect of a single ITI of NaCl in goat kids before puberty.

Considering all this information, it was hypothesized that a single ITI of NaCl at two different concentrations (20 or 40%) at 2 months of age would suppress sexual development of the kids. Also, it was investigated the changes in the stress parameters, and histological appearance of testes of the kids.

Material and methods

All the procedures in this study were approved by the Ethical Committee of Aydın Adnan Menderes University (ADÜ-HADYEK/64583101/2016/43).

Study location and animals

The study was performed at the Research Unit of the Aydın Adnan Menderes University Çine Vocational School (latitude 37°37' N, longitude 28°04' E) located 118 m above sea level. A total of 25 Alpine and Saanen male kids were used in the present study. Following the pregnancy period after synchronized matings in the flock, kids were weighed in 24h after birth and numbered with ear tags. Kids were kept continuously with their mothers during the first week and then only at nights. The kids were palpated for testicular size and equality of right and left testicles. The study started when the kids were two months old, and it lasted for seven months. The kids were not kept continuously enclosed and were enabled to be in the pasture for four to five hours per day.

Experimental groups and some stress parameters

At the beginning of the study, the kids were assigned into three groups considering the equality of their body weights; untreated control (C) (n = 9), a single ITI of 1 mL distilled water contained 20% NaCl (T1, n = 8) or 40% NaCl (Merck, Germany) (T2, n = 8). The initial body weights of the kids in C, T1, and T2 groups were 17.73, 17.37, and 17.41 kg, respectively. The hypertonic solutions were prepared by dissolving NaCl (50 g 250 mL⁻¹ and 100 g 250 mL⁻¹ respectively for T1 and T2 groups) in distilled water. Dimethyl sulfoxide ((CH₃)₂SO, 0.5%) was also added to the NaCl solutions as pain relief considering its anti-inflammatory and analgesic effects (Pereira et al., 2018; Silva et al., 2018). After dilution, the NaCl solutions were stored a few hours at 4°C until use. The injections were made into the medial testicular region in craniocaudal direction in both testes using a 0.40 × 40 mm needle. Before ITI, the scrotal skin was disinfected using a povidone-iodine solution (Betadine, 10%, Mundipharma, Istanbul, Türkiye). Pulse (numbers in 15 seconds), rectal temperature (°C), and respiration (numbers in 30 seconds) values were recorded in the kids immediately before and 4, 24 and 48 hours after ITI.

Growth performance and reproductive characteristics

Body weights of all kids were recorded at two months old and then bi-weekly intervals for seven months of the experimental period. Scrotal measurements were taken at the 2 (beginning of the study), 4, 6, and 9 months of age using by plastic tape measure. Semen was collected by electroejaculation for two times at six and nine months of age by using a rectal probe (Mark IV, Olivet, Ruakura, New Zealand). After insertion of the probe coated with Vaseline (Unilever, Türkiye) into the rectum, electrical pulses were applied for five seconds with five seconds resting intervals until ejaculation. Immediately after semen was collected, semen volume, semen viscosity (on a scale of 0 to 5; from watery to creamy), and pH were evaluated (Tekin, 1990). Mass motility was assessed under a microscope at 40 × by dropping an undiluted drop of fresh semen onto a heated slide (35°C) and covering the coverslip and evaluated on a 0 - 5 scale (0 = no motility, 5 = 100% motile) as described by Gallego-Calvo, Gatica, Santiago-Moreno, Guzman, and Zarazaga (2015). The same operator performed all semen assessments.

Sexual behavior characteristics of all kids were tested at eight months of age. The test was performed for a period of ten min in a 4 m × 6 m pen with a goat induced into estrus with 11 days of intravaginal

sponges impregnated with 20 mg flugeston acetate (Chronogest, Intervet, Türkiye), and 400 I.U. eCG + 0.5 mL Prostaglandin injections 48 hours before the sponge removal (at 9th day after sponge insertion). The number of flehmen responses (FRE), anogenital sniffing events (SNL), mounting attempts (MA), mountings (MO), vocalization (VO), and lateral approaches (LA), and latency to first mount (LFM, min) were recorded on the forms.

Testicular tissue sampling and evaluation

After the slaughter of all animals in T1 and T2 groups at the nine months of age, testicular tissue samples were fixed in Bouin's fluid for 24 hours for histological examinations. At the same time, testicular tissue samples were also collected via biopsy from C animals under local anesthesia. After fixation, tissue samples were transferred to 50% ethanol for 48 hours and then to 70% ethanol for 12 hours, processed through graded alcohols, cleaned in xylene, and embedded in paraffin. The paraffin tissue blocks were cut serially and a thickness of 6 μ m. The histological sections were placed on glass slides for staining. Crossmon's (1937) triple staining method was used for the evaluation of nonspecific seminiferous tubular changes in the testis (Creasy et al., 2012; Gopinath & Mowat, 2014).

Statistical analysis

Normal distribution of the data of the body weight and scrotal circumference was confirmed with the Shapiro-Wilk test and then compared by GLM in SAS (1998), considering treatment (ITI of NaCl or not of NaCl), time (different periods in each characteristic), and the interaction between treatment and time as main effects. Time was included in the model as a repeated data. Data of pain-related observations, sexual behavior, and semen characteristics were normalized with Log transformation before the statistical analysis, whereas the results were presented as descriptive statistics. The residues of these characteristics were analyzed by non-parametric tests (Shapiro-Wilk or Kruskal-Wallis). Post hoc (C, T1, and T2) comparisons were performed. Data are presented as the mean \pm SEM. Differences were considered as significant when $p \leq 0.05$.

Results and discussion

After ITI, no abnormalities were detected in the appearance of the testes and scrotum in any of the kids. Although the data are not shown, there were no differences concerning touch sensitivity, testicular sclerosis, or testes mobilities in scrotum among groups. This agrees with previous research that had been done in rats in which skin infection, necrosis, and testicular abscess were not detected in hypertonic saline (20%) administered animals (Emir et al., 2008). In another study, it was shown that there were no detectable changes in the general health status of rats after the ITI of hypertonic saline, except for testicular atrophy (Kwak & Lee, 2017). Pulse (numbers in 15 seconds), rectal temperature ($^{\circ}$ C) and respiration (numbers in 30 seconds) result in the C, T1 and T2 groups immediately before and 4, 24 and 48 hours after ITI are given in Figure 1a, 1b, and 1c, respectively.

The pulse number, rectal temperature, and respiration number were almost parallel in the groups at any time during the experiment ($p > 0.05$). There was no treatment and time interaction for pulse number, rectal temperature, and respiration number of the kids. The rectal temperatures, pulse, and respiration numbers of the kids in the present study were almost similar in the groups at all stages. This shows that the ITI of NaCl did not cause impairment in the vital functions of the male kids. These results corroborate the those of the previous study (Neto et al., 2014) which reported that rectal temperature was not affected after ITI of sodium chloride (20%) in calves.

The body weights of the kids in C, T1 and T2 groups during the experimental period are presented in Figure 2a. The changes in scrotal circumferences of the kids at 2 (beginning of the study), 4, 6, and 9 months of age were presented in Figure 2b.

There were no significant differences in body weights among the groups during the experiment ($p > 0.05$), and there was not an interaction between treatment and time. The ITI of NaCl had no adverse effect on the body weights of the kids both in T1 and T2 groups compared to C animals. There was no group effect on scrotal circumferences of the kids ($p > 0.05$), and there was not an interaction between treatment and time for scrotal circumferences of the kids.

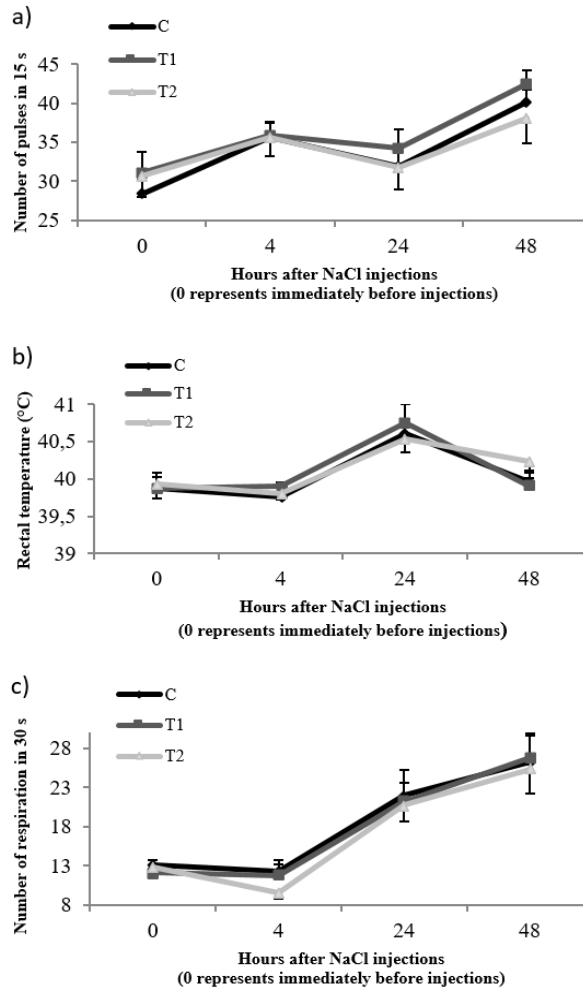


Figure 1. Pulse (numbers in 15 seconds) (a), rectal temperature (°C) (b) and respiration (numbers in 30 seconds) (c) values in the control (C) and NaCl groups (T1 and T2) immediately before (0) and 4, 24 and 48 hours after injections

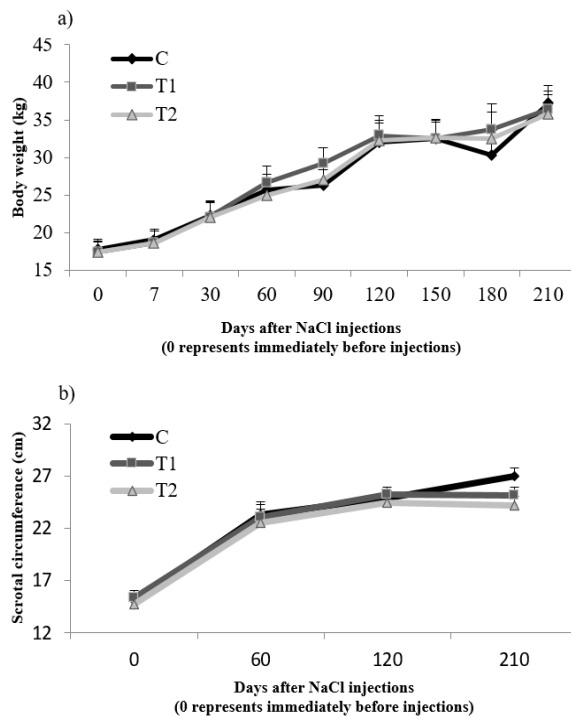


Figure 2. a) The growth performance of the kids in control (C) and NaCl administered groups (T1 and T2). b) The changes in scrotal circumferences of the kids in control and NaCl groups during the experiment

The ITI of NaCl solutions had no adverse effect on the body weights of the kids in T1 and T2 groups compared to C animals. This proves that gonadal steroids of NaCl administered animals still play an essential role in the growth of the animals in T1 and T2 groups. A decrease in daily weight gain can be an indirect sign of chronic pain after castration (Becker et al., 2012). The absence of significant differences among groups in the present study reveals that there is no body weight loss caused by the pain and stress effect. In the present study, NaCl solutions had no significant adverse effect on the testicular growth of the kids. A single ITI of NaCl at concentrations of 20 or 40% caused a relative reduction in scrotal circumference compared to the C animals, whereas the differences among groups were not significant. Unlike, some researchers observed smaller and lighter testicles in dogs or rats administered ITI of 20 or 30% NaCl (Kwak, Lee, & Lee, 2010; Emir, Sunay, Yalbuздаđ, Karakaya, & Demokan, 2011; Canpolat, Karabulut, & Eroksuz, 2016).

Some semen characteristics of the kids in the C, T1 and T2 groups at six- and nine months old are shown in Table 1.

Table 1. Some semen characteristics (mean±s.e.) of Control (C) and NaCl groups (T1 20% NaCl and T2 40% NaCl) at 6 and 9-mo old.

| Semen characteristics | Groups | | |
|---|------------|------------|------------|
| | C n=9 | T1 n=8 | T2 n=8 |
| 6 months old (4 months after injection) | | | |
| Semen volume (mL) | 0.633±0.16 | 0.787±0.21 | 0.912±0.20 |
| Viscosity (0-5) | 2.40±0.16 | 2.83±0.29 | 2.75±0.25 |
| pH | 7.98±0.16 | 7.60±0.17 | 7.87±0.12 |
| Mass motility (0-5) | 2.50±0.50 | 2.56±0.45 | 2.50±0.46 |
| 9 months old (7 months after injection) | | | |
| Semen volume (mL) | 0.650±0.15 | 0.818±0.07 | 0.637±0.14 |
| Viscosity (0-5) | 2.87±0.19 | 3.00±0.26 | 2.86±0.12 |
| pH | 7.62±0.33 | 7.62±0.41 | 7.57±0.37 |
| Mass motility (0-5) | 2.57±0.55 | 3.62±0.49 | 3.26±0.61 |

There were no differences ($p > 0.05$) among the groups in terms of semen volume, viscosity, pH, and mass motility four and seven months after ITI of NaCl. There was not found any interaction between treatment and time. A satisfactory castration method should suppress spermatogenesis (Becker et al., 2012). In this study, it seemed that the ITI of NaCl solution was not successful in suppressing testicular functions of the kids. There was no significant effect of ITI of NaCl solutions (20 and 40%) on semen characteristics of the kids when they were at six and nine months old. This showed that the castration effect could not achieve with 20 and 40% NaCl concentrations on the animals at two months old. In contrast to the present study, it was reported that spermatogenesis was blocked in cattle at 12 months of age when NaCl (20%) administered up to 20 days of age (Neto et al., 2014). But the number of studies on NaCl is quite limited to compare our results.

Figure 3 shows the values of the sexual behavior characteristics of the kids in the Control and NaCl administered groups. Male sexual behaviors of the kids in C, T1 and T2 groups at the eight months old age could not be suppressed ($p > 0.05$) either by the ITI of 20 or 40% NaCl (Figure 3).

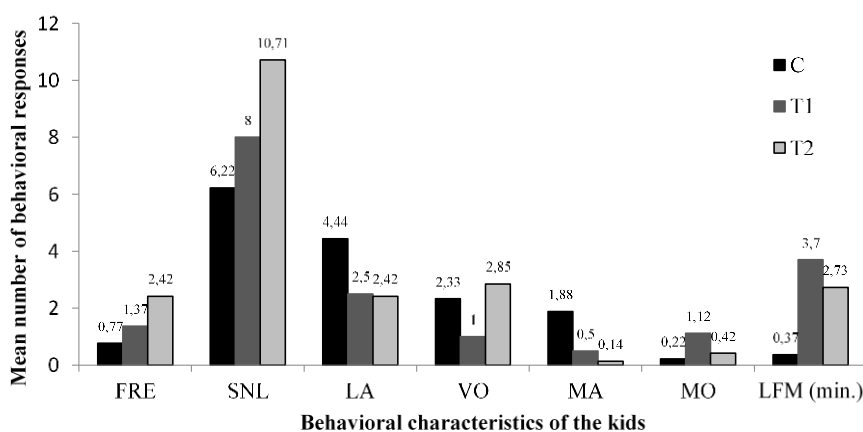


Figure 3. Mean number of behavioural responses of the kids in Control (C) and NaCl groups (T1 and T2). FRE: the number of flehmen responses, SNL: the number of anogenital sniffing, LA: the number of lateral approaches, VO: the number of vocalization, MA: the number of mount attempts, MO: the number of mounts, LFM (min.) the latency to first mount.

In the present study, the sexual behaviors of the male kids in the C, T1, and T2 groups were evaluated individually in a pen with an estrus female for ten minutes. The investigated characteristics related to sexual behaviors of the kids at the eight months of age were not suppressed by the ITI of 20 or 40% NaCl. To the best of our knowledge, no studies are investigating the effect of NaCl solutions on sexual behavior characteristics in goat kids.

In this study, testicular tissue samples were examined under microscopically. When compared with the C group (Figure 4), it was observed that the number of tubules with the normal histological appearance and Leydig cells were low in the T1 and T2 groups. In addition, nonspecific changes were commonly observed in testicular tissues of the T1 and T2 groups.

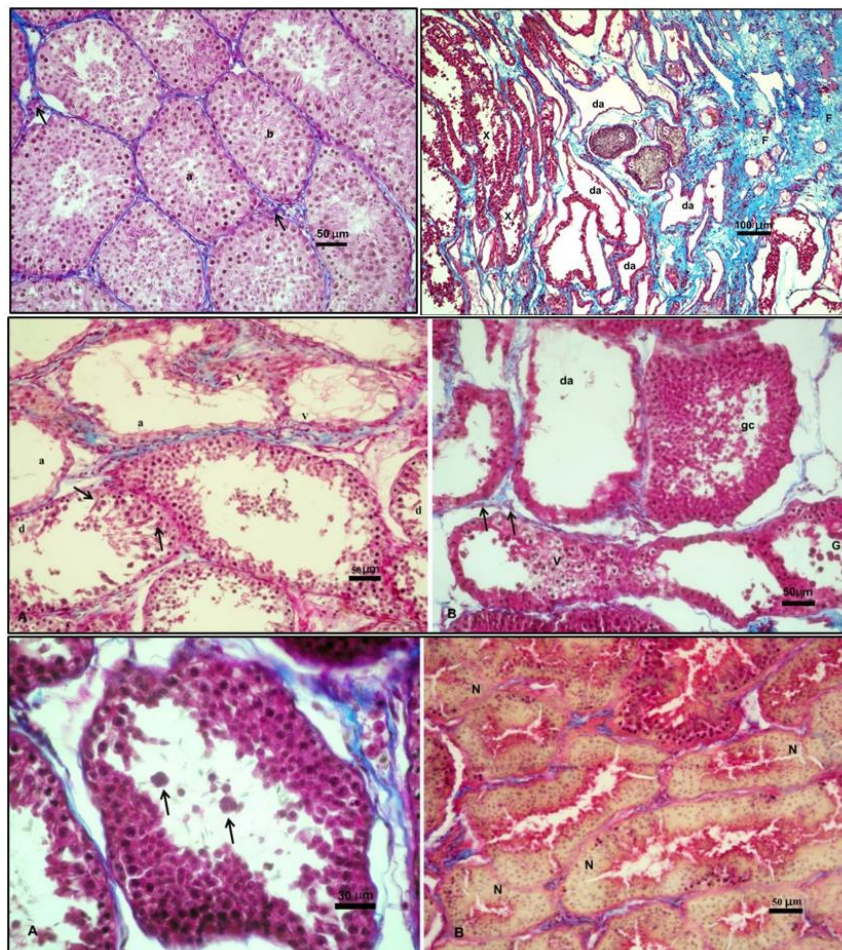


Figure 4. Top left: Histological appearance of testis from control group. a: Stage II seminiferous tubule, b: Stage V seminiferous tubule, arrows: Leydig cells. Triple staining. Top right: The appearance of various nonspecific changes in testicular tissue. F: Increase of interstitial tissue (fibrosis), x: Tubular degeneration, da: Tubular degeneration/atrophy, S: Sperm stasis in seminiferous tubules. Triple staining. Middle left: A. The appearance of tubular degeneration (d) and tubular degeneration/ atrophy (a). v: (vacuolation), arrows: Sertoli cells. Middle right: B. The appearance of nonspecific seminiferous tubular changes. da: Tubular degeneration/ atrophy, gc: Exfoliation of germ cells, v: Vacuolation, G: multi nucleated giant cells, arrows: Leydig cells. Triple staining. Down left: A. The appearance of multinucleated giant cells. Arrows: Multinucleated giant cells. Down right: B. The appearance of diffuse degenerative necrotic changes. N: Necrotic areas (coagulation necrosis). Triple staining.

In both experimental groups, tubular degeneration was found to be at a reasonably high level in testicular samples. Moreover, epithelial atrophy (tubular degeneration/atrophy) due to degeneration was also observed in the seminiferous tubules. Tubular degenerative changes were also observed as vacuolation, the presence of multinuclear giant cells, tubular necrosis, exfoliation of germ cells, degeneration of germ cells and spermatid retention. On the other hand, in tissue sections, it was also found that there were diffuse degenerative necrotic changes (coagulation necrosis), sperm stasis, and increased interstitial connective tissue in some cases (Figure 4).

Spermatogenesis initiates at four months of age in Alpine goats (Rodrigues, Costa, & Fonseca, 2012; Faucette et al., 2014). Alpine goats are in the impuberal phase from birth to three months of age, the prepuberal phase during the fourth month, reach puberty at five months of age, and reach sexual maturity at

nine months of age (Rodrigues et al., 2012). Additionally, Ahmad and Noakes (1996) reported that sexual maturity occurred at a mean age of 172.7 days in British Sannen and Alpine goats. In this research, NaCl administration was carried out in the impuberal phase and testes were examined after seven months and so in sexual maturity time.

In the present study, high level degenerative changes found in seminiferous tubules of nine months old kids in T1 and T2 groups, but chemical castration was not occurred efficiency as distinct from calves (Neto et al., 2014) and rats (Kwak & Lee, 2013). ITI of NaCl at concentrations of 20 and 40% in the present study seems to be reversible degenerative effect on the testicular tissue during the seven months. Furthermore, some researchers (Neto et al., 2014; Canpolat et al., 2016; Oliveira et al., 2017) reported that the age of the animals strongly influences the efficacy of chemical castration. Oliveira et al. (2017) observed that ITI of 20% NaCl in calves up to 20 d-old had led extensive testicular fibrosis, replacement of parenchymal components by dense connective tissue and coagulative necrosis of Leydig cells and seminiferous tubules. Canpolat et al. (2016) observed focal coagulation necrosis in testicular tissue together with diffuse and severe degenerative changes in seminiferous tubules and sparse Leydig cell in tubular lumen after ITI of 20% sodium chloride in non-adult dogs. In the calves after ITI of 30% NaCl when they were five months old, were observed intact seminiferous tubules by Oliveira et al. (2017) and reported that 83.3% of animals had intact mediastinum, whereas only 16.7% of the samples showed both structures. Nevertheless, in the same study it was observed that after 30% NaCl injections most testicles had intact areas of seminiferous tubules and mediastinum 60 days after the procedure, indicating that such method is not effective for chemical castration of older calves.

Conclusion

In conclusion, a single ITI of 20 or 40% NaCl in both testes in goat kids at two months of age did cause specific degenerations in the testicular tissue but could not suppress the reproductive characteristics of the kids, regardless of concentration of sodium chloride.

Acknowledgements

The authors thank Assoc.Prof.Dr. Suna Akkol from Van Yüzüncü Yıl University for statistical analysis of data and thank to Assist.Prof. Dr. Tugrul Epikmen from the Department of Pathology for his assistance in the determination of nonspecific tubular changes. This research was supported financially by Aydın Adnan Menderes University Scientific Research Project Commission (ADUBAP), Project No: ÇMYO: 18001.

References

- Ahmad, N., & Noakes, D. E. (1996). Sexual maturity in British breeds of goat kids. *British Veterinary Journal*, 152, 93-103. DOI: [https://doi.org/10.1016/s0007-1935\(96\)80089-3](https://doi.org/10.1016/s0007-1935(96)80089-3)
- Becker, J., Doherr, M. G., Bruckmaier, R. M., Bodmer, M., Zanolari, P., & Steiner, A. (2012). Acute and chronic pain in calves after different methods of rubber-ring castration. *The Veterinary Journal*, 194(3), 380-385. DOI: <https://doi.org/10.1016/j.tvjl.2012.04.022>
- Canpolat, I., Karabulut, E., & Eroksuz, Y. (2016). Chemical castration of adult and non-adult male dogs with sodium chloride solution. *IOSR Journal of Agriculture and Veterinary Science*, 9(12), 9-11. DOI: <https://doi.org/10.9790/2380-0912010911>
- Creasy, D., Bube, A., Rijk, E. D., Kandori, H., Kuwahara, M., Masson, R., ... Whitney, K. (2012). Proliferative and nonproliferative lesions of the rat and mouse male reproductive system. *Toxicologic Pathology*, 40(6 suppl), 40-121. DOI: <https://doi.org/10.1177/0192623312454337>
- Crossmon, G., (1937). Modification of Mallory's connective tissue stain with a discussion of the principles involved. *The Anatomical Record*, 69, 33-38. DOI: <https://doi.org/10.1002/ar.1090690105>
- Daley, D. A., Adams, T. E., Daley, C. A., Patton, W. R., & Evens, J. L. (1995). Effects of immunocastration on growth, carcass characteristics and reproductive development in ram lambs. *Sheep and Goat Research Journal*, 11, 31-34.
- Emir, L., Dadalı, M., Sunay, M., Demokan, E., Çaydere, M., & Üstün, H. (2008). Chemical castration with intratesticular injection of 20% hypertonic saline: A minimally invasive method. *Urologic Oncology: Seminars and Original Investigations*, 26(4), 392-396. DOI: <https://doi.org/10.1016/j.urolonc.2007.05.013>

- Emir, L., Sunay, M., Yalbuздаğ, O., Karakaya, Y., & Demokan, E. (2011). Hormonal and pathologic changes after chemoablation of testes with hypertonic saline solution as a treatment method alternative to orchiectomy in patients with hormone sensitive metastatic prostatic cancer. *Urologic Oncology: Seminars and Original Investigations*, 29(2), 212-217. DOI: <https://doi.org/10.1016/j.urolonc.2008.12.021>
- Faucette, A. N., Maher, V. A., Gutierrez, M. A., Jucker, J. M., Yates, D. C., Welsh, T. H. Jr, ...Forrest, D. W. (2014). Temporal changes in histomorphology and gene expression in goat testes during postnatal development. *Journal of Animal Science*, 92(10), 4440-4448. DOI: <https://doi.org/10.2527/jas.2014-7903>
- Gallego-Calvo, L., Gatica, M. C., Santiago-Moreno, J., Guzmán, J. L., & Zarazaga, L. A. (2015). Seasonal changes in reproductive activity, sperm variables and sperm freezability in Blanca Andaluza bucks. *Spanish Journal of Agricultural Research*, 13(4), e0403. DOI: <https://doi.org/10.5424/sjar/2015134-8168>
- Gökdal, Ö., Atay, O., Ülker, H., Kayaardı, S., Kanter, M., DeAvila, D. M., & Reeves, J. J. (2010). The effects of immunological castration against GnRH with recombinant OL protein (Ovalbumin-LHRH-7) on carcass and meat quality characteristics, histological appearance of testes and pituitary gland in Kıvırcık male lambs. *Meat Science*, 86(3), 692-698. DOI: <https://doi.org/10.1016/j.meatsci.2010.06.006>
- Gopinath, C., & Mowat, V. (2014). *The male reproductive system*. Totowa, NJ: Humana Press
DOI: https://doi.org/10.1007/978-1-62703-998-7_6
- Haddad, S. G., Husein, M. Q., & Sweidan, R. W. (2006). Effects of castration on growth performance and carcass characteristics of Awassi lambs fed high concentrate diet. *Small Ruminant Research*, 65(1-2), 149-153. DOI: <https://doi.org/10.1016/j.smallrumres.2005.05.029>
- Kwak, B. K., Lee, C. S., & Lee, S. H. (2010). Histological changes in rat testis by injection of hypertonic saline. *Development and Reproduction*, 14(4), 281-286.
- Kwak, B. K., & Lee, S. H. (2013). Intratesticular Injection of Hypertonic Saline: Non-Invasive Alternative Method for Animal Castration Model. *Development and Reproduction*, 17(4), 435-440.
DOI: <https://doi.org/10.12717/DR.2013.17.4.435>
- Kwak, B. K., & Lee, S. H. (2017). Evaluation of Newly Developed Chemical Castration Method: Changes in Hormone Gene Expression of Hypothalamic-Pituitary Axis. *Development & Reproduction*, 21(3), 307-315.
DOI: <https://doi.org/10.12717/DR.2017.21.3.307>
- Melches, S., Mellema, S. C., Doherr, M. G., Wechsler, B., & Steiner, A. (2007). Castration of lambs: A welfare comparison of different castration techniques in lambs over 10 weeks of age. *The Veterinary Journal*, 173(3), 554-563 DOI: <https://doi.org/10.1016/j.tvjl.2006.01.006>
- Mellema, S. C., Doherr, M. G., Wechsler, B., Thueer, S., & Steiner, A. (2006). Influence of local anaesthesia on pain and distress induced by two bloodless castration methods in young lambs. *The Veterinary Journal*, 172(2), 274-283. DOI: <https://doi.org/10.1016/j.tvjl.2005.06.002>
- Needham, T., Lambrechts, H., & Hoffman, L.C. (2017). Castration of male livestock and the potential of immunocastration to improve animal welfare and production traits: Invited Review. *South African Journal of Animal Science*, 47(6), 731-742. DOI: <https://doi.org/10.4314/sajas.v47i6.1>
- Needham, T., Lambrechts, H., & Hoffman, L.C. (2019a). Influence of immunocastration vaccine administration interval on serum androgen concentrations and testis activity in ram lambs. *Small Ruminant Research*, 170, 82-90. DOI: <https://doi.org/10.1016/j.smallrumres.2018.11.016>
- Needham, T., Lambrechts, H., & Hoffman, L. C. (2019b). Influence of extending the pre-slaughter interval after second vaccination on the carcass cutting yield and the quality of meat from immunocastrated lambs. *Meat Science*, 148, 13-18. DOI: <https://doi.org/10.1016/j.meatsci.2018.09.014>
- Neto, O. A., Gasperin, B. G., Rovani, M. T., Ilha, G. F., Nóbrega, J. E., Mondadori, R. G., ...Antoniazzi, A. Q. (2014). Intratesticular hypertonic sodium chloride solution treatment as a method of chemical castration in cattle. *Theriogenology*, 82(7), 1007-1011. DOI: <https://doi.org/10.1016/j.theriogenology.2014.07.020>
- Okwee-Acai, J., Ojok, L., & Acon, J. (2008). Testicular morphologic and hormonal responses to an intratesticular injection of lactic acid for induction of chemosterilisation in adult mubende goats. *Asian Journal of Advanced Basic Sciences*, 3, 5-11.
- Oliveira, F. C., Ferreira, C. E. R., Haas, C. S., Oliveira, L. G., Mondadori, R. G., Schneider, A., ... Lucia, T., Jr. (2017). Chemical castration in cattle with intratesticular injection of sodium chloride: Effects on stress and inflammatory markers. *Theriogenology*, 90, 114-119.
DOI: <https://doi.org/10.1016/j.theriogenology.2016.12.001>

- Paranzini, C. S., Cardoso, G. S., Souza, A. K., Perencin, F. M., Melanda, C. A. A., Bracarense, A. P. F. R. L., & Martins, M. I. M. (2019). Use of infrared thermography to evaluate the inflammatory reaction in cat testis after intratesticular injection of 0.9% NaCl or 20% CaCl₂ with 1% lidocaine. *Arquivo Brasileiro de Medicina Veterinária e Zootecnia*, *71*(3), 929-938. DOI: <https://doi.org/10.1590/1678-4162-10741>
- Pereira, L. F., Dias, F. G. G., Miguel, M. P., Honsho, C. S., Tavares, D. C., Hellú, J. A. A., & Souza, F. F. (2018). Testicular histological evaluation and serum testosterone concentrations of bulls after chemical castration with calcium chloride. *Pesquisa Veterinária Brasileira*, *38*(8), 1554-1563. DOI: <https://doi.org/10.1590/1678-5150-PVB-4945>
- Rodrigues, M. H., Costa, D. S., & Fonseca, F. A. (2012). Proliferation of seminiferous epithelium cells during the postnatal development in goats. *Animal Reproduction Science*, *135*(1-4), 25-30. DOI: <https://doi.org/10.1016/j.anireprosci.2012.08.031>
- Statistical Analysis System [SAS]. (1998). *User's guide*. Cary, NC: SAS Institute Inc.
- Silva, R. C. A., Paranzini, C. S., Franco, L. G., Miguel, M. P., Honsho, C. S., & Souza, F. F. (2018). Calcium chloride combined with dimethyl sulphoxide for the chemical sterilization of dogs. *Reproduction in Domestic Animals*, *53*(6), 1330-1338. DOI: <https://doi.org/10.1111/rda.13252>
- Tekin, N., (1990). Erkek Üreme Organlarının Muayenesi (Androlojik Muayeneler) (in Turkish). In E. Alaçam (Ed.), *Theriogenology* (p. 53-67), Turkey, TUR: Nurool Matbaacılık A.S.
- Ülker, H., Gökdal, Ö., Temur, C., Budağ, C., Oto, M., de Avila, D. M., & Reeves, J. J. (2002). The effects of immunization against LHRH on body growth and carcass characteristics in Karakaş ram lambs. *Small Ruminant Research*, *45*(3), 273-278. DOI: [https://doi.org/10.1016/S0921-4488\(02\)00153-0](https://doi.org/10.1016/S0921-4488(02)00153-0)
- Zamiri, M. J., Eilami, B., & Kianzad, M. R. (2012). Effects of castration and fattening period on growth performance and carcass characteristics in Iranian goats. *Small Ruminant Research*, *104*(1-3), 55-61. DOI: <https://doi.org/10.1016/j.smallrumres.2011.11.008>
- Zedan, I. A., & Al-Badrany, M. S. (2012). Chemical castration in Local Breed Bucks. *Iraqi Journal of Veterinary Science*, *26*(Suppl 1), 5.