

Effects of Lymphatic Drainage on Cellulitis Assessed by Magnetic Resonance

Patrícia Froes Meyer*, Nara Mendes Martins, Flávia Mendes Martins, Rosimary Araújo Monteiro and Karla Morganna Pereira Pinto de Mendonça

Centro de Ciências da Saúde; Universidade Federal do Rio Grande do Norte; Av. General Gustavo Cordeiro de Farias, s/n; 59010180; Natal, RN - Brasil

ABSTRACT

The aim of this study was to assess the use of magnetic resonance as a new method for evaluating the manual lymphatic drainage technique in treating cellulitis. Cellulitis is one of the main esthetic problems that lead women toward seeking guidance and specific treatments. There are various therapeutic approaches, owing to the multi-factorial nature of its pathogen, although the effectiveness of most of these has not been definitively proven, given that the assessment methods used are mostly subjective or do not provide enough information on subcutaneous tissue. The introduction of magnetic resonance as a means of assessing a lymphatic drainage technique in cellulitis treatment makes the evaluation more accurate, since it enables a detailed study of subcutaneous architecture.

Keywords: cellulitis, lymphatic drainage, magnetic resonance

INTRODUCTION

Cellulitis is an anti-esthetic spreading bacterial infection just below the skin surface. It develops primarily from an alteration in blood circulation and from lymph which causes structural changes in subcutaneous adipose tissue, in collagen and in adjacent proteoglycans (Lucassen et al., 1997). There is a wide range of treatments for this pathology, such as ionophoresis, ultrasound, thermotherapy, pressotherapy, electrolipophoresis, liposuction, carboxytherapy and lymphatic drainage (Rossi & Vergnanini, 2000; Smalls et al., 2006; Brandi et al., 2001). The problem lies in the fact that most cellulitis treatments have not been proven to be effective, since the assessment methods used are mostly subjective, or do not

provide enough information to the study of subcutaneous tissue (Hexsel & Mazzuco, 2000; Piérard, Nizet & Piérard-Franchimont, 2000). Currently, magnetic resonance (MR) is deemed to be one of the most objective methods for assessing the response to the cellulitis treatment, given that it allows for a detailed study of subcutaneous tissue, making observation of the cellulitis effect on skin structure possible (Avram & David, 2004). A high-resolution MR microimage enables us to visualize the architecture of the dermal and epidermal layers, the thickness and structural alterations of connective tissue in the dermis and of subcutaneous fat cells in the hypodermis, correlated to skin abnormalities, thereby rendering it more reliable, since it provides for a more detailed study of subcutaneous tissue. This brings

* Author for correspondence

forth feedback on the changes which may occur in this tissue after therapy (Avram & David, 2004, Mirrashed et al., 2006).

The aim of this study was to evaluate the use of magnetic resonance as a new objective therapeutic assessment technique, by analyzing the effects of manual lymphatic drainage on the treatment of cellulitis.

MATERIALS AND METHODS

Subject selection

Three women who were undergoing treatment at a functional-dermatology physical therapy clinic were randomly selected. The inclusion criteria were the following: age between 18 and 30 years; body mass index (BMI) between 18.2 and 24.9 kg/cm², normal weight, according to the Brazilian Association on the Study of Obesity and Metabolic Syndrome (ABESO) guidelines; constant weight during the previous year; regular menstrual cycle (being in the pre-menstrual period); moderate to advanced cellulitis, according to Ulrich's classification; non-smoker; no history of diabetes; nonuse of hormonal contraceptives, sedentary. The exclusion criteria were as follows: pregnancy; presence of cerebral aneurism clips, presence of a pacemaker or placement of a stent within the previous 3 months.

Post-selection assessment

The patients were submitted to a post-selection assessment in the following sequence:

1. Measurement of weight and height on a non-digital scale. These measurements were checked again to confirm the data collected at the initial interview. Weight was also measured at the tenth and twentieth session to control BMI during the study.
2. Magnetic resonance examination on a Toshiba Exelart 1.5T device. Examination technique: Axial and Sagittal, spin echo (SE) T1-weighted sequence, (repetition time (RT) = 630 ms; echo time (ET) = 15 ms, 192 x 384 matrix). Sagittal fast spin-echo inversion recovery T2-weighted sequence (RT = 7000 ms, ET = 80 ms, Inversion time (IT) = 140 ms, 192 x 256 matrix). The sequences were obtained before and after treatment in the post-menstrual period. A 50-cm circular coil with small FOV (10 x 10 cm) and cut-off thickness of 3.0 mm was used (Mirrashed, et al., 2006; Gensanne et al., 2006). The patients

were submitted to the examination one week before the start of treatment.

Magnetic resonance examination stages

In the orthostatic position, the location of the 50 cm circular coil was marked with a permanent pen below the right gluteal fold; the coil ring was located at the right subgluteal region. The marking was redone at each treatment session so that no positioning error would occur during its placement in the post-treatment examination. After marking, the patients were positioned in ventral decubitus on the magnetic board, and the coil was positioned at the previously-marked region and held in place with adhesive tape, without coil pressure on the skin. The resonance examination was then initiated, lasting 30 minutes on average.

Intervention

The following procedures were performed, after post-selection assessment:

Lymphatic drainage treatment took place over 20 sessions, three times a week on alternate days, between 01/2007 and 03/2007. Each session occurred as follows: manual lymphatic drainage of the lower limbs for 60 minutes, executed in the anterior and posterior region of the thigh and leg.

Reassessment

Reassessment was performed at the end of these 20 sessions, following the pattern of the first evaluation.

RESULTS AND DISCUSSION

The comparative medical report between pre and post-treatment magnetic resonance examinations showed the following:

1. The three patients exhibited thickening of subcutaneous cellular tissue, associated to the presence of intradermal extrusions, characterizing cellulitis. Similar findings were found by Rosebaum et al. (1998), who, in a study on the morphology and biochemistry of cellulitis using ultrasonography, reported a diffuse extrusion pattern of the adipose tissue evolving toward the reticular dermis in individuals with cellulitis. In 2006, Mirrashed et al., using magnetic resonance, found that the percentage of fat contained in the dermis was significantly higher in women with more advanced cellulitis (Figure 1).

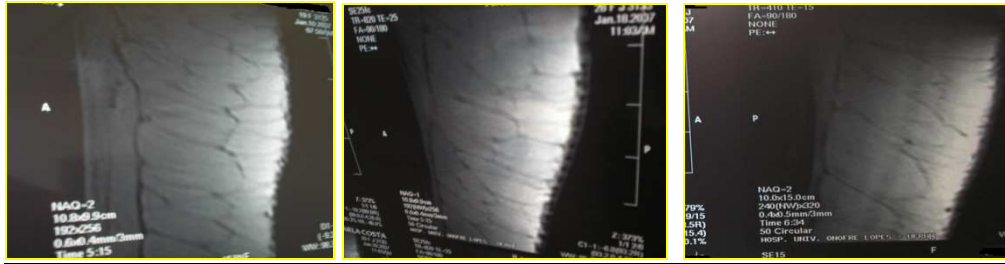

Figure 1 - Sagittal plane T1-weighted pre-treatment images of patients 1, 2 and 3.

2. The three patients showed no important alteration in the degree of intradermal extrusion of subdermal adipose tissue at post-treatment examination. Patients 1 and 2 exhibited no significant change in pre- and post-treatment

subcutaneous fat tissue. Patient 3, however, showed a slight thickness increase in this layer, likely due to the weight gain recorded at the end of the treatment (Figure 2).

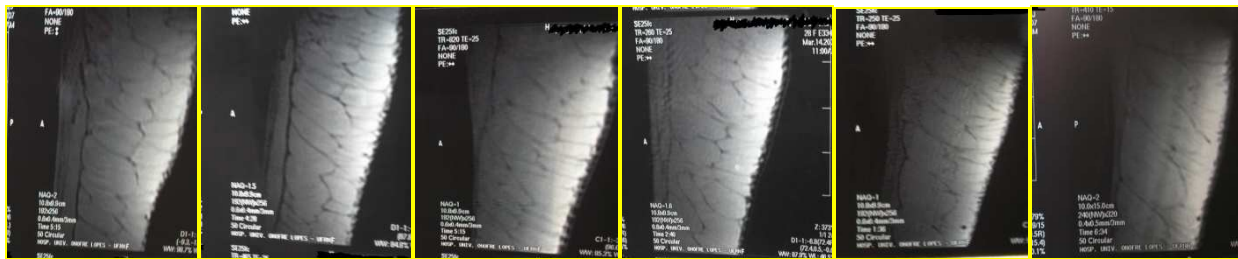

Figure 2 - Sagittal plane T1-weighted pre and post-treatment images of patients 1, 2 and 3.

3. Patient 1 displayed a less wavy skin contour in the post-treatment examination. Lymphatic drainage promoted the removal of excess liquid present in the interstitial spaces, contributing to an improvement in the fibrosis process, which, according to Lucassen et al. (1997), accounts for the wrinkly appearance of skin. The improved appearance of skin contour associated to this

aspect, especially with this patient, may have been due to the fact that she had the lowest BMI at the end of the treatment, a result which corroborates Smalls et al. (2006), who analyzed the effect of weight loss on cellulitis. In this study, weight loss improved the cellulitic aspect of the skin in most patients (Figure 3).

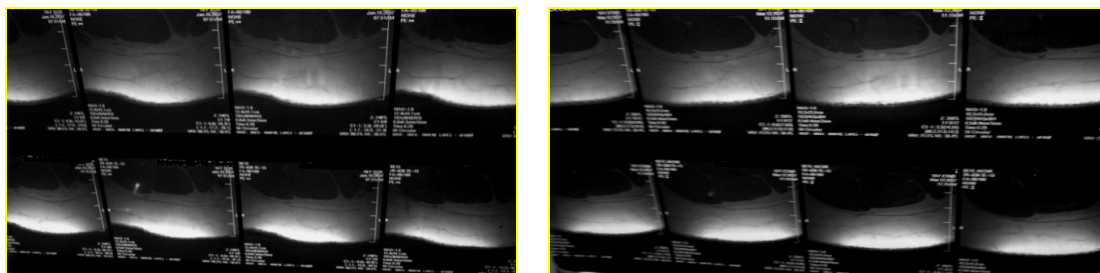


Figure 3: Axial plane T1-weighted pre and post-treatment images of patient 1.

4. Patients 2 and 3 showed fewer signs of subdermal vascular structures in the post-treatment examination than in the pre-treatment examination, suggesting reduced venous ingurgitation, this being more apparent in patient

3. There were no significant vascular alterations in patient 1. This finding is likely due to the fact that patients 2 and 3 presented with microcirculatory disturbances (micro varicose veins) (Figure 4

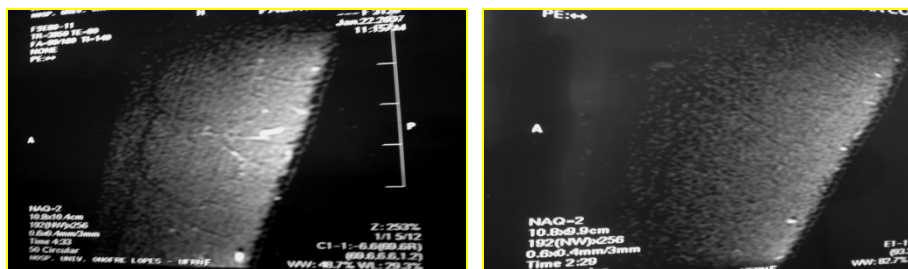


Figure 4 - Sagittal plane T2-weighted pre and post-treatment image of patient 3.

The magnetic resonance examination enabled a more accurate assessment of the subcutaneous tissue of patients submitted to manual lymphatic drainage therapy to treat cellulitis. The advantage of this method over others, such as ultrasonography, resides in the possibility of visualizing the architecture of the dermal and epidermal layers without danger of operator error. Moreover, MR enables the visualization of tissue liquids (in the T2 sequence), rendering it a more reliable objective cellulitis assessment instrument.

RESUMO

Objetivo: Este estudo objetiva avaliar o uso da Ressonância Magnética como uma nova técnica de avaliação de uma técnica de drenagem linfática no tratamento do Fibro Edema Gelóide (FEG). O FEG, popularmente conhecido como “celulite” é um dos principais problemas de estética corporal que leva as mulheres a procurar orientações e tratamentos específicos. Devido à natureza multifatorial da sua patogenia, existem várias abordagens terapêuticas, mas a maioria desses não tem sua eficácia comprovada de maneira acurada, pois os métodos de avaliação utilizados, em sua maioria, são subjetivos ou não provêm informações suficientes para o estudo do tecido subcutâneo. A introdução da ressonância magnética como meio de avaliação de uma técnica de drenagem linfática no tratamento do FEG a torna mais acurada, uma vez que a mesma possibilita o estudo detalhado da arquitetura do subcutâneo.

REFERENCES

- Avram M.M., David G. (2004), Cellulite: a review of its physiology and treatment. *J Cosmet Laser Ther.*, **6**, 181-185.
- Brandi C., D’Aniello C., Grimaldi L., Bosi B., Dei I., Lattarulo P. (2001), Carbon Dioxide Therapy in the Treatment of Localized Adiposities: Clinical Study and Histopathological Correlations. *Aesth Plast Surg.*, **25**, 170-174.
- Gensanne, D.; Josse, G.; Lagarde, J. M.; Vincensini, D. (2006), High spatial resolution quantitative MR images: an experimental study of dedicated surface coils. *Phys Med Biol.*, **51**, 2843-2855.
- Hexsel, D. M.; Mazzuco, R. (2000), Subcision: a treatment for cellulite. *Int J Dermatol.*, **39**, 539-544.
- Lucassen, G. W.; Van der Sluys, W. L. N.; Van Herk, J. J.; Nuijs, A. M.; Wierenga, P. E.; Barej, A. O. (1997), The effectiveness of massage treatment on cellulite as monitored by ultrasound imaging. *Skin Res Technol.*, **3**, 154-160.
- Mirashed, F.; Sharp, J. C.; Krause, V.; Morgan, J.; Tomanek, B. (2006), Pilot study of dermal and subcutaneous fat structures by MRI in individuals who differ in gender, BMI, and cellulite grading. *Int J Cosmet Sci.*, **28**, 207.
- Piérard GE, Nizet JL, Piérard-Franchimont. (2000), Cellulite: From Standing Fat Herniation to Hypodermal Stretch Marks. *Am J Dermatopa.*, **22**, 34-37.
- Rosenbaum, M.; Prieto, V.; Hellmer, J.; Boschmann, M.; Krueger, J.; Leibel, R. L.; (1998), An Exploratory Investigation of the Morphology and Biochemistry of Cellulite. *Am Soc Plast Surg.*, **101**, 1934-1939.
- Rossi, A. B. R.; Vergnanini, A. L. (2000), Cellulite: A review. *J Eur Acad Dermatol Venereol.*, **14**, 251-262.
- Smalls, L. K.; Hicks, M. P. D.; Gersin, K.; Kitzmiller, W. J.; Bakhsh, A.; Wickett, R. R. (2006), Effect of Weight Loss on Cellulite: Gynoid Lypodystrophy. *Am Soc Plast Surg.*, **118**, 510-516.

Received: August 21, 2008;
Revised: September 15, 2008;
Accepted: September 17, 2008