

Article - Human and Animal Health

Fertility Enhancing Potency of Omega-3 Fatty Acids in Male Rats

Emmanuel Ikechukwu Nnamonu¹
<https://orcid.org/0000-0002-6864-8618>

Bernard Obialor Mgbenka²
<https://orcid.org/0000-0001-8573-887X>

Edmund Chidiebere Mbegbu³
<https://orcid.org/0000-0002-0513-6818>

¹Federal College of Education, Eha-Amufu, School of Sciences, Department of Biology, Enugu State, Nigeria; ²University of Nigeria, Nsukka, Faculty of Biological Sciences, Department of Zoology and Environmental Biology, Enugu State, Nigeria; ³University of Nigeria, Nsukka, Faculty of Veterinary Sciences, Department of Veterinary Physiology and Pharmacology, Enugu State, Nigeria.

Received: 2018.07.20; Accepted: 2019.07.21.

*Correspondence: edmund.mbegbu@unn.ed.ng; Tel.: +234-8060144975 (M.E.C.); nnamonue@gmail.com; Tel.: +234-8064855635 (N.E.I.).

HIGHLIGHTS

- Omega-3 fatty acids significantly increased testicular weights in rats.
- It significantly increased testicular and epididymis sperm cells counts.
- It maintained normal spermatogonial cell layers and induced active spermatogenesis in the lumen of tubules.
- It improved testicular histoarchitecture.

Abstract: Cases of some grave side effects of some allopathic medicines used in treatment of infertility has caused a global need for alternatives with minimal or no side effect, hence the demand to evaluate the fertility enhancing potential of omega-3 fatty acids (O3FA) in male rats. This study evaluated the fertility enhancing potential of omega-3 fatty acids (O3FA) in male rats. Seventy-two sexually mature male albino rats 11-13 weeks of age, weighing between 171 – 180 g were assigned into six groups (I – VI) fed graded doses of O3FA. Administration of O3FA lasted twenty-eight days at 48 hour intervals. At the end of the treatment, organosomatic index of testes, testicular and epididymis sperm cells counts and testicular histology were assessed following standard methods. The actual and relative testicular weights, testicular and epididymis sperm counts of all O3FA treated rats were significantly increased ($p < 0.05$) when compared with the control group rats. The photomicrographs of testes in O3FA treated rats showed normal spermatogonial cell layers and active spermatogenesis with appearance of spermatids in the lumen of some tubules.

The findings of this study depicts that O3FA possesses the potency of enhancing various fertility indices in male rats with regards to absolute and relative testicular weights as well as sperm counts.

Keywords: omega-3 fatty acids; fertility; histology; potency; male rat.

INTRODUCTION

Fertility is the latent ability of an organism to reproduce itself while infertility is the incapability to conceive and carry a pregnancy to live birth. It is a worldwide medical and social problem that affects above 10-15% of married couples [1]. The vertebrate reproductive cycle depends upon delicate interrelationships between the sex hormones and the pituitary gonadotropic hormones [2].

Male infertility is the male's incapability to cause pregnancy in a fertile female. It occurs due to some disorders such as hormonal disturbances, low sperm production, poor sperm quality and abnormal sperm function and others. Semen quality is used as an alternative measure of male fecundity [3].

Researches have proven that certain nutrients can completely reverse infertility [4-5]. Allopathic medicines have proved to be the best in treating infertility cases but have shown some grave side effects involving various vital organs of the body. Therefore, there is a pressing need globally for alternatives with minimal or no side effect, hence the demand to evaluate the potency of O3FA acids on male fertility. An understanding of the potency of O3FA on the physiology of reproduction could be a suitable approach to handling reproductive disorders that would not hinge on the use of allopathic medicine nor exogenous hormones. More so, there is dearth of literature on the fertility effect of O3FA hence the justification of this study.

Omega -3 fatty acids are a group of polyunsaturated fats found naturally in a wide variety of foods and are unconditionally essential for many physiological processes, including growth, vision, brain development, maintaining health through life, reproduction and early foetal development [6].

Owing to the severally proven benefits of omega-3 fatty acids to human health and reproduction, this study evaluated its potency of enhancing male fertility.

MATERIAL AND METHODS

Omega 3 fatty acid (91%) was purchased from Prevention Pharmaceuticals, Lambertville, Michigan, USA. Other drugs were purchased from reputable pharmaceutical shops.

Procurement and management of experimental animals

Seventy-two adult male albino rats (with no history of prior use in any investigation) were obtained from the Genetics and Experimental Animal Breeding Laboratory of the Department of Zoology and Environmental Biology, University of Nigeria, Nsukka. The ethical conditions and experimental protocol governing the use and conduct of experiments with live animals were strictly observed as approved by the University of Nigeria, Nsukka Senate Committee on Medical and Research ethics. The animals were hygienically housed in stainless wire rat cages furnished with drinkers and faecal gathering trays, fed with commercial growers' mash (Vital Feeds, Grand Cereals Limited, Jos, Nigeria) and clean tap water. The animals were allowed to acclimatize for two weeks before being used for the experiment.

Experimental design

Seventy-two adult male albino rats were assigned into six groups I – VI. Rats in various groups were treated as follow: I received 0.3 ml distilled water + 0.3 ml tween 80 (placebo), II rats received 150 mg/kg O3FA, III rats received 250 mg/kg O3FA, IV were treated with 12.5 mg/kg mesterolene, V rats received 25 mg/kg CPP while VI rats were administered 25 mg/kg CPP + 250 mg/kg O3FA. Administration of O3FA was for twenty-eight days at 48h intervals.

Organosomatic index of testes

At day twenty-eight of the experiment the testes from some randomly selected rats at various treatment groups were harvested, freed from adherent tissues and blood, and weighed to the nearest milligram. The organ weights were reported as relative weights using this formula: organ weight / body weight $\times 100$ [7].

Determination of testicular and epididymis sperm counts

The epididymis and the testes from some randomly selected male rats were harvested, weighed and crushed differently in different mortars to release the sperm cells. The sperm cells were counted using haemocytometer following the method described by [8].

Histological studies

Tissues samples of testes from the various groups of rats were fixed in 10% formol saline and dehydrated in ascending grades of ethanol. Thereafter, sections were prepared for light microscopy as described by [9].

Statistical analysis

One-way analysis of variance (ANOVA) was carried out on the data using the IBM Statistics UK (version 20.0). The means were separated using Duncan's new multiple range test while differences in the means were considered significant at probability values less than 5 % ($p < 0.05$). The results were presented as mean \pm SEM.

RESULTS AND DISCUSSION

Effects of O3FA on organosomatic index, testicular whole weight and relative weight

The actual and relative testicular weights of the rats were shown in Table 1. The actual and relative testicular weights of all treated groups were significantly higher ($p < 0.05$) than the control group except for 12.5 mg/kg mesterolene-treated group which showed no significant difference ($p > 0.05$) compared with control (Table 1).

Table 1. Effect of omega-3 fatty acids on organosomatic index (relative weight) of testes.

Groups	Treatment	Testis weight (g)	Testis relative weight (%)
I	Placebo	1.57 ± 0.14 ^a	0.93 ± 0.04 ^a
II	150 mg/kg O3FA	2.58 ± 0.27 ^c	1.23 ± 0.08 ^b
III	250 mg/kg O3FA	2.87 ± 0.42 ^c	1.41 ± 0.18 ^b
IV	12.5 mg/kg mesterolene	1.78 ± 0.13 ^{ab}	0.87 ± 0.06 ^a
V	25 mg/kg CPP	2.31 ± 0.12 ^{bc}	1.77 ± 0.05 ^c
VI	25 mg/kg CPP + 250 mg/kg O3FA	2.50 ± 0.16 ^c	1.79 ± 0.05 ^c

Organosomatic indices (organs to body weight ratio) gives information on harmful effect of chemicals in organism, alterations in nutritional and energy status [10-12]. The observed significant increase ($p < 0.05$) in testes relative weight of the O3FA-treated rat's consonants with the result of [13], who explained that increase in the mean testicular weight of the treated rats could be due to the increased activity in their testes, which may include increased testosterone secretions [13]. Thus, the non-significant increase in testes relative weight of CPP + O3FA treated rats observed in this study indicate an increase in testicular activity caused by O3FA. Sperm number and normal testicular histology are indices of fertility [13].

Effects of O3FA on testicular and epididymal sperm counts

There was a significant increase ($p < 0.05$) in testicular and epididymal sperm counts of O3FA-treated rats compared with control. The O3FA-treated (groups B and C) rats showed the highest testicular and epididymal sperm counts which were significantly higher ($p < 0.05$) than the control. On the other hand, the least testicular and epididymal sperm counts were observed in 12.5 mg/kg mesterolene and 25 mg/kg CPP (negative control) groups while the rats treated with 25 mg/kg CPP + 250 mg/kg O3FA showed an improvement in sperm counts than those that received 25 mg/kg CPP only (Table 2).

Table 2. Effect of omega-3 fatty acids on testicular and epididymis sperm counts.

Groups	Treatment	Testicular sperm count ($\times 10^6$ sperm /mL)	Epididymal sperm count ($\times 10^6$ sperm /mL)
I	Placebo	35.78 \pm 1.00 ^c	73.68 \pm 1.49 ^c
II	150 mg/kg O3FA	46.17 \pm 1.47 ^d	86.25 \pm 1.34 ^d
III	250 mg/kg O3FA	57.76 \pm 1.41 ^e	109.06 \pm 2.73 ^e
IV	12.5 mg/kg mesterolene	3.39 \pm 0.26 ^a	13.25 \pm 0.24 ^a
V	25 mg/kg CPP	4.42 \pm 0.24 ^a	10.64 \pm 0.71 ^a
VI	25 mg/kg CPP + 250 mg/kg O3FA	28.28 \pm 0.75 ^b	42.13 \pm 0.61 ^b

The observed significant increase ($p < 0.05$) in testicular and epididymis sperm counts of O3FA-treated rats confirm profertility property of O3FA. [14] Explained that observed increase in sperm counts of treated rats was caused by an increased production of testosterone and probably follicle-stimulating hormone (FSH) inclusive. Similarly, the observed increase in sperm counts of the rats that received CPP + O3FA as compared with the rats treated CPP only could be ascribed to a possible antioxidant and free radical scavenger ability of O3FA.

Effects of O3FA on histology of testes

Photomicrographs of testes (Figure 1) of rats in group A showed intact seminiferous tubules (st) containing sperm cells at various stages of development and Leydig cells in the interstitium (arrows) with no visible histologic abnormality. Groups B (150 mg/kg O3FA), C (250 mg/kg O3FA) and D (12.5 mg/kg mesterolene) showed normal spermatogonial cell layers (white arrows) and active spermatogenesis with appearance of spermatids in the lumen of some tubules (black arrows) which were more in B with the visible nuclear details. Group E (25 mg/kg CPP) showed disorganization of the spermatogonial cell layers with degenerative and necrotic changes of all cell types (arrows) and reduced presence of cells in the lumen of seminiferous tubules. Group F (25 mg/kg CPP + 250 mg/kg O3FA) showed karyorhexis of spermatogonial cells although there were sperm cells in the lumen of seminiferous tubules. The photomicrographs of the testis from group E rats showed severe depletion of the seminiferous germ cells. However, treatment with O3FA ameliorated this effect in the group F rats. Spermatogenic cells were observed sloughing into the lumen in groups E and F with more severity in E. Similarly, atrophy of seminiferous tubules occurred in groups E and F with more severity in group E (Figure 1).

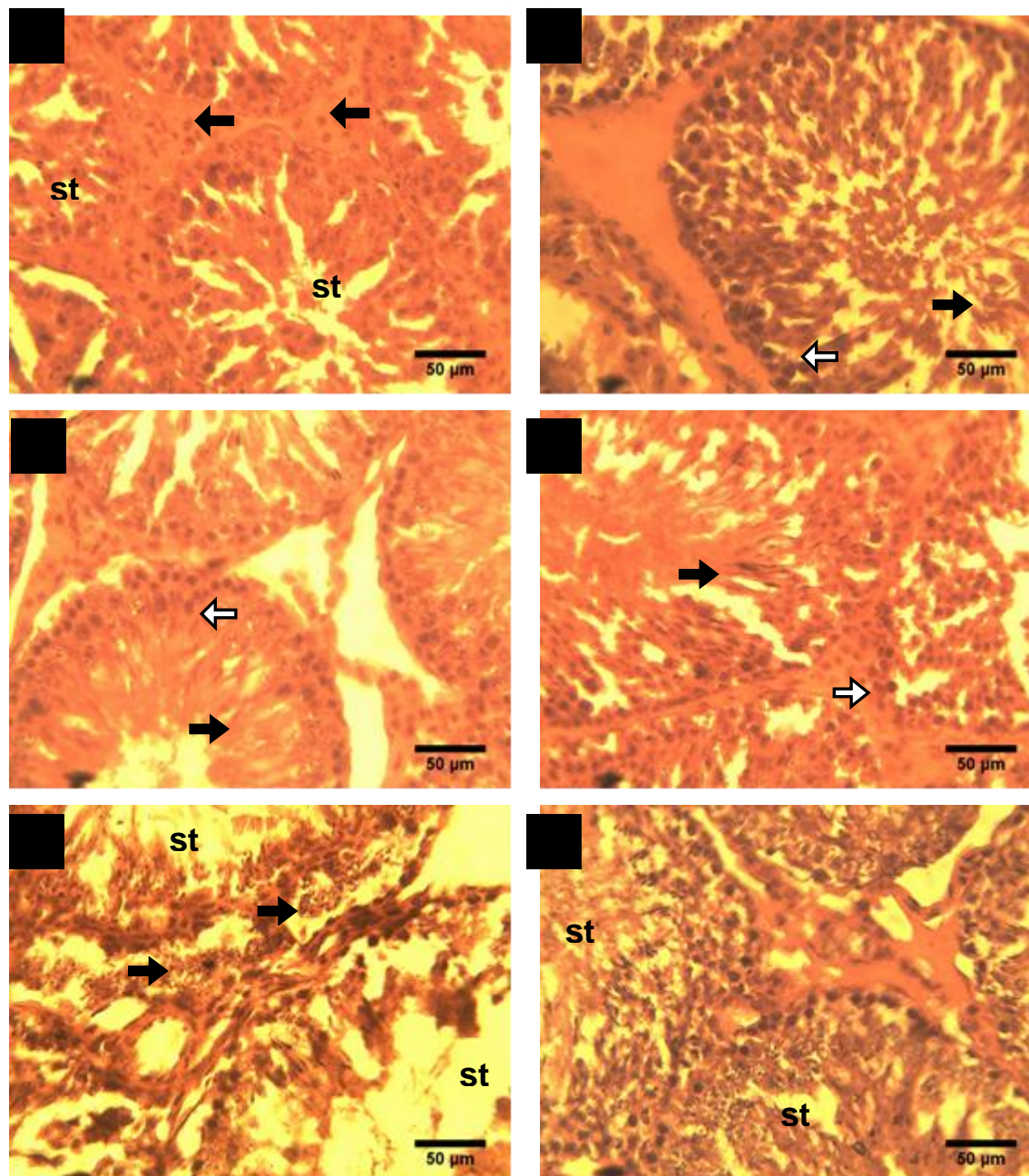


Figure 1. Photomicrographs of the testes of experimental animals

A = Placebo; B = 150 mg/kg O3FA; C = 250 mg/kg O3FA; D = 12.5 mg/kg mesterolene; E = 25 mg/kg CPP; F = 25 mg/kg CPP + 250 mg/kg O3FA; st = seminiferous tubules

Histological studies revealed the pathological status of various body tissues and organs. The observed normal spermatogonial cell layers and active spermatogenesis in O3FA treated rats which were more in 150 mg/kg O3FA shows that it has the ability of improving the histoarchitecture of the gonads in mammals. The photomicrograph of the group administered CPP + O3FA showed reduction in severity of the adverse effects caused by CPP treatment namely reduction in missing germ cell layers and reduction in atrophy of seminiferous tubules, further confirms the observed increase in sperm count at the group.

CONCLUSIONS

The findings of this study reveals that O3FA possesses the potency of enhancing various fertility indices in male rats with regards to testes whole and relative weights and sperm counts. It can also improve testicular histoarchitecture and function.

Conflict of interest disclosure: There is no conflict of interest among the authors.

Acknowledgement: Our sincere appreciation goes to Mr. and Mrs. Philip Nnamonu who financed this study.

REFERENCES

1. Bonanomi M, Lucente G, Selvstrini B. Male fertility: core chemical structure in pharmacological research. *Contraception*. 2002;65(4):317-20.
2. Nagabhashanam R, Kodarkar MS, Sarojini R. *Animal Physiology*. 2nd ed. New Delhi: Oxford & IBH Publishing Company Pvt. Limited; 2005.
3. Cooper TG, Noonan E, Von Eckardstein S, Auger J, Baker HW, Behre HM, Haugen TB, Kruger T, Wang C. World Health Organization reference values for human semen characteristics. *Hum Reprod*. 2009;16(3):231–45.
4. Zini A, San GM, Baazeem A. Antioxidants and sperm DNA damage: a clinical perspective. *J Assist Reprod Genet*. 2009;26(8):427-32.
5. Ibrahim HA, Zhu Y, Wu C, Lu C, Ezekwe MO, Liao SF, Liao SF, Huang K. Selenium-enriched probiotics improves murine male fertility compromised by high fat diet. *Biol Trace Elem Res*. 2012;147(1-3):251-60.
6. Fischer S. Dietary polyunsaturated fatty acids and eicosanoid formation in humans. *Adv Lipid Res*. 1989;23:169-98.
7. Tatli-Cankaya I, Alqasoumi SI, Abdel-Rahman RF, Yusufoglu H, Arabcianul S, Akaydin G, Soliman GA. Evaluating the antifertility potential of the ethanolic extracts of *Bupleurum sulphureum* and *Cichorium intybus* in male rats. *AJPCR*. 2014;7(1):211-8.
8. Almquist JO, Amann RP. Reproductive capacity of dairy bulls. II. Gonadal and extral-gonadal sperm reserves as determined by direct counts and depletion trials; dimensions and weight of genitalia. *J Dairy Sci*. 1961;44(9):1668-78.
9. Bancroft JD, Stevens A. *Theory and Practice of Histological Techniques*. Edinburgh: Churchill Livingstone; 1977.
10. Ronald WG, Bruce AB. Organosomic indices and an autopsy-based assessment as indicators of health condition of fish. *Am Fish Soc*. 1990;8:93-108.
11. Maxwell LB, Dutta HM. Diacinon induced endocrine disruption in sole gill sun fish *Lepomis macrochirus*. *Ecotoxicol Environ Saf*. 2005;60:21-7.
12. Di Giulio RT, Hinton DE. *The toxicology of fishes*. Boca Raton: CRC Press, Taylor and Francis Group; 2008. 1071 p.
13. Ekere SO, Okoye CN, Udoumoh AF. Fertility enhancing effects of methanolic leaf extract of *Dracaena arborea* in albino rats (*Rattus norvegicus*). *Czech J Anim Sci*. 2013;58(11):520–4.
14. Al-Sa'aidi JAA, Al-Khuzai ALD, Al-Zobaydi NFH. Effect of alcoholic extract of *Nigella sativa* on fertility in male rats. *Iraqi J Vet Sci*. 2009;23(11):123–8.



© 2018 by the authors. Submitted for possible open access publication under the terms and conditions of the Creative Commons Attribution (CC BY NC) license (<https://creativecommons.org/licenses/by-nc/4.0/>).