

Effect of Zoledronic Acid Used in the Root Surface Treatment of Late Replanted Teeth: A Study in Rats

Graziela Garrido MORI
Daniela Maria de Mendonça JANJACOMO
Daniele Clapes NUNES
Lithiene Ribeiro CASTILHO

*Postgraduate Program in Dentistry, Integrated Clinic Area, Araçatuba Dental School,
São Paulo State University, Araçatuba, SP, Brazil*

This study evaluated the use of zoledronic acid, a resorption inhibitor, as a medication for root resorption treatment of late replanted teeth. Twenty-four maxillary right central incisors of rats were avulsed and kept dry for 30 min. Then, the teeth were divided into 2 groups. In group I, root surface was treated with 2% sodium fluoride for 20 min; in group II, 10^{-6} M zoledronic acid solution was used for 20 min. All root canals were filled with calcium hydroxide. Next, teeth were replanted in their respective sockets. After 15 and 60 days post-replantation, the animals were killed and the anatomic pieces were obtained and prepared for microscopic and morphometric analyses. The results showed that zoledronic acid was capable of limiting the occurrence of root resorption and preserving cementum resorption. Further research must be performed to confirm the use of zoledronic acid in root surface treatment of late replanted teeth.

Key Words: zoledronic acid, root resorption, tooth replantation.

INTRODUCTION

Tooth avulsion, characterized by the complete displacement of the teeth from its alveolus, accounts for nearly 0.5 to 16% of dental trauma (1). During tooth avulsion, several tissues may be affected or damaged, including: periodontal ligament, alveolar bone, gingiva, lips, and dental pulp (1). The periodontal ligament is disrupted, disorganizing its orientation and compromising its viability (1,2). The vascular-nervous bundle that supplies dental pulp is also disrupted, leading to its necrosis (1). These aspects have characterized dental avulsion as a complex traumatic lesion of difficult treatment (2).

Once avulsed, the tooth must be replanted in its socket, in an attempt to reestablish its normality (1). To achieve tooth replantation success, it is fundamental to maintain the vitality of the cells over the root (1). Hence, either immediate replantation (1), performed within 15 min after avulsion, or storage of avulsed teeth in compatible media for the survival of those cells before replantation (1), is an imperative procedure.

Studies performed in different countries reveal the population's lack of information how to proceed in cases of dental avulsion (3,4). Thus, instead of accomplishing either immediate replantation or storing the tooth in an appropriate media, people usually keep an avulsed tooth exposed to the dry environment, either wrapping it in plastic or paper, or storing it in solutions incompatible with the survival of the cells on root surface. This may lead to the development of ankylosis and root resorption, which can be undesirable consequences of tooth replantation (1,2).

In an attempt to inhibit or limit root resorption and promote the repair of the area in cases of late replantation, the tooth should be submitted to both root surface treatment and endodontic therapy (1,2,5-7). Root surface treatment is one of the main methods of root decontamination. This can be mechanically performed (8), but carefully, since the cementum should not be removed. In addition to being more resistant to resorption, cementum does not allow bacterial toxins to penetrate deeply (9), thus the cleanness should be superficial. After this initial cleanness, the tooth should

be immersed in sodium fluoride solution because this, in addition to strengthening the dental structure by forming fluorapatite, is still toxic for the resorptive cells of the hard tissue (2,6,10,11). The intracanal dressing of choice is calcium hydroxide (9,12), due to its antimicrobial and anti-resorptive characteristics.

Nevertheless, despite these treatments, unsuccessful cases are still numerous, and after a mean period of 4 to 6 years, the teeth are ultimately lost (13). Thus, the search for new substances that may inhibit or delay the effects of root resorption and promote the repair in the space occupied by the periodontal ligament is essential.

Due to the similarity among the morphology, enzymatic properties and function of the cells that reabsorbs bone, dentin, and cementum, both root and bone resorption processes can be considered similar (2). Therefore, drugs and other substances used for inhibiting bone resorption may also be effective for the root resorption treatment.

Currently, biphosphonates have been the most important drugs for bone resorption treatment (2,14-20). The main mechanisms of action of the drugs have been: drug interference on clastic cells action, apoptosis of these cells, stimulation of blastic cells proliferation or associations of these aforementioned actions (2,14,16-19).

These drugs incorporate into the mineralized tissues and become available in these tissues for long periods (15,18). Because of this, they show either an immediate or late effect. This explains why these drugs have been successfully used in conditions as: osteoporosis, cancer, hipercalcemia, tumor-induced osteolysis, or Paget's disease in bone (2,14,19,20). Liberman et al. (20), in 1995, demonstrated that the prolonged administration of biphosphonates in patients with osteoporosis reduced the rate of vertebral fracture by half.

Among the several types of biphosphonates, it has currently been highlighted the zoledronic acid (16,19). According to several studies, zoledronic acid can be considered the most potent inhibitor of bone resorption, when compared with other biphosphonates (16,17,19). Furthermore, according to Schindeler and Little (17), zoledronic acid does not act on further cells of the body, having its action potential only on clasts. According to Deeks and Perry (19), zoledronic acid when incorporated into the mineralized tissues, it increases the tissues density and turns them more resistant to fractures. The authors also reported that zoledronic acid is well

tolerated by the body.

Based on the aspects presented, the purpose of this study was to evaluate the effect of zoledronic acid solution when applied for root surface treatment of teeth submitted to late replantation.

MATERIAL AND METHODS

The study was conducted on 24 male Wistar rats (*Rattus norvegicus, albinus*) weighing approximately 250-300 g. All experimental procedures were approved by the Animal Research Ethics Committee of Araçatuba Dental School, São Paulo State University, Brazil. (Process number 2008-001854). The animals were kept in cages identified according to the group and study periods. The cages were cleaned daily. The animals received a grained solid food before and during the study, except for 12 h before and after surgery, and water *ad libitum*.

For surgical interventions, the animals were anesthetized with a mixture of ketamine (Dopalen; Sespo Indústria e Comércio Ltda, Jacareí, SP, Brazil) and xylazine (Anasedan; Agribrands do Brasil Ltda, Paulínia, SP, Brazil), to intramuscular, in a dose of 0.05 mL/100g of weight for each substance. Anesthesia was applied with disposable insulin syringes. Asepsis of the anterior portion of the maxilla was performed with a 0.12% chlorhexidine gluconate solution (Periogard; Colgate-Palmolive Indústria Brasileira, São Bernardo, SP, Brazil). In addition, extraction of the maxillary right central incisor was done, simulating a case of tooth avulsion.

The extracted teeth were kept dry, attached by the crown to a sheet of pink wax for 30 min. The dental papillae of the teeth was excised with a #11 surgical blade for exposure of root canals. The pulp was removed via apical foramen, with a slightly curved #15 Flexofile (Dentsply/Maillefer, Ballaigues, Switzerland). Root canal instrumentation was completed using #20 and #25 Flexofiles. Canals were copiously irrigated with a 1% sodium hypochlorite solution (Probem Produtos Farmacêuticos e Odontológicos Ltda, Catanduva, SP, Brazil) using a Luer Look syringe and a 30x4 gauge needle. The necrotic periodontal ligament present in root was removed with a #11 surgical blade.

After preparation, teeth were washed with sterile saline and divided in 2 groups. In group I (n=12), teeth were immersed in 20 mL of 2% sodium fluoride solution (pH 5.5) (Aphoticário Farmácia de Manipulação,

Araçatuba, SP, Brazil) for 20 min. In group II (n=12), teeth were immersed in 10 mL of 10^{-6} M zoledronic acid (Novartis Finland Ltda, Taboão da Serra, SP, Brazil) for 20 min.

Root canals were further irrigated with sterile saline and filled with EDTA (Odahcam; Dentsply Indústria e Comércio Ltda, Petrópolis, RJ, Brazil) for 3 min and washed with sterile saline again. Aspiration was done with a 30x4 gauge needle attached to a Luer Lock syringe, and all root canals were dried with sterile absorbent paper points (Tanariman Industrial Ltda, Manacapuru, AM, Brazil), and filled with calcium hydroxide paste (S.S. White Artigos Dentários Ltda, Rio de Janeiro, RJ, Brazil).

Replantation procedures followed with each tooth in its respective socket. No retention was placed (2). The animals received a single dose of 20,000 IU of benzatine G penicillin (Eurofarma Laboratórios Ltda, Itapevi, SP, Brasil), via intramuscular injection.

Five animals of each group were killed at 15 and 60 days after replantation with an anesthetic overdose. The right side of the maxilla was separated from the left in the median line with a #15 surgical blade (Embramac Importação e Exportação, Ribeirão Preto, SP, Brazil). The maxilla was further cut nearby the third molar in order to loosen the hemi-maxilla containing the replanted tooth.

The specimens were fixed in 10% buffered formalin (Merck, São Paulo, SP, Brazil) for 7 days and decalcified in 4.13% EDTA (pH 7) (Titriplex III; Merck (108418)). The specimens were then processed and embedded in paraffin to show transversal cuts of the cervical, middle and apical thirds of the tooth. Sections of 5 μ m were taken at each 50 μ m with a microtome, totaling 20 sections for each specimen. The sections were stained by hematoxylin-eosin.

For microscopic analysis, the following parameters were considered: integrity of dental structure, presence of cementum, characteristics of the connective tissue formed in the periodontal space (parallel or perpendicular), presence of dental ankylosis (union of the root and bone, with absence of connective tissue between those) and occurrence of lacunae of inflammatory resorption or lacunae of replacement resorption (substitution of the tooth for bone).

In addition, morphometric analysis was also performed using the ImageJ software, which is specific for measuring areas and perimeters. Fifteen histological sections of each study period were photographed with

a digital camera (Canon, Tokyo, Japan) attached to a microscope (Carl Zeiss; AxioLab, Jena, Germany) connected to a PC computer. The images were stored as figures (TIFF files) for analysis using the ImageJ software. The perimeter of areas showing ankylosis, connective tissue formed in the periodontal space, amount of remaining cementum, and the areas of inflammatory or replacement resorption were measured.

Microscopic and morphometric analyses were assigned by a blinded, experienced examiner. The identification of the histological sections was occulted and the results recorded on specific tables. Statistical analyses of the results were carried out using Kruskal-Wallis test at a significance level set at 5%.

RESULTS

15 Days

In group I, it could be verified the formation of a dense connective tissue with few inflammatory cells. In several specimens, this tissue was disposed perpendicular to the root surface (57.15%) (Fig. 1). The tissue was parallel in 28.73% of the cases (Table 1). The histological sections of group II showed the formation of a dense connective tissue, with some areas of blood clot and few inflammatory cells. The tissue was disposed parallel to root surface in 33.44% of the cases. In 43.73% of the specimens analyzed in group II, the connective tissue was disposed perpendicular to the root, similarly

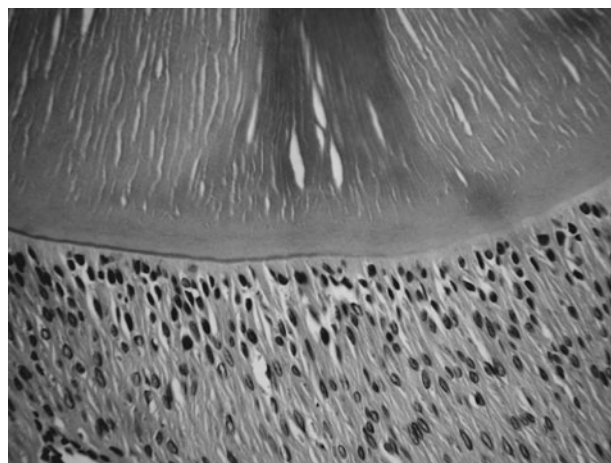


Figure 1. Group I (sodium fluoride), 15 days: integrity of dental structure and presence of connective tissue perpendicular to the root. Original magnification 40 \times .

to periodontal ligament (Fig. 2).

Ankylosis, characterized by the union between the hard tissue and the tooth, was present, in 14.12% of the specimens in group I and 22.83% in group II (Table 1).

Cementum covering the root was present in 90.94% in group I and 92.71% in group II. Because of this, few root resorption lacunae were observed in both experimental groups (Table 1) (Figs. 1 and 2).

60 Days

In group I, it was noted an insignificant presence of perpendicular tissue (4.34%). The connective tissue

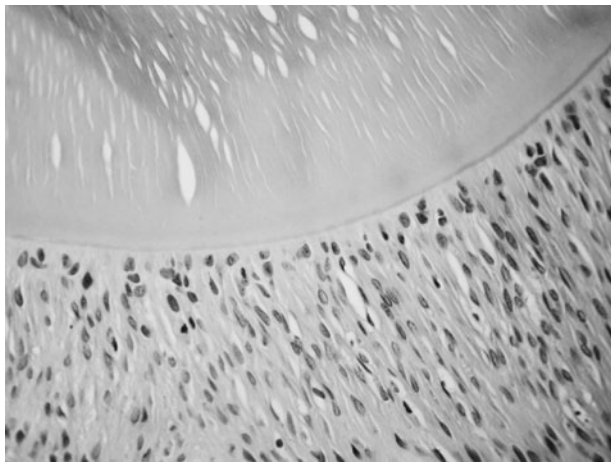


Figure 2. Group II (zoledronic acid), 15 days: integrity of dental structure and presence of connective tissue perpendicular to the root. Original magnification 40x.

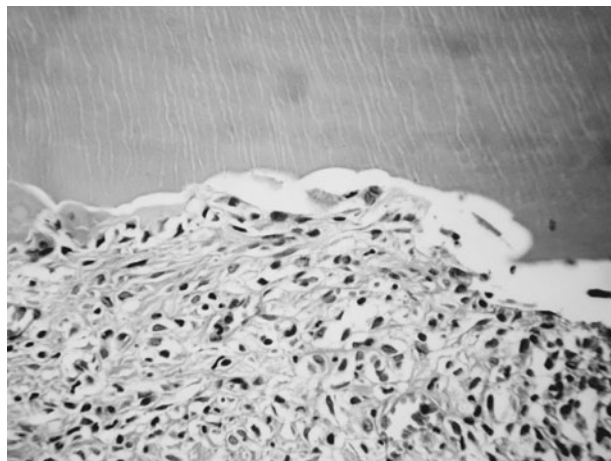


Figure 3. Group I (sodium fluoride), 60 days: presence of connective tissue parallel to the root and lacunae of inflammatory resorption. Original magnification 40x.

was disposed parallel to root surface was constant along time (Fig. 3). In group II, it could be observed a great decrease in the amount of connective tissue similar to periodontal ligament, since this type of tissue was present in only 3.87% of the cases (Table 1) ($p < 0.05$) and the connective tissue parallel to the root (Fig. 4) remained constant (Table 1). Ankylosis significantly increased, along time, in group I and II (Table 1) ($p < 0.05$).

Cementum covering the root was significantly

Table 1. Mean percent values of the occurrence of histological events for each experimental period in Group I (sodium fluoride) and Group II (zoledronic acid).

Histologic events	Group I		Group II	
	15 d	60 d	15 d	60 d
Inflammatory resorption	0.65 ^a	5.12 ^b	0.13 ^a	0.02 ^a
Replacement resorption	0.04 ^a	5.16 ^{b,c}	0.14 ^{a,d}	0.04 ^a
Presence of cementum	90.94 ^a	54.04 ^b	92.72 ^a	95.37 ^a
Ankylosis	14.12 ^a	57.71 ^b	22.83 ^a	56.77 ^b
Connective tissue parallel	28.73	37.95	33.44	39.36
Connective tissue perpendicular	57.15 ^a	4.34 ^{b,c}	43.73 ^{a,d}	3.87 ^{b,c}

^a with statistically significant difference from ^b ($p < 0.05$). ^c with statistically significant difference from ^d ($p < 0.05$).

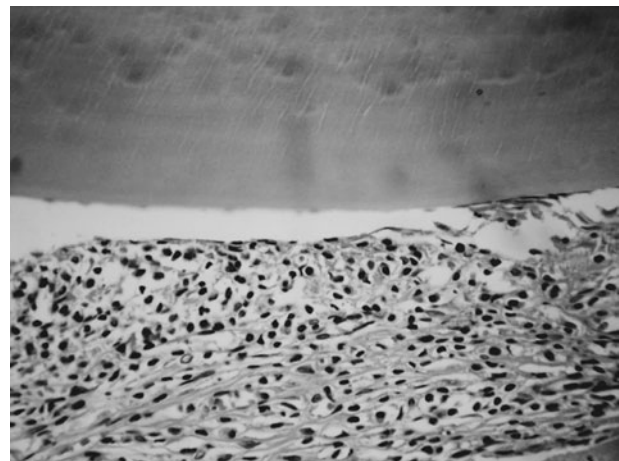


Figure 4. Group II (zoledronic acid), 60 days: integrity of dental structure and presence of connective tissue parallel to the root. Original magnification 40x.

smaller in group I, as seen in Table 1 ($p < 0.05$). In group II, the cement was constant at 60 days (Table 1).

Inflammatory resorption lacunae were present in 5.12% in group I (Fig. 3) ($p < 0.05$). In some cases, resorption lacunae were huge, communicating the periodontal region to root canal (communicating resorption). In group II, the inflammatory resorption lacunae was insignificant (0.02%).

Replacement resorption lacunae were significantly greater in group I (Table 1) ($p < 0.05$). The lacunae, in group I, were seen in 5.12% of specimens. It shows that the amount and size of the root resorption were greater at 60 days in group I ($p < 0.05$). Replacement resorption lacunae were also insignificant in group II (Fig. 4) (0.04%).

DISCUSSION

Root resorption occurrence in the experimental groups of this study was low. This emphasizes the zoledronic acid (14-20) and sodium fluoride (10,11) characteristics in limiting the resorptive process.

The zoledronic acid superiority in inhibiting root resorption, when compared to sodium fluoride can be seen in data present in Table 1. At 15 days, both substances tested were effective and similar; however, zoledronic acid was more effective, in the long term. It can be noted that in group I, at 60 days, the root resorption presence was insignificant (0.02% to 0.04% of occurrence).

The minimum occurrence of root resorption in the group I specimens can be explained by the action mechanism of zoledronic acid (14,16,17,19,20). This drug incorporates into the mineralized tissue and remains available for long periods (15,18). Additionally, zoledronic acid acts only on clasts, which specifies its action (17,19). Studies in patients with bone resorption have demonstrated the effectiveness of zoledronic acid in inhibiting the resorptive process (14,19,20), in the same way as observed in the present study.

It could be verified a direct relationship between the presence of cementum on the root surface and the occurrence of root resorption. In group I (zoledronic acid), a greater amount of cementum was observed when compared to group II (sodium fluoride). The superficial cleanness of the root surface prior to replantation was effective in both groups, since there was no difference between the cementum amounts in both groups, at 15 days (Table 1). At 60 days, however, in group I, the

cement was preserved due to the low root resorption rate. In group II, there were greater root resorption and cementum loss (Table 1).

The presence of the connective tissue similar to periodontal ligament was low at 60 days, although it had been considerably high at 15 days, in both experimental groups. This could be explained by the arrangement of the remanent fibers of the alveolar wall over the root instead of the formation of a new tissue (2). As time goes by, this juxtaposed tissue was replaced by bone tissue.

Due to the absence of both a newly-formed tissue and the epithelial rests of Malassez in the connective tissue perpendicular to the root, at 15 days, a newly-formed bone tissue was joined to root surface, characterizing ankylosis. This explains the increase of the ankylosis occurrence in both groups over time (Table 1). Although there was high ankylosis incidence in group I, the occurrence of replacement resorption was reduced. This proves the zoledronic acid efficiency in inhibiting root resorption.

The results of this work demonstrated that zoledronic acid was capable of limiting the occurrence of root resorption and preventing cementum resorption. Future research must be undertaken to confirm the use of zoledronic acid in root surface treatment of late replanted teeth.

RESUMO

Este trabalho teve como objetivo avaliar o uso do ácido zoledrônico, um inibidor da reabsorção, como medicação para o tratamento da reabsorção radicular em dentes replantados tardiamente. Para isso, 24 incisivos centrais superiores direito de ratos foram avulsionados e mantidos a seco por 30 min. A seguir, os dentes foram divididos em 2 grupos. No grupo I, a superfície radicular foi tratada com solução de fluoreto de sódio a 2% por 20 min; no grupo II, foi usada solução de ácido zoledrônico a 10^{-6} M, por 20 min. Todos os canais foram instrumentados e preenchidos com pasta de hidróxido de cálcio. Posteriormente, os dentes foram replantados em seus respectivos alvéolos. Após 15 e 60 dias do replante, os animais foram mortos e as peças obtidas foram preparadas para análise microscópica e morfométrica. Os resultados demonstraram que o ácido zoledrônico foi capaz de limitar a ocorrência da reabsorção radicular e previniu a reabsorção do cimento. Futuras pesquisas devem ser realizadas para confirmar o uso do ácido zoledrônico para o tratamento da superfície radicular em replantes tardios.

REFERENCE

1. Andreasen JO, Andreasen FM. Textbook and color atlas of traumatic injuries to the teeth. Copenhagen, Blackwell Munksgaard, 2007.

2. Mori GG, Garcia RB, de Moraes IG, Bramante CM, Bernardineli N. Morphometric and microscopic evaluation of the effect of solution of alendronate as an intracanal therapeutic agent in late reimplanted rat teeth. *Dent Traumatol* 2007;23:218-221.
3. Mori GG, Turcio KH, Borro VP, Mariuzo AM. Evaluation of the knowledge on tooth avulsion of school professionals from Adamantina, São Paulo, Brazil. *Dent Traumatol* 2007;23:2-5.
4. Mori GG, de Mendonça Janjácómo DM, Castilho LR, Poi WR. Evaluating the knowledge of sports participants regarding dental emergency procedures. *Dent Traumatol* 2009;25:305-308.
5. Thong YL, Messer HH, Zain RB, Saw LH, Yoong LT. Intracanal bisphosphonate does not inhibit replacement resorption associated with delayed replantation of monkey incisors. *Dent Traumatol* 2009;25:386-393.
6. Mori GG, de Moraes IG, Garcia RB, Borro LCB, Purificação BR. Microscopic investigation of the use of gallium nitrate for root surface treatment in rat teeth submitted to delayed replantation. *Braz Dent J* 2007;18:198-201.
7. Panzarini SR, Perri de Carvalho AC, Poi WR, Sonoda CK. Use of vitamin C in delayed tooth replantation. *Braz Dent J* 2005;16:17-22.
8. Esper HR, Panzarini SR, Poi WR, Sonoda CK, Casatti CA. Mechanical removal of necrotic periodontal ligament by either Robinson bristle brush with pumice or scalpel blade. Histomorphometric analysis and scanning electron microscopy. *Dent Traumatol* 2007;23:33-39.
9. Moore J, Wilson M, Kieser JB. The distribution of bacterial lipopolysaccharide (endotoxin) in relation to periodontally involved root surfaces. *J Clin Periodontol* 1986;13:748-751.
10. Selvig KA, Bjorvatn K, Bogle GC, Wikesjö UM. Effect of stannous fluoride and tetracycline on periodontal repair after delayed tooth replantation in dogs. *Scand J Dent Res* 1992;100:200-203.
11. American Association of Endodontics. Treating the avulsed permanent tooth. 2009. www.aae.org
12. Caliřkan MK, Türkün M, Gökay N. Delayed replantation of avulsed mature teeth with calcium hydroxide treatment. *J Endod* 2000;26:472-476.
13. Andreasen JO, Borum MK, Jacobsen HL, Andreasen FM. Replantation of 400 avulsed permanent incisors. 1. Diagnosis of healing complications. *Endod Dent Traumatol* 1995;11:51-58.
14. Rogers MJ, Gordon S, Benford HL, Coxon FP, Luckman SP, Monkkonen J, et al.. Cellular and molecular mechanisms of action of biphosphonates. *Cancer* 2000;88:2961-2978.
15. Villikka K, Perttunen K, Rosnell J, Ikävalko H, Vaho H, Pylkkänen L. The absolute bioavailability of clodronate from two different oral doses. *Bone* 2002;31:418-421.
16. Kellinsalmi M, Mönkkönen H, Mönkkönen J, Leskelä HV, Parikka V, Hämäläinen M, et al.. *In vitro* comparison of clodronate, pamidronate and zoledronic acid effects on rat osteoclasts and human stem cell-derived osteoblasts. *Pharm & Toxicol* 2005;97:382-391.
17. Schindeler A, Little DG. Osteoclasts but not osteoblasts are affected by a calcified surface treated with zoledronic acid *in vitro*. *Biochem Biophys Res Commun* 2005;338:710-716.
18. Rodan GA. Mechanisms of action of bisphosphonates. *Annu Rev Pharmacol Toxicol* 1998;38:375-388.
19. Deeks ED, Perry CM. Zoledronic acid: a review of its use in the treatment of osteoporosis. *Drugs Aging* 2008;25:963-986.
20. Liberman UA, Weiss SR, Bröll J, Minne HW, Quan H, Bell NH, et al.. Effect of oral alendronate on bone mineral density and the incidence of fractures in postmenopausal osteoporosis. The Alendronate Phase III Osteoporosis Treatment Study Group. *N Engl J Med* 1995;333:1437-1443.

Accepted September 15, 2010