

Immediate Implants Placed into Infected Sockets: A Case Report with 3-year Follow-up

Marina de Melo NAVES¹
Bruna Zacharias HORBYLON¹
Camila de Freitas GOMES¹
Helder Henrique Machado de MENEZES¹
César BATAGLION²
Denildo de MAGALHÃES³

¹*Department of Periodontology and Implantology,
HD Postgraduate Dental Education Center, Uberlândia, MG, Brazil*

²*Department of Restorative Dentistry, Ribeirão Preto Dental School, University of São Paulo, Ribeirão Preto, SP, Brazil*

³*Department of Periodontology and Implantology, Dental School, Federal University of Uberlândia;
and HD Postgraduate Dental Education Center, Uberlândia, MG, Brazil*

The esthetics and functional integrity of the periodontal tissue may be compromised by dental loss. Immediate implants became a viable option to maintain the periodontal architecture because of their anatomic compatibility with the dental socket and the possibility of eliminating local contamination. This article describes the procedure of immediate implant placement in the anterior maxilla replacing teeth with chronic periapical lesions, which were condemned due to endodontic lesions persisting after failed endodontic treatment and endodontic surgery, and discusses the relationship between the procedure and periapical lesions. Surgical removal of hopeless teeth 11, 12 and 21 was performed conservatively in such a way to preserve the anatomy and gingival esthetics. A second surgical access was gained at the apical level, allowing the debridement of the surgical chamber for elimination of the periapical lesion, visual orientation for setting of the implants and filling of the surgical chamber with xenogenous bovine bone graft. After this procedure, the bone chamber was covered with an absorbent membrane and the healing screws were positioned on the implants. Later, a provisional partial removable denture was installed and the implants were inserted after 6 months. After 3 years of rehabilitation, the implants present satisfactory functional and esthetic conditions, suggesting that immediate implant placement combined with guided bone regeneration may be indicated for replacing teeth lost due to chronic periapical lesions with endodontic failure history in the anterior maxilla.

Key Words: case report, dental implant, immediate implant, infected sockets, endodontic failures.

INTRODUCTION

Endodontic failures, like persistent infections, must be considered among the factors that lead to tooth loss. Periapical lesions are areas of inflammatory reactions to various antigens present in infected root canals. Histological examination of these lesions reveals the presence of granulation tissue infiltrated by immunocompetent cells such as lymphocytes, plasma cells, macrophages, polymorphonuclear leukocytes, and mast cells (1). Macrophages and lymphocytes are the predominant inflammatory cells. Microorganisms

located at the apical part of the root canal system are usually delineated from the inflamed periradicular tissues, either by a dense accumulation of polymorphonuclear neutrophils or by an epithelial plug at or near the apical foramen (2).

The placement of immediate implants represents an alternative to compromised teeth involved with infectious conditions. Alveolar ridge resorption after tooth extraction may considerably reduce the residual bone volume and compromise the favorable positioning of implants required for optimal restoration (3). This is even more pronounced in the anterior maxilla,

Correspondence: Prof. Dr. Denildo de Magalhães, Departamento de Periodontia e Implantodontia, Faculdade de Odontologia, Universidade Federal de Uberlândia, Avenida Pará, Bl 2G, Sala 8, Umuarama, 38400-902 Uberlândia, MG, Brasil. Tel: +55-34-3218-2255 / 3224-0352. e-mail: denildo@foufu.ufu.br

where ridge resorption often creates an unfavorable palatolabial discrepancy between the implant and the prosthesis. Following the correct clinical indications, the immediate placement of the implants into the extraction sockets avoids this undesirable resorption (4,5). Additional benefits, which are also valued by patients, are the avoidance of a second surgical intervention and the reduction in rehabilitation treatment time.

However, these situations of periapical pathosis conventionally contraindicate their immediate replacement with endosseous dental implants (6,7). Nevertheless, evidence arising from the treatment of vertebral osteomyelitis in orthopedic surgery suggests that this might be a misconception. Subacute bone infection in vertebral osteomyelitis can be successfully managed by meticulous bone debridement and antibiotic therapy combined with titanium mesh cages that provide immediate support and stability for the weakened vertebrae (8,9). Despite the preceding significant infectious state, these titanium cages were reported to achieve radiographic bone fusion, which is the orthopedic equivalent of osseointegration in implant dentistry.

Barcelos et al. (10) address, by reporting 3 cases, diagnostic parameters that should be observed in the treatment of extraction sockets with implants. In situations of 5- or 4-wall sockets, immediate transalveolar implant is recommended and safe, whereas for sockets with 2 or 3 remaining walls, guided bone regeneration (GBR) is indicated as a first step followed by implant placement in the healed bone as a second surgical phase.

Novaes Jr. and Novaes (11) reported that, in immediate implant placement for replacement of teeth with periapical lesions, success can be achieved if certain preoperative and postoperative measures are followed before surgery, such as antibiotic administration, meticulous cleaning, and alveolar debridement. In histomorphometric evaluations of immediate implantations in dogs with induced periapical lesions, osseointegration occurred in both the experimental and control sites (12).

Considering that immediate implants may be placed into infected sockets, this paper describes this procedure and addresses the outcomes of immediate implant placement in the anterior maxilla replacing teeth with chronic periapical lesions.

CASE REPORT

This case was conducted at HD Postgraduate

Dental Education Center, Uberlândia, MG, Brazil. All clinical procedures were fully explained to the patient, who signed an informed consent form approved by the Research Ethics Committee of the Federal University of Uberlândia (Protocol #089/07), authorizing treatment and publication of the case.

Diagnosis

A 38-year-old nonsmoker female patient in good health conditions and without chronic disease presented to the HD Postgraduate Dental Education Center with history of endodontic failure in the maxillary right lateral incisor and both central incisors, aiming the replacement of teeth with endosseous implants. The teeth had been treated endodontically due to development of periapical lesions with no lesion regression. Endodontic surgery had also failed. Clinical examinations revealed level 2 mobility and a scar on the soft tissue above the maxillary anterior teeth. Radiographic examinations confirmed the presence of chronic periapical lesions associated with teeth 11, 12 and 21 (Fig. 1A and B), leading to the indication of immediate implant placement.

Surgical Procedure

One hour before the surgical procedure, the patient received a prophylactic dose of 1 g amoxicillin. After local anesthesia (Alphacaine; DFL Indústria e Comércio S.A., Rio de Janeiro, RJ, Brazil), the surgical access was obtained on a conservative manner by means of an intrasulcular incision and removal of teeth with an extractor, aiming at the preservation of the anatomy and gingival esthetics. The implants (SIN Implants Innovation, São Paulo, SP, Brazil) were settled replacing tooth 12 (SA-313; 13 mm long x 3.75 mm diameter), tooth 11 (SA-415; 15 mm long x 4.0 mm diameter); and tooth 21 (SUR-5013; 13 mm long x 5.0 mm diameter). Then, a second access was gained at the apical level (Fig. 1C), allowing the debridement of the surgical chamber for elimination of the periapical lesion, visual orientation for apical setting of the implants and filling of the surgical chamber with xenogenous bovine bone graft (Genox/Baumer S.A., Mogi Mirim, SP, Brazil) (Fig. 2A). After this procedure the bone chamber was covered with an absorbent membrane (Genderm/Baumer S.A.), the wound was closed with 5-0 nonabsorbent monofilament Nylon

sutures (Shalon Ltda., São Luiz de Montes Belos, GO, Brazil), and the healing screws were positioned on the implants. Surgical dressing (PerioBond; Dentsply Ind. e Com. Ltda., Petrópolis, RJ, Brazil) was placed for 10 days to protect the surgical area.

Postoperative Management

After the surgical procedure, antibiotic therapy (amoxicillin 500 mg, 3 times/day; Eurofarma, São Paulo, SP, Brazil) was started and maintained for 7 days. Anti-inflammatory and analgesic were prescribed for 3 days. The use of 0.12 percent chlorhexidine oral rinses twice a day was indicated during 7 days (Periogard; Colgate-Palmolive Ltda, São Paulo, SP, Brazil). The patient was seen on a weekly basis during 4 weeks. Ten days after the surgery, when the periimplant tissues were more

stable than the day of the surgery, the surgical dressing and sutures were removed and a nonloaded removable provisional partial denture was placed.

Follow-up

Following a 6-month healing period, definitive prosthetic rehabilitation was carried out using hexed castable UCLA-type abutments after meticulous soldering in order to minimize framework misfit (13). The ceramic-metal crowns of teeth 12, 11 and 21 were placed and the posterior mandible was also rehabilitated with dental implants. At the 3-year follow-up examination, the implants were fully osseointegrated, presenting satisfactory functional and esthetic conditions without clinical or radiographic signs of alterations or pathologies (Fig. 2B and 2C).

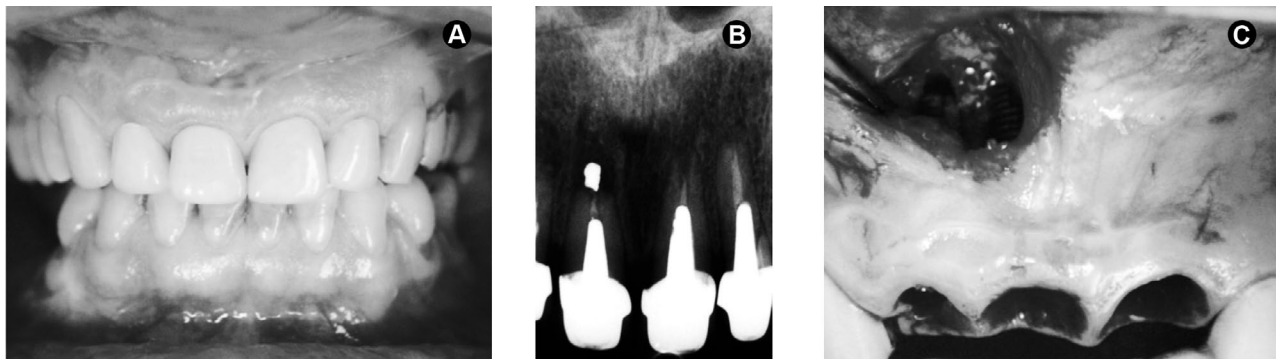


Figure 1. Panel of clinical and radiographic images of the case. A= Initial clinical aspect, B= Periapical radiograph showing the presence of chronic periapical lesions on teeth 12, 11 and 21, which had been subjected to endodontic surgery without success, C= Extraction of teeth preserving the periodontal architecture, access at the apical level (surgical chamber) and implant placement.

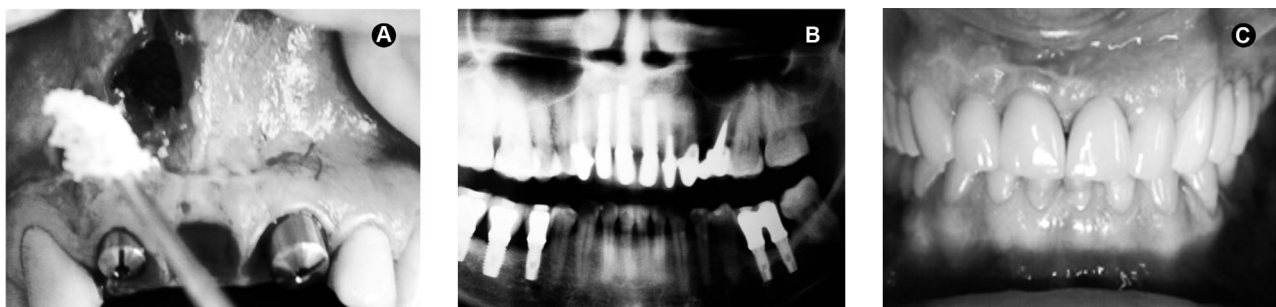

Figure 2. Panel of clinical and radiographic images of the case. A= Fulfilling of the surgical chamber with xenogenous bone graft after implant placement; B= Radiographic aspect at the 3-year follow-up visit after the definitive denture placement; C= Clinical aspect at the 3-year follow-up visit after the definitive denture placement.

DISCUSSION

The implant therapy must fulfill both functional and esthetic requirements to be considered a primary treatment modality. Aiming to reduce the process of alveolar bone resorption and treatment time, the immediate placement of endosseous implants into extraction sockets has been propagated by some authors (1,14). However, few clinical data are available on immediate implant placement in chronic periapical infected sites. Clinical reports have suggested that history of periodontal or endodontic infections is a predictive marker for implant infection and failure (15-18). Thus, some authors (6,7) contraindicate the placement of immediate implants in the presence of periodontal or periapical lesions. This is justified by the possibility of soft and hard tissues contaminations near the implant during the surgery; persistence of contaminants that were not seen clinically; dimension of the lesion; inadequate morphology of the area or a non-effective debridement of the injury during the surgery.

On the other hand, Novaes Jr. and Novaes (12) stated that the placement of immediate implants in chronically infected sites may not be necessarily contraindicated if appropriate clinical procedures like antibiotic administration, meticulous cleaning, and alveolar debridement are performed before implant surgical procedure. Recently, Lindeboom et al. (19) carried out a prospective and randomized study of 50 patients aiming to evaluate the clinical success of immediate implants in periapical infected sites. The results showed a success rate of 92% for the immediate implants and 100% for the delayed implants (placed 3 months post-extraction). Those authors concluded that immediate placement of single tooth implants for replacement of teeth with periapical lesions is a predictable treatment and can be indicated.

Casap et al. (20) also described the immediate placement of dental implants into debrided infected dentoalveolar sockets. A total of 30 implants were immediately placed into debrided infected sites in 20 patients and a protocol of meticulous debridement of the infected tissues in combination with peripheral osteotomy of the alveolus was followed. GBR was accomplished to support bone healing of periimplant alveolar defects and pre- and postsurgical antibiotic therapy was administered. All implants but one achieved osseointegration and were functioning within 12 to 72 months of follow-up. One implant was mobile after its

immediate restoration and was removed. Complications like membrane exposure and attached gingiva deficiency were related to the use of GBR.

Considering the results of these studies (12,19,20), the replacement of 3 condemned teeth with endodontic failure history by immediate implant was successfully introduced into debrided infected dentoalveolar sockets in this 3-year follow up evaluation. Based on a protocol that targets the elimination of the contaminated soft and hard tissues by meticulous debridement, this procedure was combined with pre- and postoperative antibiotics, eradicating the infection and establishing a favorable basis for bone healing and osseointegration.

Although the use of GBR has been associated with some complications (20), favorable outcomes were obtained in the present case using this technique. Similar to the treatment of plaque-induced peri-implantitis, the protocol that completely removes the contaminated tissue was maintained, allowing successful GBR of the previously infected alveolus. Thus, the use of absorbent membrane and xenogenous bone graft did not compromise the success of the immediate implants.

While this case report presented successful results by placing immediate implants into debrided infected 4- and/or 5 wall sockets, as reported by Barcelos et al. (10), this procedure should be limited to experienced surgeons who are highly skilled in differentiating and debriding granulation tissue. The surgeon must also be proficient in GBR procedures to skillfully correct the significant alveolar defects that are commonly associated with these cases. Subject to these competencies, skills and adherence to the proposed protocol, the immediate implants should be considered a viable treatment option in patients presenting dentoalveolar infections. Successful immediate placement into infected sites depends on the antibiotic regimen, the elimination of all contaminated tissues and the controlled regeneration of the alveolar defect.

Immediate implant placement into infected sockets combined with GBR represents an alternative to optimize the treatment time and periodontal architecture and esthetics, and may be indicated for replacing teeth lost due to chronic periapical lesions with endodontic failure history.

RESUMO

A integridade estética/funcional do tecido periodontal pode ser comprometida pela perda do elemento dental. Os implantes imediatos tornaram-se uma opção viável na manutenção da arquitetura

periodontal, desde que haja a compatibilidade com o alvéolo e a possibilidade da contaminação local ser totalmente eliminada. O objetivo deste estudo foi descrever o procedimento de instalação de implantes imediatos na região anterior de maxila usados na reposição de dentes com lesões crônicas periapicais, discutindo a relação entre o procedimento e lesões periapicais. A remoção dos dentes condenados (11, 12 e 21) foi feita de forma conservadora a fim de preservar a estética e arquitetura periodontal. Um segundo acesso cirúrgico foi obtido a nível apical, permitindo: o debridamento da loja cirúrgica, orientação visual dos implantes e o preenchimento com enxerto ósseo bovino. A loja óssea foi coberta por uma membrana absorvível e uma prótese parcial removível provisória foi instalada e após 6 meses os implantes foram reabilitados. Após 3 anos de reabilitação, os implantes se apresentam em condições satisfatórias de estética/função, sugerindo que a instalação de implantes imediatos combinados com a regeneração tecidual guiada em lesões periapicais crônicas podem ser indicados para repor dentes perdidos devido a lesões periapicais crônicas com história de insucesso endodôntico na maxila anterior.

REFERENCES

- Lazzara RJ. Immediate implant placement into extraction sites: surgical and restorative advantages. *Int J Periodontics Restorative Dent* 1989;9:332-343.
- Siqueira JF Jr. Endodontic infections: concepts, paradigms, and perspectives. *Oral Sur Oral Med Oral Pathol Radiol Endod* 2002;94:281-293.
- Kan JY, Shiotsu G, Rungcharassaeng K, Lozada, JL. Maintaining and attenuating periodontal tissues for aesthetic implant placement. *J Oral Implantol* 2000;26:35-41.
- Schropp L, Kostopoulos L, Wenzel A. Bone healing following immediate versus delayed placement of titanium implants into extraction sockets: a prospective clinical study. *Int J Oral Maxillofac Implants* 2003;18:189-199.
- Werbitt MJ, Goldberg PV. The immediate implant: bone preservation and bone regeneration. *Int J Periodontics Restorative Dent* 1992;12:206-217.
- Becker W, Becker BE. Guided tissue regeneration for implants placed into extraction sockets and for implant dehiscences: surgical techniques and case report. *Int J Periodontics Restorative Dent* 1990;10:376-391.
- Barzilay I. Immediate implants: their current status. *Int J Prosthodont* 1993;6:169-175.
- Hee HT, Majd ME, Holt RT, Pienkowski D. Better treatment of vertebral osteomyelitis using posterior stabilization and titanium mesh cages. *J Spinal Disord Tech* 2002;15:149-156.
- Liljenqvist U, Lerner T, Bullmann V, Hackenbrg L, Halm H, Winkelmann W. Titanium cages in the surgical treatment of severe vertebral osteomyelitis. *Eur Spine* 2003;12:606-612.
- Barcelos MJR, Novaes Júnior AB, Conz MB, Harari ND, Vidigal Júnior GM. Diagnosis and treatment of extraction sockets in preparation for implant placement: report of three cases. *Braz Dent J* 2008;19:159-164.
- Novaes AB Jr, Novaes AB. Immediate implants placed into infected sites: a clinical report. *Int J Oral Maxillofac Implants* 1995;10:609-613.
- Novaes AB Jr, Vidigal GM Jr, Novaes AB, Grisi MF, Polloni S, Rosa A. Immediate implants placed into infected sites: a histomorphometric study in dogs. *Int J Oral Maxillofac Implants* 1998;13:422-427.
- Barbosa GAS, Simamoto Júnior PC, Fernandes Neto AJ, Mattos MGC, Neves FD. Prosthetic laboratory influence on vertical misfit at the implant/UCLA abutment interface. *Braz Dent J* 2007;18:139-143.
- Öhrnell LO, Hirsch JM, Ericsson I, Brånemark PI. Single-tooth rehabilitation using osseointegration. A modified surgical and prosthodontic approach. *Quintessence Int* 1988;19:871-876.
- Ayango L, Sheridan PJ. Development and treatment of retrograde peri-implantitis involving a site with a history of failed endodontic and apicoectomy procedures: a series of reports. *Int J Oral Maxillofac Implants* 2001;16:412-417.
- Oh TJ, Yoon J, Wang HL. Management of the implant periapical lesion: a case report. *Implant Dent* 2003;12:41-46.
- Karoussis IK, Salvi GE, Heitz-Mayfield LJ, Brägger U, Hämmerle CH, Lang NP. Long-term implant prognosis in patients with and without a history of chronic periodontitis: a 10-year prospective cohort study of the ITI Dental Implant System. *Clin Oral Implants Res* 2003;14:329-339.
- Polizzi G, Grunder U, Goené R, Hatano N, Henry P, Jackson WJ, et al. Immediate and delayed implant placement into extraction sockets: a 5-year report. *Clin Implant Dent Relat Res* 2000;2:93-99.
- Lindeboom JAH, Tjjiok Y, Kroon FHM. Immediate placement of implants in periapical infected sites: a prospective randomized study in 50 patients. *Oral Surg Oral Med Oral Pathol Oral Radiol Endod* 2006;101:705-710.
- Casap N, Zeltser C, Wexler A, Tarazi E, Zeltser R. Immediate placement of dental implants into debrided infected dentoalveolar sockets. *J Oral Maxillofac Surg* 2007;65:384-392.

Accepted August 11, 2009