

Candida albicans in Patients with Oronasal Communication and Obturator Prostheses

Beatriz Silva Câmara MATTOS¹
Andréa Alves de SOUSA¹
Marina Helena C. G. de MAGALHÃES²
Marcia ANDRÉ¹
Reinaldo BRITO E DIAS¹

¹Department of Maxillofacial Surgery, Traumatology and Prosthodontics,
Dental School, University of São Paulo, São Paulo, SP, Brazil

²Department of Oral Pathology, Dental School, University of São Paulo, São Paulo, SP, Brazil

Patients using obturator prostheses often present denture-induced stomatitis. In order to detect the presence of oral *Candida albicans* in patients with oronasal communications and to evaluate the effectiveness of a topical antifungal treatment, cytological smears obtained from the buccal and palatal mucosa of 10 adult patients, and from the nasal acrylic surface of their obturator prostheses were examined. A therapeutic protocol comprising the use of oral nystatin (Mycostatin®) and prosthesis disinfection with sodium hypochlorite was prescribed for all patients. Seven patients were positive for *C. albicans* in the mucosa, with 1 negative result for the prosthetic surface in this group of patients. Post-treatment evaluation revealed the absence of *C. albicans* on prosthesis surface and on the oral mucosa of all patients. The severity of the candidal infection was significantly higher in the palatal mucosa than in the buccal mucosa, but similar in the palatal mucosa and prosthesis surface, indicating that the mucosa underlying the prosthesis is more susceptible to infection. The therapeutic protocol was effective in all cases, which emphasizes the need for denture disinfection in order to avoid reinfection of the mucosa.

Key Words: *Candida albicans*, oronasal communication, obturator prostheses, candidiasis.

INTRODUCTION

Candida albicans is the most common fungus found in the oral cavity. It may be present as part of the normal microbial flora and, as such, is not an overt pathogen (1).

However, oral candidal infection frequently occurs when host defenses are lowered by local factors (prosthesis irritation, xerostomia), medications (antibiotics, immunosuppressant drugs), treatment regimens (chemotherapy, radiation therapy) and systemic disorders (physical debilitation, malnutrition, and endocrine and immune disturbances) (2,3). Fungal infection have increased in prevalence, especially in denture-wearers and aged people, and may lead to invasive infections

that have a high mortality rate (4).

Several studies have mentioned the increased occurrence of candidal infection and colonization in patients wearing partial or total removable dentures (5,6) and have discussed the involvement of *C. albicans* in the establishment and persistence of denture-related stomatitis, a local recurring disease that affects the mucosa underneath the fitting surface of the prosthesis (7).

Some aspects should be considered when analyzing the use of complete or partial removable dentures, as a predisposing factor to denture-induced stomatitis secondary to *C. albicans* overgrowth. The presence of an overlying, synthetic material alters the local environment by decreasing saliva flow and lowering pH values, creating conditions that seem to facilitate the adherence

of this microorganism (7). Tissue microtrauma, resulting from denture misfit may be present, and traumatic injury can reduce tissue resistance to infection and increase epithelial permeability to soluble *Candida* antigens and toxins (5,8). The acrylic surface allows microbial adhesion and facilitates multilayered candidal colonization and biofilm formation of blastospores as well as the hyphal phase (3). This situation may worsen in the case of poor oral hygiene and defective denture cleansing. The purposes of the present study were to investigate the prevalence of *C. albicans* on the mucosa of 10 patients with oronasal communication using obturator prostheses, and to evaluate the effectiveness of a topical antifungal regimen.

MATERIAL AND METHODS

Ten patients attending the Maxillofacial Prosthesis Outpatient Service of the Dental School, University of São Paulo, Brazil, for prosthetic rehabilitation were selected for the study. The subjects were healthy adult volunteers (9 females and 1 male) aged 18 years or older presenting cleft lip and palate with oronasal communication due to the lack of reconstructive palatoplasty or sequelae. All patients had been using obturator prosthesis for at least 1 year, and were not receiving systemic antibiotics or steroidal antiinflammatory drugs at the time of the investigation.

Oral candidiasis is the most frequent clinical infection of the oral cavity and oropharynx in irradiated patients (9). Radiation therapy administered to patients

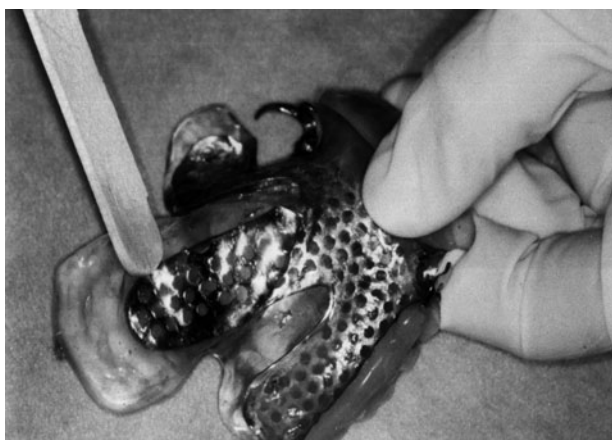

Figure 1. Nasal side of a palatopharyngeal obturator prosthesis.

with oral neoplasia may be part of a combined radiation-surgery management, and maxillary resection may lead to a defect that can be rehabilitated with obturator prosthesis. In the present study, patients subjected to radiation therapy were excluded from the study to observe the alterations caused by the presence of an oronasal communication alone. The protocol did not include the fabrication of new prostheses since prosthetic treatment has no therapeutic effect on denture-induced stomatitis caused by candidal infection (10).

Two samples were collected from each patient for cytological analysis. The first oral sample was taken by gently scraping the mucosa at the edge of the oronasal communication with a wooden spatula; the second oral sample was taken from the buccal mucosa. Additionally, a third sample was obtained from the acrylic nasal surface of the obturator prosthesis (Fig. 1). The samples were smeared onto glass slides, labeled with the patient's identification number and oral location, and stained using the Periodic Acid-Schiff (PAS) Method to reveal the fungal organisms. Patients who were positive for *C. albicans* at any given oral site, or on the prosthesis itself, received treatment, regardless of clinical signs or symptoms of oral candidiasis.

A combined treatment involving brushing the prosthesis with a denture paste, and chemical soaking. During treatment, patients were instructed to brush their prostheses with a denture cleaning paste followed by soaking in a sodium hypochlorite solution overnight, which has been shown to provide the best result in removing residual food, bacteria and yeasts (11), and then rinsing carefully in tepid water before use the next morning.

Commercially available denture cleansers are divided into several types, depending on their chemical constituents (12). Alkaline sodium hypochlorite was the substance of choice in the present study due to its low cost and efficacy as an antimicrobial agent. The solution used in this study has no corrosive effect on metallic frameworks (13). The oral mucosa was treated with Mycostatin[®], a mouthwash of topical Nystatin and water (4:1), 4 times a day. After 10 days of treatment, the patients were re-evaluated for oral infection and prosthetic colonization by *C. albicans*.

The cytological analyses regarding contamination level were scored 0 (negative), 1 (low), 2 (moderate) and 3 (high). Data were analyzed statistically by Fisher's exact test. A significance level of 5% was set for all analysis ($\alpha=0.05$).

RESULTS

The distribution of scores for *C. albicans* infection on the oral mucosa and obturator prosthesis surface is shown in Table 1. The palatal region around the oronasal communication gave 7 positive results, 3 being rated low, 2 moderate and 2 high. All infected patients exhibited palatal contamination, but only 1 patient had *C. albicans* on the buccal mucosa. This patient was also positive for *C. albicans* on the palatal mucosa and prosthesis, presenting heavy contamination in all analyzed regions. The acrylic surface was colonized, with hyphae present in 6 prostheses (Fig. 2), 1 case rated as moderate and 5 cases rated as high. All patients with *C. albicans* detected on their prostheses, presented similar or heavier contamination on the palatal mucosa. The nasal acrylic surface seemed to facilitate *C. albicans* colonization, permitting the development of large hyphal structures.

Seventy percent of the patients were positive for *C. albicans* on the oral mucosa and 60% of the patients were using contaminated obturator prostheses. All positive patients receiving the combined treatment were negative (score 0) for *C. albicans* on the oral mucosa and on the prosthesis when re-evaluated.

The Fisher's test showed that infection of the palatal mucosa was significantly higher compared to

infection of the buccal mucosa ($p=0.019$). However there was no statistically significant difference ($p>0.05$) between the palatal mucosa and the prosthetic surface. The palatal mucosa infection was also significantly higher when compared to that of the buccal mucosa ($p=0.027$). There was no significant difference ($p>0.05$) between the palatal mucosa and the prosthetic surface. Prosthesis infection was significantly higher when compared to that of the buccal mucosa ($p=0.043$).

DISCUSSION

C. albicans is a typical oral commensal present in 30 to 70% of apparently healthy persons. Denture-induced stomatitis affects approximately 65% of patients who wear prosthetic devices, mostly in the maxillary arch (2,5). The multifactorial etiology of this condition has long been suggested, including local and systemic factors such as trauma from ill-fitting dentures, microbial infection, poor denture hygiene, continuous denture wear, diet and antibiotic drug use (8). The presence of large oronasal communications alters the normal oral environment and different results are expected in this situation. However, 70% of patients evaluated in the present study were positive for *C. albicans*, which is a value similar to those reported in the literature for normal populations.

Additionally, none of the patients evaluated mentioned the most common symptom of oral candidiasis, a sore mouth. Two patients displayed small, grapelike,

Table 1. Score distribution for *Candida albicans* infection on the oral mucosa and obturator prosthesis surface.

Patient	Oral mucosa		Obturator prosthesis
	Buccal	Palatal	
1	0	1	3
2	0	2	3
3	0	3	3
4	0	1	2
5	0	2	3
6	0	1	0
7	3	3	3
8	0	0	0
9	0	0	0
10	0	0	0

Scores for candidal infection: 0 = negative; 1 = low; 2 = moderate; 3 = high.

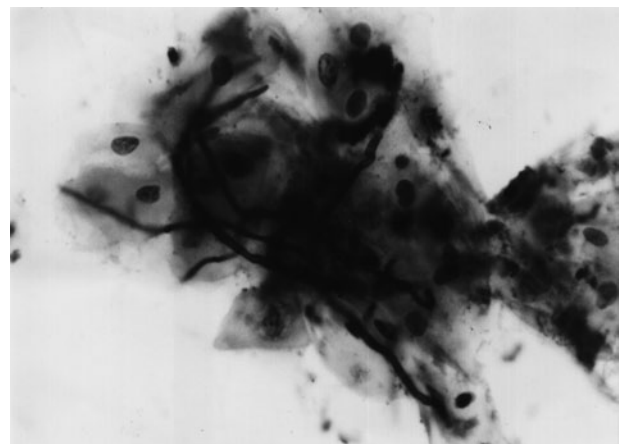


Figure 2. Cytological smear from palatal mucosa demonstrating branching hyphae stained with PAS.

bright red areas on the palatal mucosa, but none on the buccal mucosa. The isolation of *C. albicans* from the palatal mucosa and the presence of hyphae on the nasal acrylic surface confirm that denture use increases candidal colonization and predisposes the user to oral candidiasis. The findings of the present study showed that the oral mucosa underlying the prosthesis is more susceptible to colonization by *C. albicans*, and that the presence of an oronasal communication in this region had no direct effect on candidal infection. Furthermore, alterations to the overall oral environment seem not to affect oral mucosa colonization, since the results of the present study confirm those reported in the literature for normal, edentulous populations.

Studies regarding the colonization of the nasal floor by aerobic (14) and anaerobic (15) oral flora in patients with cleft palate and oronasal fistulae indicated poor transmission of bacteria through the fistula, competition with commensal nasal flora, or an inability of oral bacteria to survive in a saliva-depleted area. Nevertheless, the high colonization of the nasal acrylic surface by *C. albicans* should be matter of concern since it is in direct relation to the nasal floor and adds contamination to the nasal cavity.

These results reinforce the need for patient education regarding personal hygiene habits and prosthetic care. Previous evaluation of methods for cleaning denture on biofilms formed *in vitro* on acrylic resins demonstrated that mechanical and combination methods were similar and more effective than chemical method for *C. albicans* (16). The combination treatment proposed here was based on methods and substances proven to be effective. Alkaline hypochlorite was the substance of choice here, owing to its low cost and efficacy as denture disinfecting solution. All the prostheses examined in this study were made of heat-polymerized acrylic resin and no alteration was observed in this material after treatment. The solution used in this study had no corrosive effect on the metallic partial-denture frameworks (13). The effect of alkaline hypochlorite on the physical properties of the resilient resins employed as denture-lining material should be evaluated since soft liners are known to be susceptible to deterioration by denture cleansers (17).

The elimination of *C. albicans* from human tissue has been performed effectively with topical Nystatin for nearly 30 years (1,2) and the patients have responded positively to topical treatment with this antifungal agent. Aiming to prevent *C. albicans* biofilm formation on

denture material, *in vitro* studies have reported positive results when using thin-film polymer PMMA associated with antifungal medications for coating denture material (18) or pre-coating with antifungal agents (19), suggesting that these methods should be evaluated as a potential preventive therapy for denture-induced stomatitis.

C. albicans infection in patients with oronasal communication and obturator prostheses is similar to that presented by patients using conventional prosthesis. The greater infection of the palatal mucosa and nasal acrylic surface of the prosthesis, indicates that the mucosa underlying the prosthesis is more susceptible to infection, and should be considered the best site for diagnosis. The treatment proposed in the present study was effective in eliminating *C. albicans* from the oral mucosa and disinfecting the prostheses. Patients wearing prosthetic obturators should be evaluated regularly, and microbiological control should be performed periodically to detect and prevent the development of oral candidiasis.

RESUMO

Os pacientes portadores de prótese obturadora frequentemente apresentam estomatite protética. Com o objetivo de detectar a presença de *Candida albicans* oral em pacientes com comunicação oronasal e avaliar a eficácia de um tratamento tópico antifúngico foi realizada citologia esfoliativa da mucosa palatina e jugal e da superfície acrílica nasal da prótese obturadora. O protocolo terapêutico consistiu de nistatina (Mycostatin®) para tratamento da mucosa oral e uma solução de hipoclorito de sódio para desinfecção da prótese. Sete pacientes (70%) apresentaram resultado positivo para *C. albicans* na mucosa, com um resultado negativo para a superfície protética neste grupo. A avaliação após o tratamento revelou ausência de *C. albicans* na mucosa oral de todos os pacientes, bem como na superfície protética. A infecção por *C. albicans* das mucosas jugal e palatina diferiram significativamente, enquanto que a mucosa palatina e a superfície protética apresentaram valores semelhantes. O grau de infecção da mucosa palatina foi significativamente maior quando comparado àquele da mucosa jugal e semelhante ao apresentado pela prótese, sugerindo que a mucosa subjacente à prótese é mais susceptível à infecção. O protocolo terapêutico foi efetivo em todos os casos, o que enfatiza a necessidade da desinfecção protética para se evitar a reinfecção da mucosa oral.

REFERENCES

1. Webb BC, Willcox MDP, Thomas CJ, Harty DWS, Knox KW. The effect of sodium hypochlorite on potential pathogenic traits of *Candida albicans* and other *Candida* species. *Oral Microbiol Immunol* 1995;10:334-341.
2. Iacopino AM, Wathen WF. Oral candidal infection and denture stomatitis: a comprehensive review. *J Am Dent Assoc* 1992;123:46-

- 51.
3. Nikawa H, Egusa H, Makihira S, Yamashiro H, Fukushima H, Jin C, Nishimura M, Pudji RR, Hamada T. Alteration of the coadherence of *Candida albicans* with oral bacteria by dietary sugars. *Oral Microbiol and Immunol* 2001;16:279-283.
4. ten Cate JM, Klis FM, Pereira-Cenci T, Crielaard W, de Groot PWJ. Molecular and cellular mechanisms that lead to candida biofilm formation. *J Dent Res* 2009;88:105-115.
5. Figueiral MH, Azul A, Pinto E, Fonseca PA, Branco FM. Denture-related stomatitis: Identification of aetiological and predisposing factors – a large cohort. *J Oral Rehabil* 2007;34:448-455.
6. Darwazeh AM, Al-Refai S, Al-Mojaiwel S. Isolation of *Candida* species from the oral cavity and fingertips of complete denture wearers. *J Prosthet Dent* 2001;86:420-423.
7. Gasparoto TH, Dionisio TJ, Oliveira CE, Porto VC, Gelani V, Santos CF, Campanelli AP, Lara VS. Isolation of *Candida dubliensis* from denture wearers. *J Med Microbiol* 2009;58:959-962.
8. Budtz-Jørgensen E. Etiology, pathogenesis, therapy, and prophylaxis of oral yeast infections. *Acta Odontol Scand* 1990;48:61-69.
9. Farah CS, Hong S, Wanasangsakul S, Elahi S, Pang G, Gotjamanos T, Seymour GJ, Clancy RL, Ashman RB. Irradiation-induced oral candidiasis in an experimental murine model. *Oral Microbiol Immunol* 2001;16:358-363.
10. Kulak Y, Arıkan A, Delibalta N. Comparison of three different treatment methods for generalizes denture stomatitis. *J Prosthet Dent* 1994;72:283-288.
11. Chan ECS, Iugovaz I, Siboo R, Bilyk M, Barolet R, Amsel R, Wooley C, Klitorinos A. Comparison of two popular methods for removal and killing of bacteria from dentures. *J Can Dent Assoc* 1991;57:937-939.
12. Sheen SR, Harrison A. Assessment of plaque prevention on dentures using an experimental cleanser. *J Prosthet Dent* 2000;84:594-601.
13. Banting DW, Greenhorn PA, McMinn JG. Effectiveness of a topical antifungal regimen for the treatment of oral candidiasis in older, chronically ill, institutionalized, adults. *Can Dent Assoc* 1995;61:199-205.
14. Brennan PA, Markus AF, Flood TR, Downie IP, Uppal R. Do oral flora colonize the nasal floor of patients with oronasal fistulae? *Cleft Palate Craniofac J* 2001;38:399-400.
15. Brennan PA, Willy P, Anand R, Markus AF. Colonization of the cleft nasal floor by anaerobic oral flora in patients with oronasal fistulae. *Cleft Palate Craniofac J* 2009;40:431-432.
16. Paranhos HF, Silva-Lovato CH, Souza RF, Cruz PC, Freitas-Pontes KM, Watanabe E, Ito IY. Effect of three methods for cleaning dentures on biofilms formed *in vitro* on acrylic resin. *J Prosthodont* 2009;18:427-431.
17. Nikawa H, Yamamoto T, Hamada T, Rahardjo MB, Murata H. Commercial denture cleansers - cleansing efficacy against *Candida albicans* biofilm and compatibility with soft denture-lining materials. *Int J Prosthodont* 1995;8:434-443.
18. Redding S, Bhatt B, Rawls, HR, Siegel G, Scott K, Lopez-Ribot J. Inhibition of *Candida albicans* biofilm formation on denture material. *Oral Surg Oral Pathol Oral Radiol Endod* 2009;107:669-672.
19. Pusateri CR; Monaco EA, Edgerton M. Sensitivity of *Candida albicans* biofilm cells grown on denture acrylic to antifungal proteins and chlorhexidine. *Arch Oral Biol* 2009;54:588-594.

Accepted October 16, 2009