

Monitoring Nonsurgical and Surgical Root Canal Treatment of Teeth with Primary and Secondary Infections

Carlos Estrela¹, Júlio Almeida Silva¹, Daniel Almeida Decurcio¹, Ana Helena G Alencar¹, Cyntia RA Estrela², Luiz Augusto Faitaroni², Aline Carvalho Batista¹

¹Department of Stomatologic Sciences, UFG - Federal University of Goiás, Goiânia, GO, Brazil

²Department of Endodontics, University of Cuiabá, Cuiabá, MT, Brazil

Correspondence: Prof. Dr. Carlos Estrela, Praça Universitária s/n, Setor Universitário, 74605-220 Goiânia, GO, Brasil. Tel.: +55-62-3209-6254. e-mail: estrela3@terra.com.br

The aim of this study was to monitor nonsurgical and surgical root canal treatment (RCT) of teeth with primary and secondary infections and apical periodontitis (AP). This prospective clinical study comprised the treatment of 80 patients with primary and persistent secondary infections and AP. Of this initial sample, forty patients did not return. Periapical index using cone beam computed tomography scans (CBCTPAI) was used to aid diagnosis, planning and to determine the better therapeutic strategy. Twenty patients (26 teeth) diagnosed with primary infection and AP received conventional RCT and were followed up for 10 to 36 months. Twenty patients (31 teeth) diagnosed with persistent secondary infection were submitted to periapical surgical and followed up for 6 to 30 months. The results showed RCT successful in 19/26 cases with complete AP healing (5/26 with partial repair) in 10-36 months of follow up. For the surgically managed cases, effectiveness of surgical therapy was detected in 10/31 cases with complete healing (10/31 cases with partial repair) within 6-30 months follow up. The return of patients for clinical and radiographic follow-up, and obedience to the proposed time period was very short from ideal. The levels of success in both therapeutic protocols were high. RCT failures were detected even with rigorous standard clinical protocols.

Key Words: healing process, apical periodontitis, primary infection, secondary infection, periapical surgery, cone beam computed tomography, outcome.

Introduction

One of the main reasons for the failure of root canal treatment (RCT) is perseverance of bacterial contamination (1). Apical periodontitis (AP) characterizes an inflammatory response to root canal infection. AP from endodontic origin is verified in progressive stages of inflammation and destruction of periapical bone, which generally are observed as periapical granulomas, radicular cysts or abscesses (2). Special attention was required to select the therapeutic option, because periapical diseases of nonendodontic origin may mimic common infections of endodontic origin (3).

The diagnosis and therapeutic strategy often used in endodontics to treat a disease has been based on clinical and radiographic aspects, aided by complementary exam whenever required. The major challenge involves the adoption of effective protocols for bacterial decontamination in difficult access areas. RCT comprises removing the pulp tissue, microorganisms and their byproducts, enlarging the root canal, filling the canal space and tightly sealing the coronal access. These aspects depend on the effectiveness of sanitization process, which includes the use of endodontic instruments and irrigant solution, intracanal dressing, root canal space completely filled, and permanently restored and functioning tooth (4).

The parameters often used to determine the success in endodontically treated teeth (ETT) includes absence of pain and swelling; absence of drainage and fistula; tooth in

function with normal periapical physiology; absence or regression of periapical bone rarefaction (4-6).

Thus, the follow up is important and the patient should be invited to return for clinical and radiographic evaluation at the scheduled date. Among the risk factors enumerated for the presence of AP post-treatment is included the quality of RCT and coronal restoration, which if not strictly implemented may maintain residual infection. The judicious application of a therapeutic protocol requires understanding the challenge of the balance of a correct management between the sanitization process and the complex internal anatomy. The apical limit of RCT and different clinical conditions alone or combined may subsidize the final therapeutic prognosis, including root canal perforation, overfilling, endodontic and periodontal lesion, root fracture, periapical biofilm, traumatic dental injury, fracture of instrument, AP, root resorption, etc. Thus, the successful RCT prevents pain, AP and in the end, tooth loss (4).

In the last decades, the outcome of nonsurgical and surgical RCT structured with a controlled therapeutic approach has targeted high success estimate (7-13).

Monitoring the outcomes of RCT is essential to establish safe therapeutic decisions for the healing infectious processes. Thus, it can ensure the quality control of therapeutic strategy and estimate the outcome of the RCT. The aim of this study was to follow up nonsurgical and

surgical RCT of teeth with primary and secondary infections and apical periodontitis.

Material and Methods

Sample Selection

This clinical and prospective study was composed by an initial sample of 80 patients with root canal infections and apical periodontitis (AP) evaluated between the years of 2009 and 2014 (mean age 34 years-old, 26 men). The patients were referred to the Dental Urgency Service of the School of Dentistry of the Federal University of Goiás, (Goiânia, GO, Brazil) for routine RCT. The patients were submitted to a clinical interview, review of dental/medical history and clinical/imaging examinations. The teeth included in the study presented primary and secondary root canal infection associated with AP. The inclusion criterion was clinically healthy subjects (no history of systemic disease) with diagnostic hypothesis of AP. The exclusion criteria included pregnant women, patients with systemic problems, periodontal disease, or that made use of systemic medications or had antimicrobial treatment in the last three months. The study was approved by the research ethics board of the Federal University of Goiás (Process #170-171/2009) and the participants signed an informed consent form.

Clinical Procedures

From the initial selected sample, 40 patients dropped out of treatment for undeclared reasons. Considering the necessity of imaging exams to help the diagnoses of periapical diseases and treatment planning, CBCT images were acquired with the first generation i-CAT Cone Beam 3D imaging system (Imaging Sciences International, Hatfield, PA, USA). These cases showed complex and/or doubtful conditions. The volumes were reconstructed with isotropic-isometric voxels measuring 0.20 mm x 0.20 mm x 0.20 mm. The tube voltage was 120 kVp and the tube current 3.8 mA. Exposure time was 40 s. Images were examined with the scanner's proprietary software (Xoran version 3.1.62; Xoran Technologies, Ann Arbor, MI, USA) in a PC workstation running Microsoft Windows XP professional SP-2 (Microsoft Corp, Redmond, WA, USA), with processor Intel(R) Core(TM) 2 Duo-6300 1.86 Ghz (Intel Corporation, USA), NVIDIA GeForce 6200 turbo cache videocard (NVIDIA Corporation, Santa Clara, CA, USA) and Monitor EIZO - Flexscan S2000, resolution 1600x1200 pixels (EIZO NANAO Corporation, Hakusan, Japan).

In 26 teeth from 20 patients diagnosed with primary infection (infection present before RCT) associated with AP (14 maxillary anterior teeth, 2 mandibular anterior teeth, 3 maxillary premolars, 3 mandibular premolar, 2 maxillary molars and 2 mandibular molars), the clinical

management proposed was nonsurgical RCT. The strategy consisted of root canal access and cervical third, without anesthesia. Then, the root canals were instrumented using a crown-down technique; the root canals prepared up to a size 40-50 K-Flexofile (Dentsply/Maillefer, Ballaigues, Switzerland), 1 mm short of the apical foramen. In all teeth, the root canals were irrigated with 5 mL of 2.5% sodium hypochlorite (NaOCl, recently prepared) at each change of file; a calcium hydroxide paste with distilled water was used as an intracanal dressing for 21 days. Teeth were then radiographed in order to confirm the compactness of calcium hydroxide paste. The teeth had temporary coronal restoration with glass ionomer (Vitrebond; 3M ESPE, St. Paul, MN, USA). After 21 days, the intracanal dressing was removed and the root canals were filled with gutta-percha and Sealapex™ (Sybron Kerr, Orange, CA, USA) using the lateral condensation technique, and definitive coronal restoration with composite resin.

In 31 teeth from 20 patients with persistence of secondary infection (infection present after RCT) (13 maxillary anterior teeth, 7 mandibular anterior teeth, 5 maxillary premolars, 5 maxillary molars and 1 mandibular molar) and AP, considered failure of current root canal retreatment, was indicated periapical surgery.

The imaging data used for the surgical planning were: extent of lesion; RCT condition; expansion and/or destruction of periapical cortical bone; involvement of the lesion with surrounding anatomical structures (mandibular canal, mental foramen, incisive foramen, maxillary sinus, nasal cavity, apical region of neighboring teeth); distance between periapical lesion/bone destruction and gingival margin.

The inclusion criteria of patients referred for periapical surgery was permanent ETT with persistent secondary infection. Periapical lesions were considered persistent in cases undergoing root canal retreatment, whose clinical and radiographic follow up continues suggesting maintenance of periapical infection after 3 months of retreatment. The cases with real indication of periapical surgery were included in the study.

The surgical procedure was planned according to the particular characteristics of each case, taking into account the extent of the lesion and relationship with neighboring anatomical structures. The surgical procedures included: antibacterial conditioning of the oral cavity; anesthesia; gentle incision; detachment of gingival mucosa; osteotomy; removal of the lesion; root-end resection (apicoectomy) - removal of 3 mm of apical root-end; ultrasonic root-end preparation; root-end filling with MTA; suture. The patients returned after 7 days for clinical evaluation and for suture removal. The macroscopic appearance of the periapical lesion was analyzed in terms of shape, color and consistency.

Table 1. Cone beam computed tomography periapical index scores ((CBCTPAI)(14)

N	Bone alterations on periapical structures
0	Intact periapical bone structures
1	Diameter of periapical radiolucency > 0.5-1mm
2	Diameter of periapical radiolucency > 1-2mm
3	Diameter of periapical radiolucency > 2-4mm
4	Diameter of periapical radiolucency > 4-8mm
5	Diameter of periapical radiolucency > 8mm
n + E	Expansion of periapical cortical bone
n + D	Destruction of periapical cortical bone

The variables E (expansion of cortical bone) and D (destruction of cortical bone) were added to each score, if either of these conditions was detected in the CBCT analysis.

Table 2. Outcomes of nonsurgical RCT in teeth with primary infections and AP (n=26)

Case	Teeth	CBCTPAI	Follow-up	Outcome
1	MXA	5 (>8 mm)	21 months	0
2	MXA (n=2)	3 (>2-4 mm)	19 months	1 (>0.5-1 mm)
3	MXA (n=2)	4 (>4-8 mm)	17 months	0
4	MXA	5 (>8 mm)	17 months	5 (>8 mm)
5	MXM	3D (>2-4 mm)	20 months	1 (>0.5-1mm)
6	MXPM	2 (>1-2 mm)	20 months	0
7	MXA	2 (>1-2 mm)	20 months	0
8	MNA (n=2)	4 (>4-8 mm)	18 months	0
9*	MXA	5 (>8 mm)	22 months	4 (>4-8 mm)
10	MNPM (n=3)	5E (>8 mm)	36 months	0
11	MXPM	3 (>2-4 mm)	10 months	0
12	MXA	3 (>2-4 mm)	18 months	0
13	MXA	4 (>4-8 mm)	13 months	1 (>0.5-1 mm)
14	MXPM	2 (>1-2 mm)	14 months	0
15	MXM	4D (>4-8 mm)	13 months	3 (>2-4 mm)
16	MNM	3 (>2-4 mm)	18 months	0
17	MXA (n=2)	3 (>2-4 mm)	14 months	0
18	MNM	3 (>2-4 mm)	14 months	0
19	MXA	2 (>1-2 mm)	15 months	0
20	MXA	4 (>4-8 mm)	13 months	0

CBCTPAI: cone beam computed tomography. MXA: maxillary anterior tooth; MNA: mandibular anterior tooth; MXPM: maxillary premolar; MNPM: mandibular premolar; MXM: maxillary molar; MNM: mandibular molar; m : month). In case 9*, after 22m it was detected fistula with suggestion of root fracture.

All specimens were fixed in 10% buffered formalin (pH 7.4) and paraffin-embedded. The microscopic features were evaluated by the analysis of one 5-µm section of each sample, stained routinely with hematoxylin and eosin.

Clinical and imaging monitoring has been proposed for the two groups of therapeutic protocols (primary lesions and persisting secondary lesions). The early lesions were evaluated according to the periapical index using CBCT scanning (Table 1) (14). Measures considered the largest diameter of the lesion as a reference for the CBCTPAI. For the monitoring of the therapeutic protocols, CBCT scan was not required when regression of AP was verified by conventional radiographic examination, but follow up for a longer period was proposed. The scores were adapted for the final outcome analysis in periapical radiographs (PR). The outcomes were evaluated by measurement of lesion extension.

Results

A total of 26 teeth presenting primary infection were conventionally treated and monitored from 10 to 36 months (Table 2). In 19 teeth was observed complete AP healing; in one case there was no regression of the AP (score 5) after 17 months; in one case was given initial score 5 and after 22 months it was scored 4 (fistula, suggesting root fracture); 4 cases changed from score 3-4 to score 1; in one case was detected change from score 4D to score 3.

Of 31 teeth that underwent periapical surgery (Table 3), 10 teeth had complete AP healing after 6-30 months of follow-up; 10 teeth showed almost complete healing of AP; in 8 teeth the periapical lesions were very extensive and after control showed decrease, but still exhibited high scores; three teeth were considered failures - one tooth was indicated for extraction due to root fracture; in one tooth, when the surgical field was opened, there were root cracks and persistent AP (also indicated for extraction); one tooth was indicated for a new surgical reintervention, due to persistence of AP after 24 months. In this case, the first histopathological analysis was periapical cyst, and the second was periapical granuloma. After 30 months of follow-up was detected complete AP healing.

Figures 1 and 2 show clinical aspects with primary and secondary infection undergoing both surgical and non-surgical managements, compatible with results of AP healing.

Discussion

The daily challenge of the endodontist includes preparing and sealing well the root canal and the

coronal structure, besides keeping the tooth in function. The healing of AP due to root canal infection represents the outcome expected after a RCT. The life of an endodontically treated tooth depends on the accuracy of the diagnosis and planning, excellence of sanitization, root canal preparation and filling, and final rehabilitation procedures (4). The clinical and radiographic follow-up of conventional RCT and surgical management in infected teeth improve the quality control of the adopted protocols and clinical studies.

In this prospective clinical study, high percentage of the AP healing process was detected in both types of infections. The effectiveness of adopted therapeutic strategies is in agreement with previous studies (7-9,12,13). In an RCT

follow up of 8 to 10 years, Sjögren et al. (7) evaluated the factors that affect the results. Based on the preoperative state of the pulp and of the periapical tissue, a 96% success rate was verified when there was no AP, 86% success when it was present, 98% success in the cases of retreatment without AP and 62% success in retreatment cases that presented AP. In the teeth with preoperative AP, when the instrumentation and filling of the root canal went up to 2 mm of the apex, the prognosis was significantly better than the cases of overfilling, or when the filling was more than 2 mm beyond the apex. Smith et al. (8) analyzed in a retrospective study the outcome of conventional RCT with a minimum follow up of 5 years. The

type of used sealing material had no demonstrable effect on success rate but gender, age, preoperative vitality and periapical pathology were associated with significantly different success rates. Technique also influenced success rate; the method of root canal preparation and the position of the apical seal relative to the radiographic apex were both found to be significant. The overall success rate was 84.29%. Friedman and Mor (9) reviewing literature, reported that the chance of teeth without AP to remain free of disease after initial treatment or orthograde retreatment is 92% to 98%. The chance of teeth with AP to completely heal after initial treatment or retreatment is 74% to 86%, and their chance to be functional over time is 91% to 97%. Thus there does not appear to be a systematic difference in outcome between initial treatment and orthograde retreatment. The chance of teeth with AP to completely heal after apical surgery is 37% to 85%, with a weighted average of approximately 70%. However, even with the lower chance of complete healing, the chance for the teeth to be functional over time is 86% to 92%.

In the present study, in both therapeutic strategies were also identified failures (Tables 1 and 2). Regardless of the correct standard of endodontic technique and careful

Table 3. Outcomes of surgical treatments in teeth with secondary infections and AP (n=31)

Case	Teeth	CBCTPAI	Microscopic Analysis	Follow-up	Outcome
1	MXA	5ED (>8mm)	PG	24m	0
2*	MNM	5 (>8mm)	PC/PG	30m	0
3	MXA	5D (>8mm)	PC	12m	1 (>0.5-1mm)
4	MXA (n=3),MXPM (n=2)	5D (>8mm)	PC	10m	0
5	MXM	5D (>8mm)	PG	7m	2 (>1-2mm)
6	MXPM	5D (>8mm)	PC	10m	0
7	MXA (n=2)	5E (>8mm)	PG	10m	1 (>0.5-1mm)
8*	MNA (n=4)	5 (>8mm)	--	8m	2 (>1-2mm)
9	MNA (n=3)	5ED (>8mm)	PG	12m	5 (> 8mm)
10	MXM	4 (>4-8mm)	PG	12m	0
11	MXA	5D (>8mm)	PG	12m	4 (>4-8mm)
12	MXA	5ED (>8mm)	PG	12m	1 (>0.5-1mm)
13	MXPM	4D (>4-8mm)	PG	12m	4 (>4-8mm)
14	MXPM	4 (>4-8mm)	PG	12m	3 (>2-4mm)
15	MXM	5 (>8mm)	PG	12m	3 (>2-4mm)
16	MXM	4D (>4-8mm)	PG	12m	0
17	MXA (n=2)	5D (>8mm)	PG	12m	4D (>4-8mm)
18*	MXM	4 (>4-8mm)	--	13m	3 (>2-4mm)
19**	MXA	5 (>8mm)	PG	10m	4 (>4-8mm)
20***	MXA	4 (>4-8mm)	PC	6m	1 (>0.5-1mm)

(MXA: maxillary anterior tooth; MNA: mandibular anterior tooth; MXPM: maxillary premolar; MNPM: mandibular premolar; MXM: maxillary molar; MNM: mandibular molar; m - month; PG: Periapical granuloma; PC: Periapical cyst)(In the case 8* and 18* it was verified that the material was insufficient for microscopic analysis; in case 2, it was made surgical procedure and the results show AP (PC) after follow-up. In a surgical reintervention after 30m the result was satisfactory (PG); in case 19* when was open the surgical field was observed presence of root cracks, thin walls which not permitted the root-end preparation and root-end filling, and after the control was verified the maintenance of AP; in case 20*, during the monitoring of 6m was verified the presence of longitudinal root fracture associated with periodontal pocket, with the subsequent history of dental trauma - condemned to extraction).

procedures, failures may occur. Certainly some areas of the root canal cannot be cleaned and filled, and the infection persisted (1,4). An anatomical structure that hampers full access to the root canal is the presence of isthmus. The isthmuses were well visualized by longitudinal map-reading dynamic from pulp orifice to the molar apexes using CBCT scans in a recent study (15). The presence of isthmus detected in maxillary molars was 86% in *ex vivo* assay and 62% *in vivo* assay, whereas in mandibular molars was observed 70% in *ex vivo* assay and 72% *in vivo* assay. The map-reading dynamics in CBCT images was found to be precise to detect the localization of isthmus. The isthmus which begins in cervical third is more easily accessed by cervical pre-flaring, mechanical action of rotary instruments or ultrasound. In root isthmus that begins in the middle third and ends in apical third or when begins and ends in apical third, the challenge is the access into these areas (15). The clinical implication of this finding involves the difficulty of sanitization, mechanical action to disrupt the bacterial biofilms or cleaning these inaccessible areas. Thus, a strict strategy of irrigation and intracanal dressing for better bacterial control is recommended (4,15).

In the present study, for the RCT with primary infection and AP, the root canals were prepared 1 mm short of the apical foramen and a calcium hydroxide paste was maintained for 21 days. A successful RCT was observed in 19/26 cases with complete AP healing (5/26 with partial repair) in 10-36 months follow up. For the surgically managed cases, the efficacy of surgical therapy was

detected in 10/31 cases with complete healing (10/31 cases with partial repair) in 6-30 months follow up. The monitoring of root canal infections treatment for a longer period of time is important, since many cases still show up with partial repair, and due to the AP dimension, the time for the follow-up may not be sufficient for a complete healing. Østavik (16) followed clinically and radiographically 732 RCT with and without preoperative chronic AP yearly for up to 4 years. Complete healing of preoperative chronic AP in some occasions required 4 years for completion, while signs of initiated, but incomplete, healing were visible in at least 89% of all healing roots after 1 year. Risk analyses may provide relevant information in addition to or in substitution for success/failure analyses.

One aspect involved in improving outcomes is intimately associated with the adoption of standard clinical protocols of excellence (4). Ng et al. (17) discussed the influence of clinical factors on the outcome of primary root canal treatment using systematic review. Four conditions (pre-operative absence of periapical radiolucency, root filling with no voids, root filling extending to 2 mm within the radiographic apex and satisfactory coronal restoration) were found to improve significantly the outcome of primary root canal treatment.

A limiting factor in this clinical study was the small number of patients who returned for follow up treatments and who obeyed the proposed return schedule, difficulty also reported in previous studies (18-20). Liang et al. (18) evaluating factors that might affect the outcome of RCT in

C. Estrela et al.

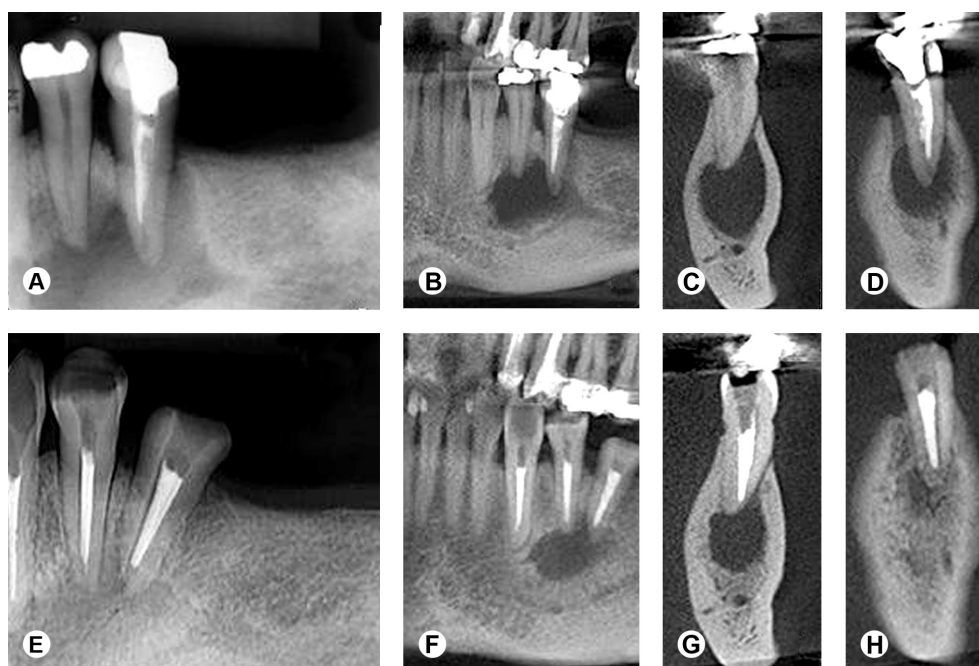


Figure 1. Composite image of periapical radiographs and CBCT scans of mandibular premolars and canine associated with large AP and primary and secondary infections (A-H). After 36 months of follow up of conventional root canal treatment, healing in process was detected by CBCT images.

retrospective study with follow up of 2 years had a recall rate of 36%. The authors reported that the low recall rates might reduce the impact of clinical outcome studies.

For persistent infections a viable alternative is periapical surgery. Considering the cases of surgically treated persistent infections in this study, the results of the histopathological analysis revealed in most cases the presence of periapical granulomas. The types and incidences of periapical lesions obtained from 156 extracted human teeth were evaluated (2) and it was observed that 50% were granulomas, 69 (55%) not epitheliated and 58 (45%) epitheliated; and 15% were periapical cysts (61% true cysts and 39% periapical pocket cysts).

CBCT images provide the opportunity of reading by mapping, with information by a dynamic display in diverse planes, which influenced the accuracy of diagnosis, planning and therapeutic protocol. In the present study, first was used CBCTPAI to evaluate AP. This periapical index has been applied in other studies (21,22). During the

follow-up after RCT or surgical procedure when periapical radiograph (PR) showed complete healing or vestiges of healing of AP, the scores were adapted for the final analysis in PR. The limitations of PR compared with CBCT images (14,15,18,19,23,24) must be considered; however, vestiges of healing of AP by PR were detected. Cases with complete healing of AP using PR were identified at different periods of time, indifferent to the initial diameter of the lesion. Fernández et al. (24) evaluated the outcome of RCT measured by PR, digital periapical radiographic (DPR), and CBCT in a 5-year follow up. Of the 17 evaluated prognostic factors, 4 were associated with poor outcome of the treatment: root canal curvature, disinfection of gutta-percha, presence of missed canals and the quality of definitive coronal restoration. The success of RCT after 5 years in teeth with vital pulps varied with each imaging method: 94.3%-PR, 92.3%-DPR, and 81.3%-CBCT.

Considering that the aim of this study was to monitor surgical and nonsurgical RCT of teeth with primary and

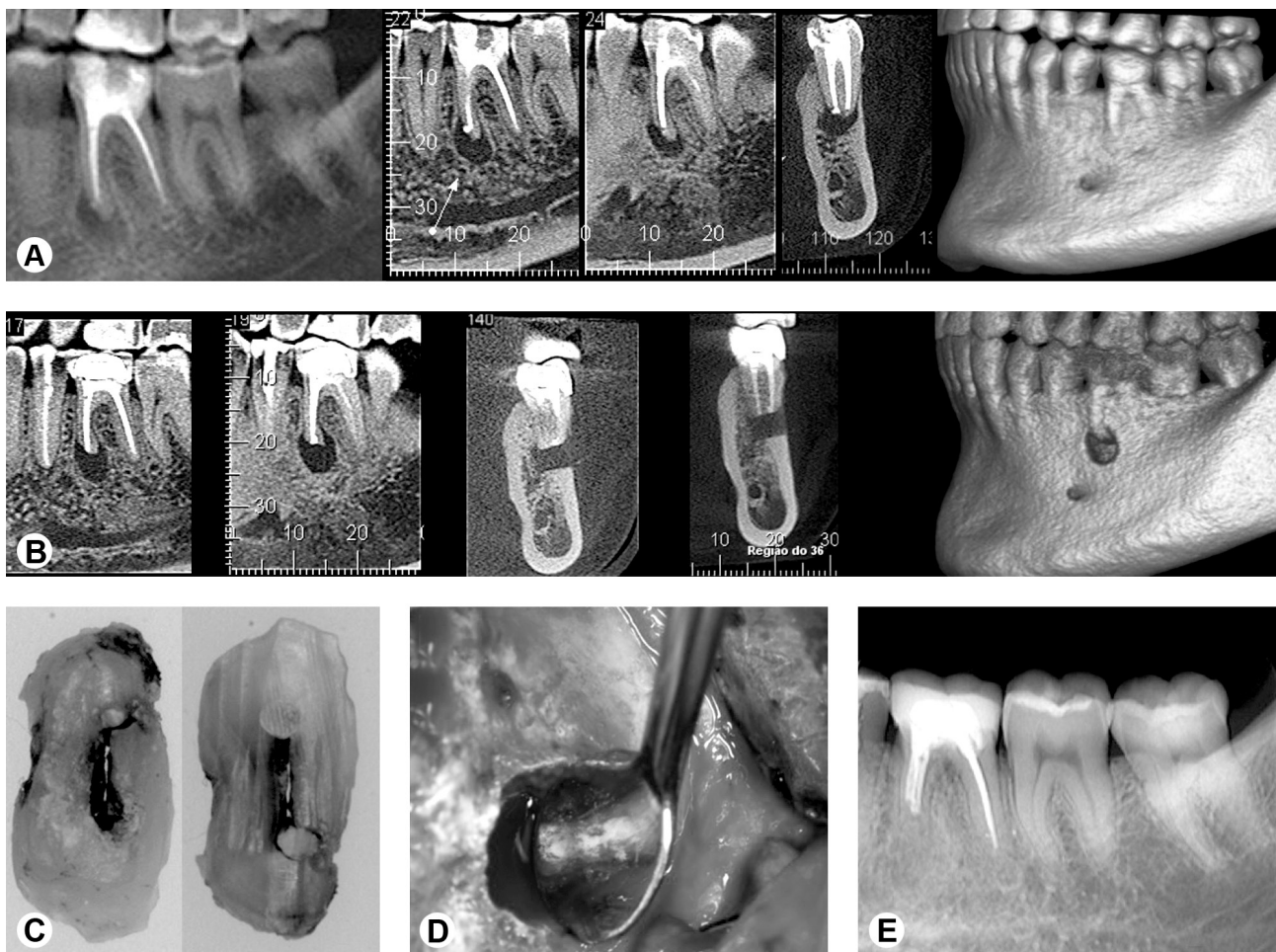


Figure 2 (A-E) - CBCT scans show first mandibular molar right that due persistence of infection was detected failure of retreatment (A). After 24 months follow-up of the periapical surgical, and due to maintenance of AP (B), a new surgical reintervention was proposed. In this moment, it was observed area of the isthmus (C). After removing of the apical root-end and the periapical lesion, and filling the isthmus area with MTA (D), the surgical cavity was filled with biomaterial (Bio-Oss®). In the new follow-up was observed healing in process of AP (E).

secondary infections and AP, the outcomes of therapeutic protocols were not compared. However, whenever possible, non-surgical retreatment must be the first choice for failures of RCT. Sundqvist et al. (25) verified the microbiota present in teeth after failed RCT and established the outcome of 45 root-filled teeth with persisting periapical lesions. The results showed mainly single species of predominantly Gram-positive organisms. The most commonly recovered isolates were bacteria of the *Enterococcus faecalis* species. The overall success rate of re-treatment was 74%. Infection at the time of root filling and size of the periapical lesion were factors that had a negative influence on the prognosis. Three of four endodontic failures were successfully managed by re-treatment. Del Fabbro et al. (10) considered a systematic review to analyze the results of surgical and non-surgical therapy for retreatment of AP. It was reported that there is little evidence for a decision-making process. Well-designed randomized controlled trials should be conducted with monitoring of at least four years, and a sample size consistent for detecting a true difference between the long term results of two alternative treatments. Torabinejad et al. (11) compared the success rates of nonsurgical endodontic retreatment with those of periapical surgery using systematic review. It appears that periapical surgery shows more favorable initial healing, which declines with increasing recall periods. Nonsurgical retreatment offers a more favorable long-term outcome. Limited amount of comparative evidence was observed and there is an apparent need for high-quality randomized controlled trials.

The outcome of RCT has been discussed by Wu et al. (19). In clinical studies, two factors may have further added to the overestimation of successful outcomes after RCT: extractions and re-treatments were rarely recorded as failures; and the recall rate was often lower than 50%. Systematic reviews reporting the success rates of RCT without referring to these limitations may mislead readers. The outcomes of RCT should be re-evaluated in long-term longitudinal studies using CBCT and stricter evaluation criteria.

Two cases are reported to illustrate this study. Figure 1 shows a clinical report with mandibular premolars and canine associated with large AP, and primary and secondary infections. After conventional RCT and 36 months of follow up complete healing was detected by PR and partial healing by CBCT images. Figure 2 presents a clinical report that the probable persistence of infection in isthmus area was the main cause of failure of root canal retreatment. Surgical intervention was indicated. After 24 months follow up of the periapical surgery, and due to maintenance of AP, a new surgical reintervention was proposed. At this moment was observed the area of isthmus. After removing of the apical

root-end, the periapical lesion and filling the isthmus area with MTA, in the new follow up was observed complete regression of AP by CBCT scans. The first histopathological analysis was periapical cyst, and the second was periapical granuloma.

The difficulty of comparing the results of this study with others include the standard of the proposed therapeutic strategies; the standardization of the apical limit; the anatomic diameter for enlargement; the technique protocol - irrigant solution, intracanal dressing, root canal filling material; type of tooth and size of the selected sample; the return of the patients; time and type of infection; the criteria for the detection and evaluation of periapical lesion, among others. In order to increasingly minimize all these variables that may affect the impact of clinical studies, monitoring of therapeutic protocols applied in the root canal infections allows incorporating habits in professionals and patients to follow the treatments. The estimates of prognosis for root canal diseases may only be deduced when the treatment outcomes are properly and impartially analyzed. Despite of the limitations of this study, monitoring the outcomes of surgical and nonsurgical RCT of infected teeth showed elevated levels of success in both therapeutic protocols. Failures were detected despite rigorous standard clinical protocol.

Resumo

O objetivo do estudo foi monitorar tratamentos de canais radiculares (TCR) convencionais e com auxílio de cirurgia periapical. Este estudo prospectivo constituiu de 80 pacientes portadores de infecções primárias e secundárias persistentes e periodontite apical (PA). O índice periapical utilizando tomografia computadorizada de feixe cônico (CBCTPAI) foi utilizado como auxiliar no diagnóstico, planejamento e para determinar a melhor estratégia terapêutica. Apenas 40 pacientes retornaram para o TCR. Em 20 pacientes (26 dentes) com diagnósticos de infecções primárias e PA foram feitos TCR convencionais e monitoramentos por 10 a 36 meses. Em 20 pacientes (31 dentes) com diagnósticos de infecções secundárias persistentes foram submetidos a procedimentos cirúrgicos e acompanhamentos durante 6 a 30 meses. Os resultados mostraram TCR bem sucedidos em 19 de 26 casos, com curas completas das PA (5 de 26 com reparação parcial) em controles de 10 a 36 meses. Para os casos de tratamentos cirúrgicos foram detectadas eficácias das terapêuticas cirúrgicas em 10 de 31 casos com curas completas (10 de 31 casos com reparação parcial) em controles de 6 a 30 meses. O retorno dos pacientes para controle clínico e radiográfico e a obediência ao período de tempo proposto está muito aquém do ideal. Os níveis de sucesso em ambos os protocolos terapêuticos se mostraram elevados. Fracassos no TCR foram detectados mesmo utilizando protocolo clínico com rigoroso padrão.

Acknowledgements

This study was supported in part by grants from the National Council for Scientific and Technological Development (CNPq grant 302875/2008-5; CNPq grant 306394/2011-1 to C.E.).

References

1. Nair PNR. Pathogenesis of apical periodontitis and the causes of endodontic failures. Crit Rev Oral Biol Med 2004;15:348-381.

2. Nair PNR, Pajarola G, Schroeder HE. Types and incidence of human periapical lesions obtained with extracted teeth. *Oral Surg Oral Med Oral Pathol* 1996;81:93-102.
3. Faitaroni LA, Bueno MR, Carvalhosa AA, Ale KAB, Estrela C. Ameloblastoma suggesting large apical periodontitis. *J Endod* 2008;34:216-219.
4. Estrela C, Holland R, Estrela CRA, Alencar AHG, Sousa-Neto MD, Pécora JD. Characterization of successful root canal treatment. *Braz Dent J* 2014;25:3-11.
5. Strindberg LZ. The dependence of the results of pulp therapy on certain factors. An analytical study based on radiographic and clinical follow-up examinations. *Acta Odontol Scand* 1956;14:1-174.
6. Bender IB, Seltzer S, Soltanoff W. Endodontic success – a reappraisal of criteria. *Oral Surg Oral Med Oral Pathol* 1966;22:780-801.
7. Sjögren U, Hagglund B, Sundqvist G, Wing K. Factors affecting the long-term results of endodontic treatment. *J Endod* 1990;16:498-504.
8. Smith CS, Setchell DJ, Harty FJ. Factors influencing the success of conventional root canal therapy--a five-year retrospective study. *Int Endod J* 1993;26:321-333.
9. Friedman S, Mor C. The success of endodontic therapy: healing and functionality. *J Calif Dent Assoc* 2004;32:493-503.
10. Del Fabbro M, Taschieri S, Testori T, Francetti L, Weinstein R. Surgical versus non-surgical endodontic re-treatment for periradicular lesions. *Cochrane Database Syst Rev* 2007:CD005511.
11. Torabinejad M, Corr R, Handysides R, Shabahang S. Outcomes of nonsurgical retreatment and endodontic surgery: a systematic review. *J Endod* 2009;35:930-937.
12. Imura N, Pinheiro ET, Gomes BP, Zaia AA, Ferraz CC, Souza-Filho FJ. The outcome of endodontic treatment: a retrospective study of 2000 cases performed by a specialist. *J Endod* 2007;33:1278-1282.
13. Estrela C, Leles CR, Hollanda ACB, Moura MS, Pécora JD. Prevalence and risk factors of apical periodontitis in endodontically treated teeth in a selected population of Brazilian adults. *Braz Dent J* 2008;19:34-39.
14. Estrela C, Bueno MR, Azevedo B, Azevedo JR, Pécora JD. A new periapical index based on cone beam computed tomography. *J Endod* 2008;34:1325-1331.
15. Pécora JD, Estrela C, Bueno MR, Porto OC, Alencar AHG, Sousa-Neto MD, et al.. Detection of root canal isthmuses in molars by map-reading dynamic using CBCT images. *Braz Dent J* 2013;24:569-574.
16. Østavik D. Time-course and risk analyses of the development and healing of chronic apical periodontitis in man. *Int Endod J* 1996;29, 150-155.
17. Ng Y-L, Mann V, Rahbaran S, Lewsey J, Gulabivala K. Outcome of primary root canal treatment: systematic review of the literature – Part 2. Influence of clinical factors. *Int Endod J* 2008;41:6-31.
18. Liang YH, Li G, Wesselink PR, Wu MK. Endodontic outcome predictors identified with periapical radiographs and cone-beam computed tomography scans. *J Endod* 2011;37:326-331.
19. Wu MK, Shemesh H, Wesselink PR. Limitations of previously published systematic reviews evaluating the outcome of endodontic treatment. *Int Endod J* 2009;42:656-666.
20. Wu MK, Wesselink P, Shemesh H. New terms for categorizing the outcome of root canal treatment. *Int Endod J* 2011;44:1079-1080.
21. Esposito S, Cardaropoli M, Cotti E. A suggested technique for the application of the cone beam computed tomography periapical index. *Dentomaxillofacial Radiol* 2011;40:506-512.
22. Pope O, Sathorn C, Parashos P. A comparative investigation of cone-beam computed tomography and periapical radiography in the diagnosis of a healthy periapex. *J Endod* 2014;40:360-365.
23. Moura MS, Guedes OA, Alencar AHG, Azevedo B, Estrela C. Influence of length of root canal obturation on apical periodontitis detected by periapical radiography and cone beam computed tomography. *J Endod* 2009;35:805-809.
24. Fernández R, Cadavid D, Zapata SM, Alvarez LG, Restrepo FA. Impact of three radiographic methods in the outcome of nonsurgical endodontic treatment: A five-year follow-up. *J Endod* 2013;39:1097-1103.
25. Sundqvist G, Figdor D, Persson S, Sjögren U. Microbiologic analysis of teeth with failed endodontic treatment and the outcome of conservative re-treatment. *Oral Surg Oral Med Oral Pathol Oral Radiol Endod* 1998;85:86-93.

*Received January 10, 2014
Accepted September 30, 2014*