

# Ossifying Fibroma of the Jaws: A Clinicopathological Case Series Study

Márcia de Andrade, Yara Teresinha Corrêa Silva-Sousa, Maria Fernanda Teiga Marques, Maria Luiza dos Anjos Pontual, Flávia Maria de Moraes Ramos-Perez, Danyel Elias da Cruz Perez

Department of Clinical and Preventive Dentistry, School of Dentistry, UFPE - Federal University of Pernambuco, Recife, PE, Brazil

Correspondence: Prof. Dr. Danyel Elias da Cruz Perez, Avenida Prof. Moraes Rego, 1235, Cidade Universitária, 50670-901 Recife, PE, Brazil. Tel: +55-81-2126-7510. e-mail: danyel.perez@ufpe.br

The aim of this study was to assess the clinical, radiographic and microscopic features of a case series of ossifying fibroma (OF) of the jaws. For the study, all cases with OF diagnosis from the files of the Oral Pathology Laboratory, University of Ribeirão Preto, Ribeirão Preto, SP, Brazil, were reviewed. Clinical data were obtained from the patient files and the radiographic features were evaluated in each case. All cases were reviewed microscopically to confirm the diagnosis. Eight cases were identified, 5 in females and 3 in males. The mean age of the patients was 33.7 years and most lesions (7 cases) occurred in the mandible. Radiographically, all lesions appeared as unilocular images and most of them (5 cases) were of mixed type. The mean size of the tumor was 3.1 cm and 3 cases caused displacement of the involved teeth. Microscopically, all cases showed several bone-like mineralized areas, immersed in the cellular connective tissue. From the 8 cases, 5 underwent surgical excision and 1 patient refused treatment. In the remaining 2 cases, this information was not available. In conclusion, OF occurs more commonly in women in the fourth decade of life, frequently as a mixed radiographic image in the mandible. Coherent differential diagnoses are important to guide the most adequate clinical approach. A correlation between clinical, imaginological and histopathological features is the key to establish the correct diagnosis.

Key Words: case series, differential diagnosis, ossifying fibroma, radiographic features.

## Introduction

Fibro-osseous lesions is a term used for a group of diseases of the jaws in which the normal bone tissue is replaced by fibroblasts and fibrous tissue, with formation of variable amounts of mineralized material (1). This term does not represent a specific diagnosis. Fibrous dysplasia, osseous dysplasia and ossifying fibroma compose the group of fibro-osseous lesions. Despite the similarities in clinical, radiographic and histopathological features of these lesions, these lesions are of distinct nature (1). Osseous dysplasia and fibrous dysplasia are reactive lesions while ossifying fibroma is a true neoplasm. In consequence, the fibro-osseous lesions present different biological behavior (1,2). Thus, a correct final diagnosis is essential.

The ossifying fibroma (OF) is a benign neoplasm that affects the jaws. This lesion occurs more often in females in the third and fourth decades of life. Usually, OF appears as a single, painless and slow-growing lesion, mostly found in the posterior region of the mandible, specifically in the premolars and molars area (2,3).

Radiographically, OFs present as a unilocular and well-circumscribed image, initially radiolucent, and as they progress, appear as mixed lesions, with radiolucent and radiopaque areas. The older lesions are radiopaque and surrounded by a radiolucent halo (2,4). Microscopically, this neoplasm is composed of a proliferation of benign spindle cells, forming a cellular connective tissue and a mineralized

tissue similar to bone or cementum (5).

The treatment consists in completely removing the lesion with curettage, surgical excision or en-block resection, depending on the size and location of the lesion (3,4). In lesions with a fibrous capsule around, the surgical excision may be performed more easily (6). Recurrences are rarely observed (2,4).

OF is an uncommon lesion and few series of cases have been published (2,4,7,8). Thus, the aim of this study was to assess the clinical, radiographic and microscopic features in an OF case series.

## Material and Methods

Between 2000 and 2010, all cases of ossifying fibroma diagnosed at the Oral Pathology Laboratory, University of Ribeirão Preto, SP, Brazil, were analyzed. Clinical data such as age, gender and time of complaints of the patients, location and size of the tumor were obtained from the patient files in the Laboratory. The radiographic features were evaluated in each case. Cases with incomplete data were excluded.

After biopsy or surgical treatment, the specimens were fixed in 10% formaldehyde solution for 24 h. For conventional histological processing, the tissues were dehydrated in increasing concentrations of ethanol, immersed in xylene and then embedded in paraffin.

Histological 5- $\mu$ m-thick sections were obtained from paraffin-embedded tissue blocks and stained with hematoxylin-eosin. All cases were microscopically reviewed to confirm the diagnosis. The diagnosis was established based on the clinical, radiographic and histopathological features.

## Results

Eight cases of ossifying fibroma were diagnosed. There were 5 women and 3 men. The mean age of the patients was 33.7 years (ranging from 13.0 to 49.0 years). Most lesions (7 cases, 87.5%) occurred in the mandible; 4 of them occurred in the anterior region and 3 in the posterior region. In the diagnosis, the mean time of complaints was 37 months (ranging from 2.0 to 60.0 months). Four patients (50%) reported painless swelling in the affected region (Fig. 1). One case (12.5%) reported mild pain without swelling and another reported tooth displacement. The information on complaints was not available in 2 cases. The clinical and epidemiological data are summarized in Table 1.

Radiographically, most cases (5 cases, 62.5%) showed

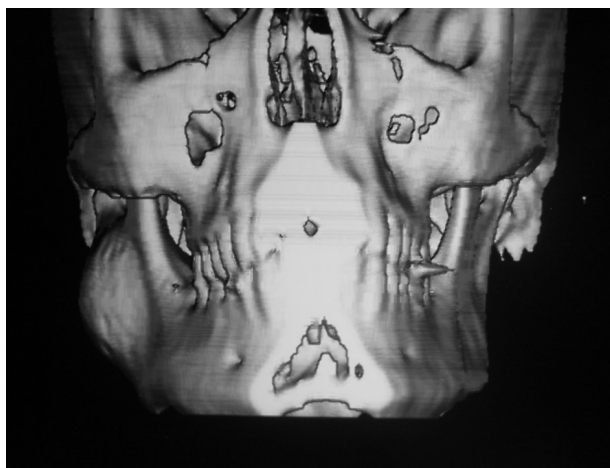


Figure 1. 3D reconstruction from multiple images reveals swelling in the affected area (case 6).

Table 1. Clinical and epidemiological data of ossifying fibroma of the jaws

Case	Age (years)	Gender	Duration (months)	Patient complaint	Site
1	40	Female	5.0	Mild pain	AMD
2	13	Male	2.0	Tooth displacement	AMX
3	49	Male	20.0	NA	PMD
4	NA	Female	2.0	NA	AMD
5	46	Female	60.0	Painless swelling	PMD
6	17	Male	NA	Painless swelling	PMD
7	51	Female	60.0	Painless swelling	AMD
8	20	Female	8.0	Painless swelling	AMD

\*NA: Not available. AMX: Anterior maxilla. AMD: Anterior mandible. PM: Posterior mandible.

mixed images, and all lesions were unilocular and well circumscribed (Figs. 2 and 3). The mean size of the lesions was 3.0 cm (ranging from 1.0 to 6.0 cm). Three cases (37.5%) caused dental displacement (cases 2, 5 and 8). One case (case 1) was located in the periapical region of the right mandibular canine that was endodontically treated. In this case, the lesion extended into the apical region of the adjacent lateral incisor. The patient complained of slight pain, exacerbated during palpation. Table 2 shows the main radiographic features.

Microscopically, all cases were composed of connective tissue of mixed and variable cell types, with a mineralized component that consisted of trabecular or woven bone. Osteoblastic rimming was commonly observed (Fig. 4).

Most cases (5 cases) were treated by surgical excision of the lesion. However, one patient refused treatment and in 2 cases this information was not available.

## Discussion

In fibro-osseous lesions, the presence of a mineralized

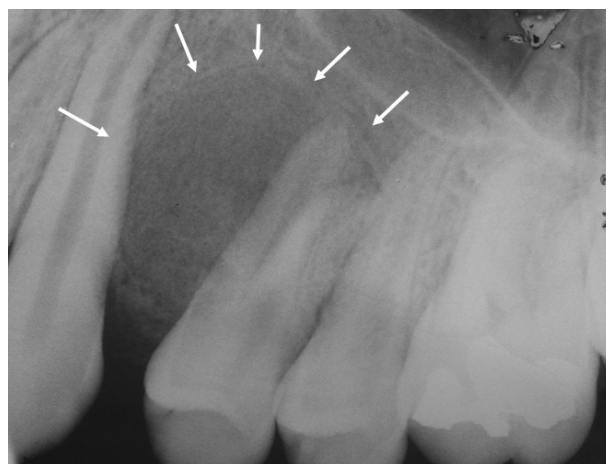


Figure 2. Well-delimited mixed radiographic image causing displacement of the involved teeth (case 2).

Table 2. Radiographic features of all ossifying fibroma cases

Case	Radiographic feature	Radiographic density	Size (cm)
1	Unilocular	Radiolucent	1.0
2	Unilocular	Mixed	2.0
3	Unilocular	NA*	NA
4	Unilocular	Mixed	2.0
5	Unilocular	Radiopaque	1.0
6	Unilocular	Mixed	6.0
7	Unilocular	Mixed	5.0
8	Unilocular	Mixed	4.0

\*NA: Not available

tissue with spheroid-laminated appearance is described as similar to cementum. However, cementum is a bone-like mineralized tissue deposited on the root surface of a tooth. Therefore, in addition to the mineralized tissue structure, the anatomic site is essential to characterize the cementum (8). Currently, the World Health Organization recommends the use of ossifying fibroma and osseous dysplasia, replacing the cement-ossifying fibroma and cement-osseous dysplasia, which exclude the term "cementum" (9).

The OF is a relatively rare benign tumor that affects the mandible and maxilla. Although OF appears as a single slow growth lesion (2,4), a few cases of multiple tumors have been reported (10). These lesions are more frequent in women and occur more commonly between the third and fourth decades of life (2,5,11), similar to the current case

series. However, 3 cases occurred in young patients. In the present study, all but one case occurred in the mandible, as observed by several authors (2,7). Nevertheless, in contrast to most studies in the literature (2,4,7), in this series, almost half of the mandibular cases affected the posterior region. Chang et al. (2) found that 61% of the cases affected the posterior region of the mandible. This divergence may be due to differences in the number of cases in previously published series or eventual geographic aspects when comparing series published around the world (2,4,6).

Swelling in the affected region is the most common clinical sign observed in patients with OF. They are usually painless and eventually identified in routine radiographic examination (3). From the 8 cases presented in this study, most of them exhibited swelling on the tumor site and

only one reported mild pain. OF may cause tooth displacement and root resorption in adjacent teeth (12). In the current series, 3 cases presented tooth displacement, which was the main complaint in one case. No root resorption was observed.

Radiographically, the features of OF may vary depending on the amount of mineralized tissue within the tumor. OFs usually appear as unilocular, well-delimited lesions, with variable amount of radiopaque foci inside the lesion (1). Consequently, a mixed radiographic image is commonly observed (2,7). In the present series, 62.5% of the lesions showed mixed images. Computerized tomography (CT) is essential for a complete evaluation of the lesions. In panoramic radiographic examination, case 6 showed a predominantly radiolucent image. On the other hand, a CT image revealed an unequivocal mixed image located in the right mandibular ramus. Based on this additional information, several image examinations should be used for the correct assessment and diagnosis of intra-osseous lesions. However, as this series was based on data from an oral pathology laboratory, the analysis of additional image examinations could not be performed. Enlargement of the OF may increase the amount of mineralized material inside the

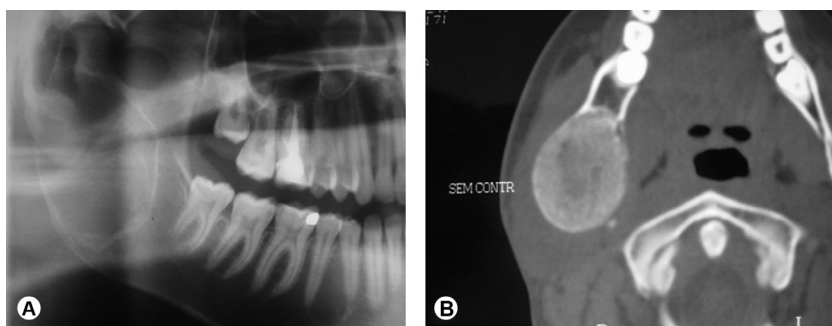


Figure 3. Case 6. A: Well-delimited large radiolucent image located in the right mandibular ramus. B: CT scan showing well-circumscribed mixed image.

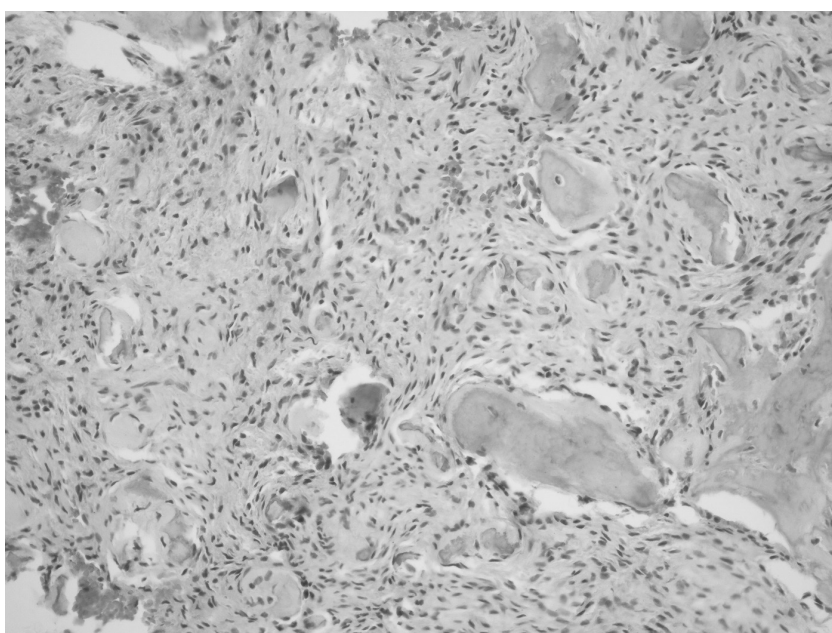


Figure 4. Mineralized material composed by woven bone interspersed by cellularized connective tissue (HE, original magnification 100x).

tumor. Nevertheless, the use of the term maturation to characterize this phenomenon in neoplastic lesions is controversial. Neoplasms have an unlimited growth and do not mature from a biological perspective. This term should be used preferentially for dysplastic lesions like the osseous dysplasias (8).

OF is classified as a maxillofacial fibro-osseous lesion. Fibrous dysplasia and osseous dysplasia are other conditions considered in the group of fibro-osseous lesions (8,11). Fibrous dysplasia is the main lesion in the differential diagnosis of OF (4). Radiographically, fibrous dysplasia usually appears as a diffuse, homogeneous ground-glass, radiodense region, whereas the OF shows a well-demarcated mixed radiolucent and radiopaque image (11,13), as observed in all cases from this series, which were well-circumscribed and separated from the cortical bone. Osseous dysplasia may appear in three different clinico-radiographic patterns, namely florid, focal or periapical osseous dysplasia (9,14). Among the osseous dysplasias, focal osseous dysplasia (FOD), in early, intermediate and late stage, is an important differential diagnosis for OF (2). Differently from OF, FOD occurs more frequently in patients during the fourth and fifth decades of life and usually presents ill-defined radiographic borders. Moreover, the lesions in FOD are smaller than in OF and affect more frequently the periapical region (6). In this series, case 1 is located in the periapical region. In the present case, although the lesion presented a small dimension, it extended into the apical region of the adjacent lateral incisor. Additionally, the patient complained of slight pain, which was exacerbated during palpation. These features strongly suggested lesion growth. In contrast, most FOD are fully asymptomatic and diagnosed in a routine radiographic examination (13,15,16).

Apart from the fibro-osseous lesions, other diseases may be included in the differential diagnosis of OF. In fact, the differential diagnosis depends on the radiographic features of the lesion. In OF, it appears as a radiolucent image, odontogenic cysts, ameloblastoma, central giant cell lesions, chronic apical periodontitis and idiopathic bone cavity (2). For mixed lesions, osteoblastoma, calcifying cystic odontogenic tumor and calcifying epithelial odontogenic tumor should be considered in the differential diagnosis (2). Finally, for radiopaque OF, complex odontoma and idiopathic osteosclerosis are the main differential diagnoses. OF may also resemble a cementoblastoma if it occurs around the tooth root (4); however, cementoblastoma is fused to the tooth root. In large OFs, osteosarcoma may be also considered in the clinico-radiographic diagnosis, since osteosarcomas of the jaws affect patients in a similar age range (17).

Microscopically, OF consists in a cellular connective

tissue that presents mineralized material, with an osteoblastic rimming commonly observed on the surface of the mineralized tissue (15), similar to observed in most cases of this current series. Recently, a study demonstrated that the presence of peritrabecular cleaving in fibrous dysplasia is an important histopathological feature for distinguishing fibrous dysplasia from OF (18). Moreover, considering fibro-osseous lesions, mainly the fibrous dysplasia, the presence of mutations at the Arg201 codon of the alpha subunit of the stimulatory G protein is observed only in fibrous dysplasia (19).

Juvenile trabecular fibroma (JTOF) and juvenile psammomatoid ossifying fibroma (JPOF) are other histological OF types. In contrast with conventional OF, JTOF and JPOF occur most commonly in the maxilla and bony walls of paranasal sinuses, respectively. Both present predilection for patients up to the second decade of life. JTOFs usually show an aggressive and rapid growth (13,15), different from the ones in the current study.

The treatment of ossifying fibroma is a complete removal by curettage or excision (2,4). In this study, five of the lesions were submitted to surgical excision. One patient refused treatment and in two cases information on the treatment was not available. After treatment, recurrences are rare.

In conclusion, OF occurs more commonly in women in the fourth decade of life, frequently as a mixed radiographic image in the mandible. Coherent differential diagnoses are important to guide the most adequate clinical approach. A correlation between clinical, imaginological and histopathological features is the key to establish the correct diagnosis.

## Resumo

O objetivo deste estudo foi analisar as características clinico-radiográficas e microscópicas de uma série de casos de fibroma ossificante (FO). Para o estudo, todos os casos com diagnóstico de FO do arquivo do Laboratório de Patologia Bucal da Universidade de Ribeirão Preto, Ribeirão Preto, São Paulo, Brasil, foram estudados. Os dados clínicos foram coletados das fichas de encaminhamento das lesões ao Laboratório. As características radiográficas foram avaliadas em cada caso. Todos os casos foram revisados microscopicamente para confirmação do diagnóstico. Oito casos foram identificados, 5 em mulheres e 3 em homens. A idade média dos pacientes foi de 33,7 anos e a maioria das lesões (7 casos) ocorreu na mandíbula. Radiograficamente todas as lesões se apresentavam como imagens uniloculares e a maioria (5 casos) se mostravam como imagem mista. O tamanho médio do tumor foi de 3,1 cm e 3 casos causavam deslocamento dos dentes envolvidos. Microscopicamente, todos os casos apresentavam várias áreas mineralizadas semelhantes a osso, imersas em um tecido conjuntivo celularizado. Dos 8 casos, 5 foram submetidos a excisão cirúrgica da lesão e 1 paciente recusou tratamento. Nos outros 2 casos, essa informação não estava disponível. Conclui-se que os FOs ocorrem mais comumente na mandíbula de pacientes do gênero feminino durante a quarta década de vida e se apresentam frequentemente como uma imagem radiográfica mista. Diagnósticos diferenciais coerentes são importantes para guiar a conduta clínica mais adequada. A correlação entre as características clínicas, imaginológicas e histopatológicas é a



chave para estabelecer o diagnóstico correto.

## References

1. Gondivkar SM, Gadbañal AR, Chole R, Parikh RV, Balsaraf S. Ossifying fibroma of the jaws: report of two cases and literature review. *Oral Oncol* 2011;47:804-809.
2. Chang CC, Hung HY, Chang JY, Yu CH, Wang YP, Liu BY, Chiang CP. Central ossifying fibroma: a clinicopathologic study of 28 cases. *J Formos Med Assoc* 2008;107:288-294.
3. Vegas Bustamante E, Gargallo Albiol J, Berini Aytés L, Gay Escoda C. Benign fibro-osseous lesions of the maxillas: analysis of 11 cases. *Med Oral Patol Oral Cir Bucal* 2008;13:E653-E656.
4. Triantafyllidou K, Venetis G, Karakinaris G, Iordanidis F. Ossifying fibroma of the jaws: a clinical study of 14 cases and review of the literature. *Oral Surg Oral Med Oral Pathol Oral Radiol* 2012;114:193-199.
5. de Moraes Ramos-Perez FM, Soares UN, Silva-Sousa YT, da Cruz Perez DE. Ossifying fibroma misdiagnosed as chronic apical periodontitis. *J Endod* 2010;36:546-548.
6. Su L, Weathers DR, Waldron CA. Distinguishing features of focal cementoosseous dysplasia and cemento-ossifying fibromas II. A Clinical and radiologic spectrum of 316 cases. *Oral Surg Oral Med Oral Pathol Oral Radiol Endod* 1997;84:540-549.
7. de Noronha Santos Netto J, Machado Cerri J, Miranda AM, Pires FR. Benign fibro-osseous lesions: clinicopathologic features from 143 cases diagnosed in an oral diagnosis setting. *Oral Surg Oral Med Oral Pathol Oral Radiol* 2013;115:e56-e65.
8. Noffke CE, Raubenheimer EJ, MacDonald D. Fibro-osseous disease: harmonizing terminology with biology. *Oral Surg Oral Med Oral Pathol Oral Radiol* 2012;114:388-392.
9. Barnes L, Eveson JW, Reichart P, Sidransky D, eds. *Pathology & Genetics of Head and Neck Tumors*. Lyon: IARC Press, 2005
10. Ribeiro AC, Carlos R, Díaz KP, Gouvêa AF, Vargas PA. Bilateral central ossifying fibroma affecting the mandible: report of an uncommon case and critical review of the literature. *Oral Surg Oral Med Oral Pathol Oral Radiol Endod* 2011;111:e21-e26.
11. McCarthy EF. Fibro-osseous lesions of the maxillofacial bones. *Head Neck Pathol* 2013;7:5-10.
12. White SC, Pharoah MJ. *Oral radiology principles and interpretation*. 5th ed. Mosby; 2004. p. 498-501.
13. Slootweg PJ. Lesions of the jaws. *Histopathology* 2009;54:401-418.
14. Gündüz K, Avsever H, Karaçaylı U, Senel B, Piskin B. Florid cemento-osseous dysplasia: a case report. *Braz Dent J* 2009;20:347-350.
15. Slootweg PJ. Osseous dysplasia. In: Barnes L, Eveson JW, Reichart P, Sidransky D, eds. *Pathology & Genetics Head and Neck Tumors*. Lyon: IARC Press; 2005. p. 323.
16. Eversole R, Su L, El Mofly S. Benign fibro-osseous lesions of the craniofacial complex. A review. *Head and Neck Pathol* 2008;2:177-202.
17. Junior AT, de Abreu Alves F, Pinto CA, Carvalho AL, Kowalski LP, Lopes MA. Clinicopathological and immunohistochemical analysis of twenty-five head and neck osteosarcomas. *Oral Oncol*. 2003;39:521-530.
18. Prado Ribeiro AC, Carlos R, Speight PM, Hunter KD, Santos-Silva AR, de Almeida OP, et al.. Peritrabecular clefting in fibrous dysplasia of the jaws: an important histopathologic feature for differentiating fibrous dysplasia from central ossifying fibroma. *Oral Surg Oral Med Oral Pathol Oral Radiol* 2012;114:503-508.
19. Toyosawa S, Yuki M, Kishino M, Ogawa Y, Ueda T, Murakami S, et al.. Ossifying fibroma vs fibrous dysplasia of the jaw: molecular and immunological characterization. *Mod Pathol* 2007;20:389-396.

Received April 4, 2013  
Accepted November 12, 2013