


ORIGINAL INVESTIGATION

Percutaneous tracheostomy in COVID-19 patients: a new apneic approach



Elena Moizo ^{a,*}, Alberto Zangrillo^{a,b}, Sergio Colombo^a, Carlo Leggieri^a, Milena Mucci^a, Paolo Beccaria^a, Nicola Pasculli^a, Giovanni Borghi^a, Valentina Paola Plumari^a, Alessia La Bruna^a, Roberto Dossi^a, Martina Baiardo Redaelli^a, Anna Tornaghi^a, Gaetano Lombardi^a, Giovanni Landoni^{a,b}, Antonio Dell'Acqua^a, Francesca Guzzo^a, Giacomo Monti^a

^a IRCCS San Raffaele Scientific Institute, Department of Anesthesia and Intensive Care, Milan, Italy

^b Vita-Salute San Raffaele University, School of Medicine, Milan, Italy

Received 24 September 2020; accepted 12 July 2021

Available online 27 July 2021

KEYWORDS

COVID-19;
Percutaneous dilation
tracheostomy;
Tracheotomy;
Apnea;
Intensive care;
Critical care

Abstract

Background: Percutaneous dilation tracheostomy is an aerosol-generating procedure carrying a documented infectious risk during respiratory virus pandemics. For this reason, during the COVID-19 outbreak, surgical tracheostomy was preferred to the percutaneous one, despite the technique related complications increased risk.

Methods: We describe a new sequence for percutaneous dilation tracheostomy procedure that could be considered safe both for patients and healthcare personnel. A fiberscope was connected to a video unit to allow bronchoscopy. Guidewire positioning was performed as usual. While the established standard procedure continues with the creation of the stoma without any change in mechanical ventilation, we retracted the bronchoscope until immediately after the access valve in the mount tube, allowing normal ventilation. After 3 minutes of ventilation with 100% oxygen, mechanical ventilation was stopped without disconnecting the circuit. During apnea, the stoma was created by dilating the trachea and the tracheostomy cannula was inserted. Ventilation was then resumed. We evaluated the safeness of the procedure by recording any severe desaturation and by performing serological tests to all personnel.

Results: Thirty-six patients (38%) of 96 underwent tracheostomy; 22 (23%) percutaneous dilation tracheostomies with the new approach were performed without any desaturation. All personnel (150 operators) were evaluated for serological testing: 9 (6%) had positive serology but none of them had participated in tracheostomy procedures.

* Corresponding author.

E-mail: moizo.elena@hsr.it (E. Moizo).

Conclusion: This newly described percutaneous dilation tracheostomy technique was not related to severe desaturation events and we did not observe any positive serological test in health workers who performed the tracheostomies.

© 2021 Sociedade Brasileira de Anestesiologia. Published by Elsevier Editora Ltda. This is an open access article under the CC BY-NC-ND license (<http://creativecommons.org/licenses/by-nc-nd/4.0/>).

Introduction

Acute respiratory distress syndrome (ARDS) is the most serious complication of the new coronavirus disease 2019 (COVID-19) which has led to a high and unexpected number of patients admitted to intensive care units (ICU) who required mechanical ventilation worldwide. Many COVID-19 patients require tracheostomy due to prolonged mechanical ventilation. Tracheostomy has the advantage to reduce the risk of laryngeal damage and the need for sedation, which facilitates the process of weaning from mechanical ventilation and the patient's discharge from the ICU.

The most widespread techniques of percutaneous dilation tracheostomy (PDT) in ICU patients are performed with a single dilatator (e.g., Ciaglia or Percutwist techniques) or with special curved forceps (Griggs technique). All PDT techniques appear to be equally feasible at bedside in ICU, although the Griggs technique is associated with a higher incidence of intraprocedural bleeding and technical difficulties to complete the procedure (i.e., difficult cannula insertion, difficult dilation, or failure) than the single dilatator technique.¹

PDT is an aerosol-generating procedure that carried a documented infectious risk during the last Severe Acute Respiratory Syndrome (SARS) pandemic.^{2,3} In most SARS-CoV-2 patients, low respiratory tract specimens could remain positive for longer periods than upper respiratory ones.⁴ Therefore, postponing tracheostomy as much as possible could reduce the infectious risk for healthcare professionals. Stoma dilation is probably the most hazardous phase because air leaks are common at this point of the maneuver.

In the hypothesis that the PDT, as an aerosol generating procedure, could be dangerous for healthcare personnel, in this study we described a new technique which possibly reduces viral spreading. Then we evaluated the SARS-CoV-2 serological status of healthcare personnel.

Methods

This study is part of the COVID-BioB study, an observational investigation performed at Istituto di Ricovero e Cura a Carattere Scientifico (IRCCS) San Raffaele Scientific Institute (NCT 04318366), and it received approval by the Ethical Committee. From February 25 to April 22, 2020 we admitted patients with ARDS requiring invasive mechanical ventilation in the seven COVID-19 ICUs activated in the hospital, which was re-shaped for the emergency.⁵

PDT (Ciaglia, Percutwist and Griggs technique) was performed in adult patients who had prolonged mechanical ventilation (> 8 days), favorable anatomy (i.e., BMI less than 35, absence of evident deformities, etc.) and no

severe hypercapnia (more than 60 mmHg). The specific technique was chosen according to operators' preference and availability of the devices (the pandemic rapidly depleted tracheostomy set stocks and we were not able to use the same technique on all patients).

Modified PDT technique

Five out of seven COVID-19 ICUs performed PDT with the new approach described in this manuscript. The team was composed of two intensivists (one acted as bronchoscopist and the other was the operator), and two nurses. All the operators involved in the procedure wore a single-use cap, water-repellent coat or overalls, N100/FFP3 mask, goggles, protective visor, and gloves before entering the patient room. Before the procedure, a second sterile gown and a second pair of gloves were worn.

Before fiberoptic insertion, the patient was deeply sedated with both propofol and remifentanyl. Rocuronium or cisatracurium were administered to prevent cough and to obtain deep neuromuscular blocking. The patient was ventilated with 100% oxygen through the orotracheal tube. A fiberoptic was connected to an external video unit so that the bronchoscopist could stay as far as possible from the patient's mouth. The fiberoptic was inserted in the tracheal tube through a catheter mount with a flip-top cap to guarantee the sealing of the circuit. The tracheal tube was then retracted until the first tracheal ring was visualized. This phase needed the cuff of the tracheal tube to be deflated; ventilation was temporarily suspended. A guidewire was inserted by puncturing between the second and the third tracheal ring as in the usual practice. While the established standard procedure continues with the creation of the stoma by dilation without any change in mechanical ventilation setting parameters, we retracted the bronchoscope until immediately after the flip top cap in the catheter mount, allowing normal ventilation because the internal caliber of the airway was not reduced by the fiberoptic (Fig. 1). After 3 minutes of ventilation with 100% oxygen, with the same positive end expiratory pressure by which the patient was ventilated, mechanical ventilation was stopped without disconnecting the circuit. During apnea, we performed the first dilation with 14Fr dilator then we created the stoma by dilating the trachea according to the chosen technique (Ciaglia, Griggs or Percutwist), and the tracheostomy cannula was placed. Correct positioning was confirmed by fiberoptic control. Ventilation was resumed immediately after confirmation of correct cannula positioning.

We collected data concerning the rate of severe hypoxic events during the PDT procedure (defined as any peripheral oxygen saturation (SpO₂) less than 90%⁶), timing of tracheostomy from tracheal intubation, length of ICU and

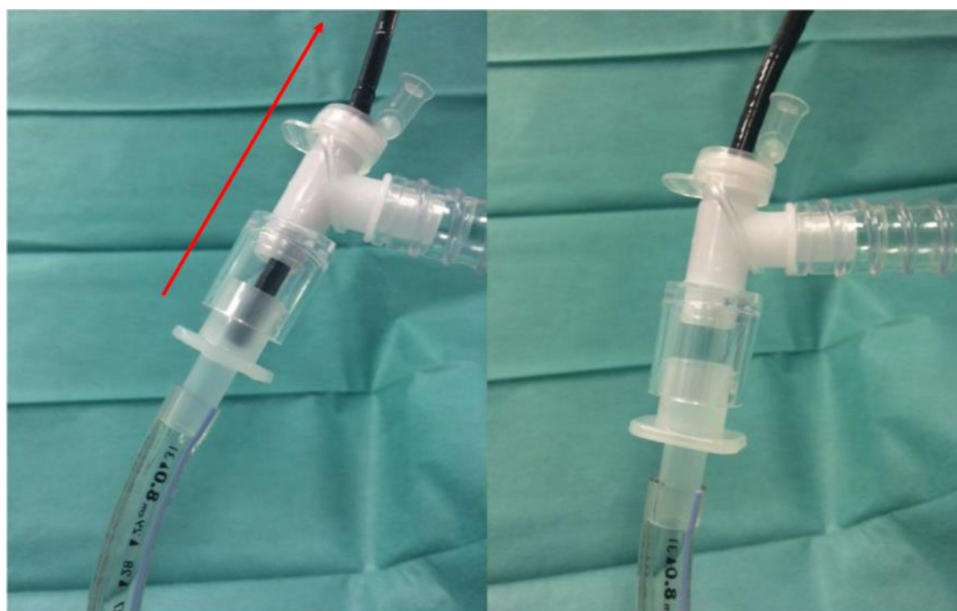


Figure 1 Position of fiberoptic (a) during modified percutaneous tracheostomy procedure, and (b) during ventilation before apneic stoma formation.

hospital stay, need for admission in rehab wards, and respective length of stay, deaths, and time to tracheostomy tube removal.

After the rapid reduction of COVID-19 ARDS prevalence in Italy⁷ and the closure of all our COVID-19 dedicated ICUs, all personnel was evaluated by serological testing (Immunoglobulin G for Sars-Cov 2, Liason XL instrument, DiaSorin, Varese, Italy). The number of positive serology-tests among healthcare providers was collected. Data were electronically collected and analyzed by Microsoft Excel[®]. Results are shown as n(%) for proportions, and median (interquartile) for continuous variable.

Results

We admitted 96 COVID-19 patients with ARDS requiring mechanical ventilation in the ICUs and 36/96 (37%) tracheostomies were performed (first tracheostomy on March 1st and the last one on May 4th, 2020). A surgical technique was used in 14/36 (39%) patients; the modified PDT technique first described in this manuscript was used in 22/36 (61%) patients, and these were included in the analysis. Most patients received the Ciaglia's PDT (15/22, 68%), while Griggs's PDT was used in 6/22 patients (27%) and Percutwist in 1 patient (5%).

Amongst PDT patients, mean age was 67 (59–71) and 17/22 (77%) patients were male. PDT was performed after a median (interquartile) of 14 (10–17) days from tracheal intubation (Table 1). No severe hypoxic events were observed.

Concerning the duration of acute hospital admission, the length of ICU stay was 26.5 (20–43) days; the length of hospital stay was 52 (35–73) days. Hospital mortality was 10/22 (46%). Nine patients died in ICU and one in the ward.

From the 12 survivors, tracheostomy tubes were removed 41 (27–46) days after PDT. One patient was directly discharged at home after the acute hospital stay. Eleven

Table 1 Demographics, complications, survival, and length of stay of 22 mechanically-ventilated patients for COVID-19 ARDS.

Parameter	Values
Age, years	67 (59–71)
Male sex	17 (77%)
Hospital mortality	10 (46%)
Days from tracheal intubation to PDT	14 (10–17)
Severe desaturation event	0 (0%)
LOS in ICU, days	27 (20–43)
LOS in hospital, days	52 (35–73)
LOS in rehabilitation, days	18 (11–30)
Tracheostomy tube removal time, days	41 (27–46)

ARDS, acute respiratory distress syndrome; PDT, Percutaneous dilation tracheostomy; LOS, Length of Stay; ICU, Intensive Care Unit.

patients were transferred to the rehabilitation ward and ten of them were discharged after 18 (11–30) days of rehabilitation. The flow chart with patients' flow and outcome is shown in Figure 2.

After the closure of all the COVID-19 intensive care units, 150 healthcare providers underwent serological testing and 9 (6%) were found positive. All the 23 resident doctors were negative, while 7/98 (7%) nurses and 2/29 (7%) physicians were positive. Thereafter, we retrospectively investigated if positive-tested healthcare providers had been involved in PDTs and found that no positive nurses or physicians had participated to PDT. Notably, one of the physicians had a positive swab in the early phase of epidemic, and the other one had the partner as a probable source of contagion. Among the nurses: one lived in the area of Bergamo (where an extremely high number of cases was registered), one had a relative as probable source of contagion, three had posi-

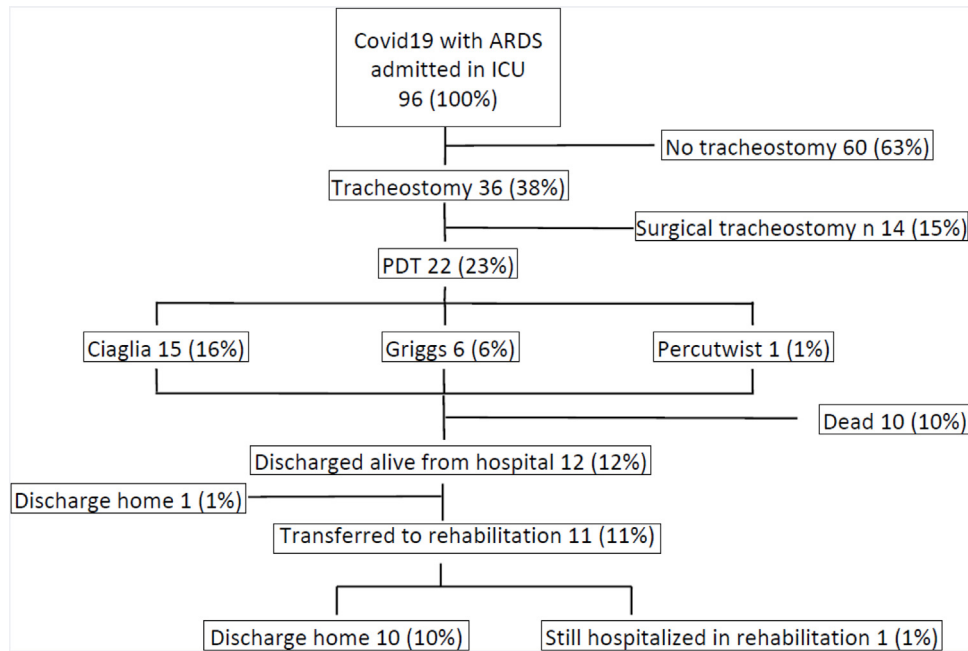


Figure 2 Flow chart and outcome of included patients. ARDS, acute respiratory distress syndrome; ICU, intensive care unit; PDT, percutaneous dilation tracheostomy. Sum of percentages may not be 100% because of rounding.

tive swabs several weeks before starting to work in the ICUs and two were fully asymptomatic.

Discussion

We described a modified technique for PDT which can be used in patients with Sars-Cov-2 or in other future respiratory pandemics. The technique was feasible, easy to perform, and we observed no severe hypoxia events among 22 consecutive patients. Briefly, after 3 minutes of pure oxygen ventilation and with the same positive end expiratory pressure already in use, stoma creation was performed during apnea, without disconnecting the patient from the ventilator. We also observed that none of the healthcare providers involved in the procedure developed a positive serology testing and we were able to identify a different and plausible chain of contagion in most of the positive healthcare providers working in the ICU during the pandemic event.

Despite the lack of data about superiority of surgical tracheotomies in terms of complications or safety for healthcare providers, this technique was generally favored over PDT during the SARS outbreaks,^{8–10} since PDT was considered at risk of aerosolization.

Recent guidelines for tracheostomy in COVID-19 pandemic refer mainly to surgical procedures^{11,12} and the Canadian society of otolaryngology, head & neck surgery even recommended to avoid tracheostomy in COVID-19 patient.¹²

Surgical tracheostomy is normally performed with initial advancement of the endotracheal tube, ensuring that the cuff is distal to the tracheostomy incision to prevent air flow through the stoma. Tracheal incision is performed, and ventilation is interrupted only before insertion of the tracheostomy tube. Early inflation of the cuff is advised to

ensure seal against the tracheal wall and, after confirmation of positioning, the orotracheal tube is removed. According to recommendations,^{11,12} this technique has the advantage of minimizing the possibility of air leak and therefore the risk of aerosolization. However, it also has disadvantages: first of all, it requires transporting the patient to the operating theatre; sometimes a larger stoma is created, with the risk of air leakage (if the cuff of the tracheostomy tube is not sealing) also after tracheostomy; and it has a higher incidence of bleeding and stoma infections when compared to the percutaneous technique.^{1,10}

Brendan et al., on the other hand, suggested a multidisciplinary approach in Sars-Cov-2-positive patients¹³ and the execution of the procedure where the team has more experience and confidence.

In addition, the optimal timing of tracheostomy is not well-defined yet.¹⁴ In Sars-Cov-2 positive patients, the same uncertainty exists, but an early tracheostomy could add an even higher infectious risk for healthcare providers. Considering the viral load, it seems that mouth and nose swabs become negative before the virus disappears in the lower respiratory secretions,¹⁵ putting the healthcare professionals at risk during tracheostomy procedures even if the swab is negative.

Moreover, the development of specific antibodies is usually detectable 12 days after symptoms onset.¹⁶ For this reason, tracheostomy should be performed ≥ 14 days after intubation according to Takhar et al.,¹² or ≥ 10 days following the suggestions of Brendan et al.¹³

The second issue against early tracheostomy is futility. The average time to death in ICU mechanically-ventilated COVID-19 patients was around 5 days in Wuhan,¹⁷ 7 days in Lombardy-Italy¹⁸ and 6 days in the UK.¹⁹ Therefore, performing tracheostomy too early could be a futile maneuver.

Our study has limitations and, as all observational studies, causality cannot be inferred. We evaluated the safety of the described sequence only in relation to severe desaturation, which is the most expected event associated with apnea, while we did not record mean arterial saturation during the procedure. We also did not collect other complications rate (i.e., infections, bleeding, and hypotension). We assessed the serology of healthcare professionals only after the ICUs closure. However, positive swab results can occur despite subsequently negative serology and therefore, we cannot exclude that asymptomatic healthcare professionals could have had a positive swab without developing antibodies.

We performed tracheostomy after 14 days of mechanical ventilation and did not control swab results in patients at the time of tracheostomy, so we cannot exclude that, at the moment of PDT, the patient was already negative. Moreover, operators of PDT adopted maximal barrier precautions, so we cannot evaluate if absence of transmission of COVID-19 is related to barrier precautions or to the described new sequence. We did not collect rate of infections in surgical tracheostomy operators, so we cannot compare result to percutaneous tracheostomy. Overall, the sample size is small, and our results come from a single center, thereafter generalizability is overall low.

Conclusions

We described a modified and safe sequence of percutaneous tracheostomy that, together with the correct use of PPEs, was associated with no virus transmission to any of the involved healthcare workers. Further studies are warranted, but we provide data that could be useful in current or future viral respiratory pandemics.

Conflict of interest

The authors declare no conflicts of interests.

Acknowledgements

We would like to thank all the medical staff, residents and nurses of San Raffaele Hospital, especially Martina Di Piazza, MD, Stefano Fresilli, MD, Davide Losi, MD, and Giacomo Senarighi, MD, for their precious work in revising this manuscript.

References

- Cabrini L, Landoni G, Greco M, et al. Single dilator vs. guide wire dilating forceps tracheostomy: a meta-analysis of randomised trials. *Acta Anaesth Scand*. 2013;58:135–42.
- Chen W-Q, Ling W-H, Lu C-Y, et al. Which preventive measures might protect health care workers from SARS? *BMC Public Health*. 2009;9:81.
- Tran K, Cimon K, Severn M, et al. Aerosol generating procedures and risk of transmission of acute respiratory infections to healthcare workers: a systematic review. *PLoS One*. 2012;7:e35797.
- Chen C, Gao G, Xu Y, et al. SARS-CoV-2-positive sputum and feces after conversion of pharyngeal samples in patients with COVID-19. *Ann Intern Med*. 2020;172:832–4.
- Zangrillo A, Beretta L, Silvani P, et al. Fast reshaping of intensive care unit facilities in a large metropolitan hospital in Milan, Italy: facing the COVID-19 pandemic emergency. *Crit Care Resusc*. 2020;22:91–4.
- Cabrini L, Monti G, Landoni G, et al. Percutaneous Tracheostomy, a systematic review. *Acta Anaesth Scand*. 2012;56:270–81.
- Ciceri F, Ruggeri A, Lembo R, et al. Decreased in-hospital mortality in patients with COVID-19 pneumonia. *Pathog Glob Health*. 2020;114:281–2.
- Tien HC, Chughtai T, Jokeklar A, et al. Elective and emergency surgery in patients with severe acute respiratory syndrome (SARS). *Can J Surg*. 2005;48:71–4.
- Chee VW, Khoo ML, Lee SF, et al. Infection control measures for operative procedures in severe acute respiratory syndrome-related patients. *Anesthesiology*. 2004;100:1394–8.
- Brass P, Hellmich M, Ladra A, et al. A. Percutaneous techniques versus surgical techniques for tracheostomy. *Cochrane Database Syst Rev*. 2016;7:CD008045.
- Canadian Society of Otolaryngology–Head and Neck Surgery. Recommendations from the CSO-HNS taskforce on performance of tracheotomy during the COVID-19 pandemic. *J Otolaryngol Head Neck Surg*. 2020;49:23.
- Takhar A, Walker A, Tricklebank S, et al. Recommendation of a practical guideline for safe tracheostomy during the COVID-19 pandemic. *Eur Arch Otorhinolaryngol*. 2020;277:2173–84.
- McGrath BA, Brenner MJ, Warrilow SJ, et al. Tracheostomy in the COVID-19 era: global and multidisciplinary guidance. *Lancet Respir*. 2020;8:717–25.
- Andriolo BNG, Andriolo RG, Saconato H, et al. Early versus late tracheostomy for critically ill patients. *Cochrane Database Syst Rev*. 2015;1:CD007271.
- Wang K, Zhang X, Sun J, et al. Differences of Severe Acute Respiratory Syndrome Coronavirus 2 Shedding Duration in Sputum and Nasopharyngeal Swab Specimens Among Adult Inpatients With Coronavirus Disease 2019. *Chest*. 2020;158(5):1876–84, <http://dx.doi.org/10.1016/j.chest.2020.06.015>.
- Zhao J, Yuan Q, Wang H, et al. Antibody responses to SARS-CoV-2 in patients of novel coronavirus disease 2019. *Clin Infect Dis*. 2020;71:2027–34.
- Leung C. Clinical features of deaths in the novel coronavirus epidemic in China. *Rev Med Virol*. 2020;30:e2103.
- Grasselli G, Zangrillo A, Zanella A, et al. Baseline characteristics and outcomes of 1591 patients infected with SARSCoV-2 admitted to ICUs of the Lombardy Region, Italy. *JAMA*. 2020;323:1574–81.
- Intensive Care National Audit and Research Centre, Accessed February 20, 2021 ICNARC report on COVID-19 in critical care; 2020.