

References

1. Edwards KM, Berbers GA. Immune responses to pertussis vaccines and disease. *J Infect Dis.* 2014;209 Suppl. 1:S10–5.
2. Mbayei SA, Faulkner A, Miner C, et al. Severe pertussis infections in the United States, 2011–015. *Clin Infect Dis.* 2019;69:218–26.
3. Nicolai A, Nenna R, Frassanito A, et al. Respiratory viruses and *Bordetella pertussis* co-infections: a frequent occurrence in children hospitalized with *Bordetella pertussis*. *Eur Respir J.* 2016;48:PA1275.
4. Zangrillo A, Beretta L, Scandroglio AM, et al. COVID-BioB Study Group. Characteristics, treatment, outcomes and cause of death of invasively ventilated patients with COVID-19 ARDS in Milan, Italy. *Crit Care Resus.* 2020 [in press].
5. van der Zee A, Schellekens JF, Mooi FR. Laboratory diagnosis of pertussis. *Clin Microbiol Rev.* 2015;28:1005–26.

Samuele Renzi^a, Massimo Clementi^{b,c}, Sara Racca^b, Milena Mucci^d, Paolo Beccaria^d, Giovanni Borghi^{d,*}, Giovanni Landoni^{c,d}, Alberto Zangrillo^{c,d}

^a The Hospital for Sick Children, Division of Haematology/Oncology, Toronto, Canada

^b IRCCS San Raffaele Scientific Institute, Laboratory of Microbiology and Virology, Milan, Italy

^c Vita-Salute San Raffaele University, Milan, Italy

^d IRCCS San Raffaele Scientific Institute, Anesthesia and Intensive Care Department, Milan, Italy

* Corresponding author.

E-mail: borghi.giovanni@hsr.it (G. Borghi).

Received 25 August 2020; accepted 26 September 2020

<https://doi.org/10.1016/j.bjane.2020.09.008>

0104-0014/ © 2020 Sociedade Brasileira de Anestesiologia.

Published by Elsevier Editora Ltda. This is an open access article under the CC BY-NC-ND license (<http://creativecommons.org/licenses/by-nc-nd/4.0/>).

Potentially disastrous reversal of neuromuscular block agents before removing Mayfield head holder



Dear Editor,

Precision in all surgical procedures is critical, and it is an undeniable factor. The millimetric accuracy, however, is essential in the majority of neurosurgical cases, especially in functional stereotactic and neuronavigation procedures, where long instruments are placed through the cerebral parenchyma aiming for deep specific encephalic points. Even with an exhaustive study of tractography, for instance, or any other imaging guidance software during surgery, the risk of damaging a “non-silent” central nervous system structure such as the internal capsule is always present and impersonates catastrophic consequences. For that reason, the complete immobilization of the head while performing these procedures is mandatory. One of the most employed devices to provide skull stability, allowing outstanding required precision, is the head holder. The pioneering work of Dr. James Gardner, in his brilliant article published in 1935,¹ displayed a head holder apparatus that became the prototype for the succeeding devices designed later. Currently, the Mayfield device is the most ordinarily employed worldwide. It is fashioned by a three-pin skull clamp (Fig. 1) that sustains the cranium in a motionless state. Several complications have been reported associated with the misuse of this equipment. The surgeon precipitates the preponderance of them, such as skull fractures and epidural hematomas.²

Nevertheless, the surgeon is not the sole blameworthy in this complicated multifactorial equation known as surgical-anesthetic procedure. The misapplication of basic concepts of pharmacology allied to the lack of understanding of the surgical timeline and sequential operational steps could imply harmful outcomes. One of the most common consequences of the sequential misconception above described is

the scalp laceration. It occurs while the patient superficializes and without following commands starts moving, usually as a response to the painful stimulus granted by the sharp pins attached to the skull. This uncoordinated movement can result in losing the pins from the skull and ultimately serving as a scalpel that could promote terrifying scalp lacerations. Furthermore, the temptation of early recovery from the deep neuromuscular block status necessary throughout surgery is often described, especially by inexperienced anesthesia providers.

Another significant point that should not be neglected is the unpleasant financial consequences that could accompany this fiasco. Even though patients undergo an awake craniotomy and regain consciousness with pins in place, they face a completely different situation. First of all, surgeons and anesthesiologists have previously scrutinized them who decide if the patient is emotionally able to tolerate this event. Additionally, the patient is informed about the situation, and the scalp block performed for these procedures plays a huge rule in offering more comfort and pain control.

For the reasons addressed before, we strongly suggest that the reversal of the neuromuscular block agent should be

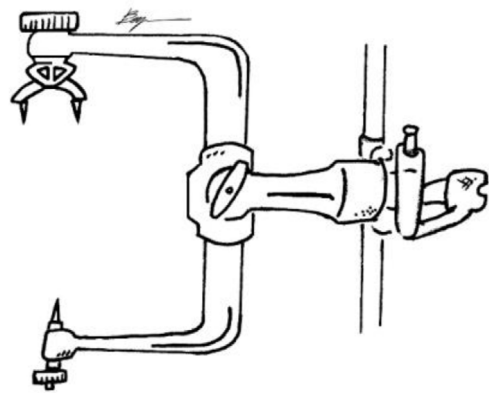


Figure 1 Three-pin skull holder (Mayfield) with sharp points.


done only after the removal of the headholder pins. Concurrently, the authors desire to emphasize that this unfortunate anesthetic complication is entirely preventable, and all efforts must be made to avert patient harm.

Conflicts of interest

The authors declare no conflicts of interest.

References

1. Gardner WJ. Intracranial Operations in the Sitting Position. *Ann Surg.* 1935;101:138–45.
2. Baerts WD, de Lange JJ, Booij LH, Broere G. Complications of the Mayfield skull clamp. *Anesthesiology.* 1984;61:460–1.

Christiano dos Santos e Santos  ^{a,*},
Caio Freire Benjamin Vianna ^b,
Ruy Castro Monteiro da Silva Filho ^c

^a University of Mississippi Medical Center, Department of Anesthesiology, Jackson, USA

^b Faculdade de Medicina de Campos, Campos dos Goytacazes, RJ, Brazil

^c Hospital Municipal Miguel Couto, Departamento de Neurocirurgia, Rio de Janeiro, RJ, Brazil

* Corresponding author.

E-mail: cesantos@umc.edu (C.S. Santos).

Received 7 August 2020; accepted 12 September 2020

<https://doi.org/10.1016/j.bjane.2020.09.012>
0104-0014/ © 2020 Published by Elsevier Editora Ltda. on behalf of Sociedade Brasileira de Anestesiologia. This is an open access article under the CC BY-NC-ND license (<http://creativecommons.org/licenses/by-nc-nd/4.0/>).

Subjective method for tracheal tube cuff inflation: time to bid adieu



Dear Editor,

We read with interest the study by Duarte et al., titled “Subjective method for tracheal tube cuff inflation: performance of anesthesiology residents and staff anesthesiologists. Prospective observational study”.¹ We laud the authors for choosing such a relevant and timeless topic. The dangers of over-inflating the endotracheal tube cuff are well known, including, but not limited to, sore throat, hoarseness, dysphagia, and under extreme circumstances, vascular occlusion and tracheal ischemia.^{1,2} The authors raise an extremely valid point, that when non-standardized methods, such as pilot balloon palpation are used, even the experienced anesthesiologists may not be able to guard the patients from the hazards of tracheal ischemia.

However, the study design documented by the authors requires some more elucidation. It would be desirable to know how anesthesia was maintained for the cases in question. Nitrous oxide is known to diffuse into the cuff and eventually increase cuff pressures and thus lead to increased morbidity due to increased cuff pressures. This diffusion occurs slowly over time, with Mogal et al., finding a significant increase in cuff pressures, in comparison to the previous readings, at both 30 and 60 minutes after intubation.³

This brings us to the next aspect of the study design that leaves room for improvement. When Mogal et al. compared cuff pressures with use of air and nitrous oxide, they found that while the increase in cuff pressures was significantly higher in the nitrous oxide group, the group with air also showed serial rise in pressures, albeit not as high.³ Duarte et al. have measured the cuff pressures only at one point in the surgery. However, the time-point is not specific. It is said

to have been “up to 60 minutes after tracheal intubation”.¹ This variability in the time of measurement could have led to readings that may not reflect the true pressures, just after cuff-inflation.

It might also be pertinent to know whether all the patients that participated in the study underwent the same type of surgery and if laparoscopic approaches were employed for any of them. In comparison to pressures seen in open surgical procedures, significantly higher cuff pressures have been found in patients undergoing laparoscopic procedures, and that too, as early as 5 minutes after institution of pneumoperitoneum.⁴

The authors work in government-aided teaching hospitals, that cater to the economically challenged patients, in a developing country. We understand not only the scarcity of cuff-pressure manometers, but also the difficulties maintaining such equipment in our set-up. However, we believe inexpensive alternatives to manometers do exist and recommend the use these alternatives to ensure appropriate cuff pressures.

The authors particularly endorse the use of Pressure Volume Loops (PVL), a real time graphic available on the anesthesia machines and ventilators, which is an easy, safe and effective method of ensuring appropriate cuff pressures after inflation. The method involves inflating the cuff in gradual increments of 0.5 mL, till a complete closure of the PVL can be seen, i.e., the expiratory limb reaches zero volume and meets the starting point of the inspiratory limb. Almarakbi et al. found that significantly lower volumes of air were required to achieve a seal and that recorded intra-cuff pressures were also well within normal limits.⁵

With the availability of newer tools to help achieve and maintain appropriate cuff pressures, which provide for enhanced safety for the patients, it only seems fair to bid adieu to the age-old technique of subjective method for tracheal tube cuff inflation by palpating the pilot balloon.