

## CASE REPORT

# Management of airway obstruction following lidocaine nebulization in a case of tracheal stenosis: case report

Kriti Chaudhary , Kamlesh Kumari \*, Swati Chhabra , Garima Choudhary 

All India Institute of Medical Sciences, Department of Anesthesiology and Critical Care, Jodhpur, India

Received 8 July 2020; accepted 18 September 2021

Available online 7 October 2021

### KEYWORDS

Airway obstruction;  
Lidocaine;  
Tracheal stenosis

**Abstract** Stenting for lower tracheal stenosis is a tricky situation and for the safe conduct of anesthesia, it is imperative to maintain spontaneous respiration. Airway topicalization is routinely recommended for anticipated difficult airway. We report a case of upper airway obstruction following lidocaine nebulization in a patient to be taken for tracheal stenting for lower tracheal stenosis. We would like to highlight that close monitoring of the patient is advisable during airway topicalization to detect any airway obstruction at the earliest and how fiberoptic intubation can play a pivotal role to secure the airway in an emergency scenario. © 2021 Sociedade Brasileira de Anestesiologia. Published by Elsevier Editora Ltda. This is an open access article under the CC BY-NC-ND license (<http://creativecommons.org/licenses/by-nc-nd/4.0/>).

## Introduction

Tracheal stenting for lower tracheal stenosis caused by anterior mediastinal mass poses a challenge to both anesthesiologists and surgeons. Depending upon the location, length, and severity of the stenotic segment, various anesthesia techniques for airway management may be chosen. To allow rigid bronchoscopy for tracheal stenting, spontaneous respiration is preferred to maintain airway patency by preserving transluminal pressure.<sup>1,2</sup> Nebulization with 4% lidocaine avoids cough reflex and aids in better patient cooperation. We hereby report a case of complete upper airway

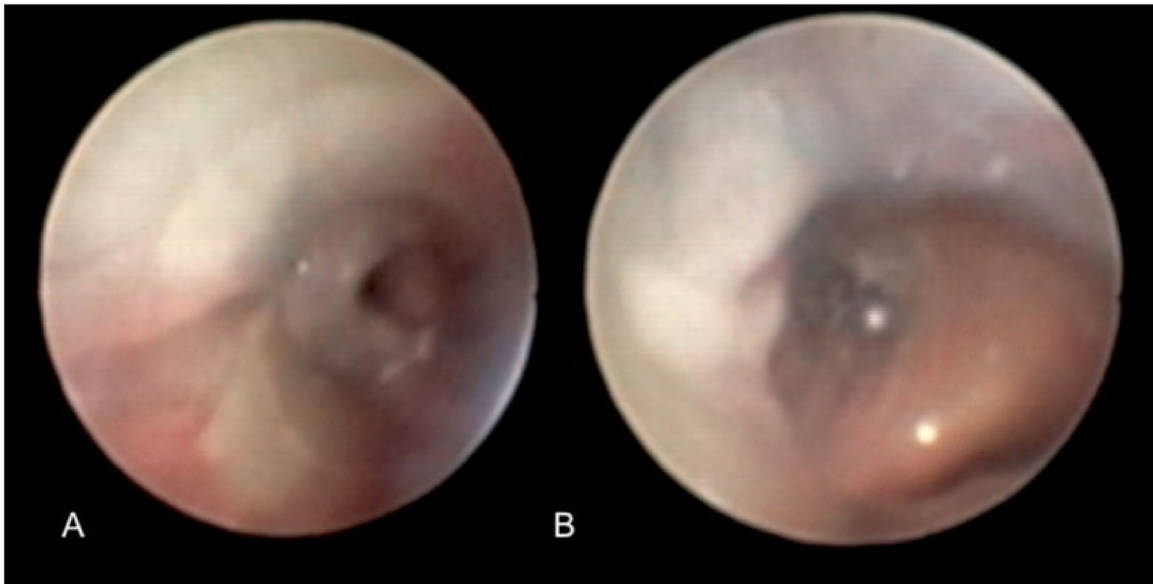
obstruction following nebulization with 4% lidocaine, while preparing the airway for tracheal stenting under sedation in a patient of lower tracheal stenosis, changing our primary plan, and turning a semi-emergent condition into an emergent one. Though fiberoptic intubation is not recommended as the first choice to manage the difficult airway in an emergency situation, it was lifesaving and probably the best choice available to secure the airway at the earliest in our case.

## Case report

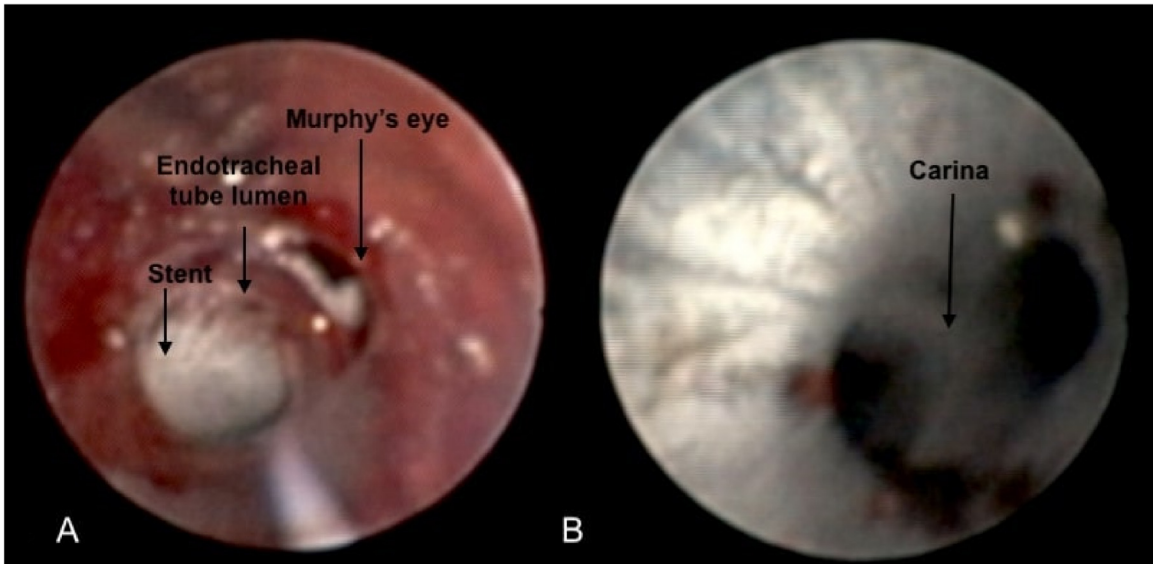
A 50-year-old female weighing 70 kg was scheduled to undergo tracheal stenting for severe lower tracheal stenosis caused by anterior mediastinal mass. On preanesthetic check-up, the patient was dyspneic in supine position,

\* Corresponding author.

E-mail: [kamlesh.gmch@gmail.com](mailto:kamlesh.gmch@gmail.com) (K. Kumari).



**Figure 1** Segment of tracheal stenosis as seen through endotracheal tube (ET) using flexible intubation video endoscope (FIVE).



**Figure 2** Post-procedure endoscopic views showing Y shaped tracheal stent (2A) just distal to the tip of ET and (2B) at the level of carina.

although comfortable and maintaining an oxygen saturation ( $SpO_2$ ) of 99% on room air in the sitting position. The patient had no comorbidities and her blood investigations were normal. Modified Mallampati score was 2 and spirometry revealed reduced forced expiratory volume in the first second ( $FEV_1$ –1.95L, 53% predicted), peak inspiratory, and peak expiratory flow rates ( $PEF$ –180L.min<sup>-1</sup>, 30% predicted). Arterial blood gas (ABG) analysis revealed mild impairment of oxygenation in the supine position with a pH of 7.457,  $PaO_2$  of 70.8mmHg, and  $PaCO_2$  of 34.6mmHg on room air. A thorax CT revealed an anterior mediastinal mass causing severe tracheal narrowing approximately 1.5 cm above the carina. Stenotic segment length was 1 cm with major and minor axis diameter of 4 mm

and 3 mm, respectively. A preliminary plan was decided after discussion with the multidisciplinary team. Rigid bronchoscopy (RB) was planned under intravenous (IV) propofol and dexmedetomidine sedation after anesthetizing the airway by 4% lidocaine nebulization. On the day of surgery, the patient was nebulized with 5 mL of 4% lidocaine via a nebulizer mask with an oxygen flow rate of 12 L.min<sup>-1</sup> in the preoperative area. After 5 minutes of lidocaine nebulization, the patient developed stridor and dyspnea in the sitting position as well. Soon the patient became restless and developed tachycardia (heart rate 135 beats/min) and tachypnea (respiratory rate 28 breaths/min), and her saturation dropped to 92%. She was transferred immediately to the operating room (OR) for emergency tracheal stent-

ing. The patient was agitated and unable to lie down, so the OR table was changed to 90° head-up position, and all routine monitors were attached while oxygenating with 100% oxygen via nasal prongs. She developed hypotension (blood pressure 80/40 mmHg) and SPO<sub>2</sub> dropped to 90%. Nasopharyngeal airway (NPA) size 7.0 mm was inserted and a breathing circuit was attached to it using a 15-mm connector of the endotracheal tube (ET) size 7.0 mm. Sevoflurane with 100% O<sub>2</sub> was administered via breathing circuit to allow for emergency nasal intubation using Karl Storz, flexible intubation video endoscope (FIVE) (Model 11301 BNXX) through the other nostril. End-tidal carbon dioxide (ETCO<sub>2</sub>) was noted to be as high as 90 mmHg. With the help of FIVE, the airway was secured with 6.5 mm ET and once the tube tip was placed just above the level of stenosis, the patient was hyperventilated to wash off retained CO<sub>2</sub>. After changing the patient's position to supine, an invasive arterial catheter was inserted, and IV noradrenaline was started at 0.05 µg.kg<sup>-1</sup>.min<sup>-1</sup> and titrated to maintain mean arterial pressure between 65–70 mmHg. Anesthesia was maintained with IV propofol infusion titrated to maintain a bispectral index of 40–60, fentanyl 2 µg.kg<sup>-1</sup> and atracurium 0.5 mg.kg<sup>-1</sup> loading dose followed by 0.1 mg.kg<sup>-1</sup> intermittent boluses. FIVE-guided examination of the stenosed area was done via ET (Fig. 1). The available deployer for tracheal stenting had an outer diameter of 11 mm which could not be passed through ET of any size, so under FIVE-guidance, ET was withdrawn till it was just beyond the glottis and tracheostomy stoma was made and deployer was inserted through it to place Y-shaped tracheal stent (Fig. 2A and B). Thereafter, the tube was inserted again to lie just above the stent margins and tracheostomy stoma was closed and the patient was electively ventilated to reach normocapnia and IV noradrenaline was gradually tapered off. The patient was extubated and shifted to the postoperative area for observation. Her postoperative vitals were stable, and she was later shifted to the ward.

## Discussion

Tracheal stenting for lower tracheal stenosis is a tricky procedure that involves maintaining airway patency while providing optimal time and conditions for the surgeon. Maintenance of spontaneous respiration is essential during the induction of anesthesia to avoid airway obstruction.<sup>1,2</sup> In our case, after lidocaine nebulization, the patient developed stridor due to upper airway collapse, as shown with FIVE.

Local anesthetic (LA) can depress laryngeal muscles or interfere with the receptor activity at the laryngeal level causing loss of upper airway muscle tone and precipitate airway collapse.<sup>3</sup> Similar scenario has been reported by Ho et al.<sup>4</sup> Airway obstruction by preexisting upper airway abnormalities can be anticipated by airway ultrasound, spirometry, CT, and MRI. But airway collapse by local anesthetic seems to be difficult to predict by such investigations, as it was not yet reported.

Fiberoptic intubation is not recommended as the first choice in severe acute airway obstruction.<sup>5</sup> However, in a sitting position, it was the most feasible option available to quickly secure an airway and with tracheal stenosis just 1.5 cm above carina, tracheostomy was unlikely to be helpful. NPA can prove to be a useful tool by relieving upper airway obstruction and improving oxygenation and ventilation by connecting it to a breathing circuit until a definitive airway can be secured. Inhalational agent can be administered through this set up to sedate the patient while avoiding loss of spontaneous respiration.

We would like to suggest that nebulization with LA should be dealt with caution and if feasible, should be done in a controlled OR environment and patients should be closely monitored for any signs of obstruction. Fiberoptic intubation by a competent and experienced anesthesiologist could be an important tool in securing emergent airways in such scenarios of acute airway obstruction with tracheal stenosis.

## Conflicts of interest

The authors declare no conflicts of interest.

## References

1. Erdös G, Tzanova I. Perioperative anaesthetic management of mediastinal mass in adults. *Eur J Anaesthesiol.* 2009;26:627–32.
2. Sibert KS, Biondi JW, Hirsch NP. Spontaneous respiration during thoracotomy in a patient with a mediastinal mass. *Anesth Analg.* 1987;66:904–7.
3. Dubey M, Pathak S, Ahmed F. Topicalisation of airway for awake fibre-optic intubation: Walking on thin ice. *Indian J Anaesth.* 2018;62:625–7.
4. Ho AM, Chung DC, To EW, et al. Total airway obstruction during local anesthesia in a non-sedated patient with a compromised airway. *Can J Anaesth.* 2004;51:838–41.
5. Wong P, Wong J, Mok MU. Anaesthetic management of acute airway obstruction. *Singapore Med J.* 2016;57:110–7.