

Conflicts of interest

The authors declare no conflicts of interest.

References

1. Carmona MJC, Quintão VC, Melo BF, André RG, Kayano RP, Malbouisson LMS, Auler-Júnior JOC. Transforming operating rooms into intensive care units and the versatility of the physician anesthesiologist during the COVID-19 crisis. *Clinics (Sao Paulo)*. 2020;75:e2023.
2. Torres MLA, Canhisares FAT, Quintão VC. Management of CO₂ absorbent while using the anesthesia machine as a mechanical ventilator on patients with COVID-19. *Rev Bras Anestesiologia*. 2020;70:184–5.
3. Mesnil M, Capdevila X, Bringuier S, Trine P-O, Falquet Y, Charbit J, et al. Long-term sedation in intensive care unit: a randomized comparison between inhaled sevoflurane and intravenous propofol or midazolam. *Intensive Care Med*. 2011;37:933–41.

4. Orser BA, Wang D-S, Lu W-Y. Sedating ventilated COVID-19 patients with inhalational anesthetic drugs. *EBioMedicine*. 2020;55.

Igor Pedrosa Saffier *, Rafael P. Kayano

Universidade de São Paulo (USP), Hospital das Clínicas, Faculdade de Medicina, São Paulo, SP, Brazil

* Corresponding author.

E-mail: igor.saffier@hc.fm.usp.br (I.P. Saffier).

Received 27 June 2020; accepted 9 September 2020

<https://doi.org/10.1016/j.bjane.2020.09.013>

0104-0014/ © 2020 Published by Elsevier Editora Ltda. on behalf of Sociedade Brasileira de Anestesiologia. This is an open access article under the CC BY-NC-ND license

(<http://creativecommons.org/licenses/by-nc-nd/4.0/>).

Is *Bordetella pertussis* co-infecting SARS-CoV-2 patients?

Bordetella pertussis está coinfecando pacientes com SARS-CoV-2?

Dear Editor,

Bordetella pertussis (*B. pertussis*) is a gram-negative respiratory coccobacillus that still represents a significant (yet largely preventable) cause of morbidity and mortality worldwide. It is well known that an infection with *B. pertussis* does not confer long-lasting protective immunity; this is also true in case of vaccination, as the antibody levels progressively wane.¹ While *B. pertussis* is generally considered a potentially life-threatening agent in children with less than 3 months of life, there has been increasing evidence that other categories of patients can also be severely affected by the disease, especially seniors.²

Table 1 Results of *Bordetella pertussis* testing in 10 COVID-19 patients admitted to the ICU.

Patient	DNA*	IgM	IgG	IgA
1	NEG	2.2	18.8	2.7
2	NEG	9.1	2.1	1.5
3	NEG	3.6	10.9	6.4
4	NEG	0.9	2.5	1.9
5	NEG	6	48.1	2.6
6	NEG	0.5	27.6	7.9
7	–	3.9	5.9	4.5
8	–	0.6	2.9	3.8
9	NEG	1	10.1	3.9
10	NEG	1.3	10	6.5

* PCR assays on nasopharyngeal swab.

§ Serological tests for *B. pertussis*.



As a result, some authors have recently hypothesized the possibility of overlooking a coinfection with *B. pertussis* in patients diagnosed with SARS-CoV-2 pneumonia. The clinical symptoms of these two diseases are in fact partially overlapping; moreover, *Bordetella pertussis* infections are frequently associated with respiratory viruses, including other types of human coronaviruses.³

Therefore, we aimed to screen for *B. pertussis* 10 adult patients admitted to the Intensive Care Unit (ICU) of our large tertiary university hospital⁴ for the management of severe SARS-CoV-2 pneumonia.

All patients underwent serologies for *B. pertussis*, while 8 were also screened through PCR assays on a nasopharyngeal swab, as molecular testing is the gold standard diagnostic for this disease.⁵ These patients were found to have negative PCR for *B. pertussis* DNA (Table 1). Furthermore, although the interpretation of *Bordetella pertussis*' serologies is challenging in the vaccine era, there was no serologic evidence of recent infection in our cohort.

Based on this limited, yet insightful experience, we believe that a coinfection with *B. pertussis* in patients affected by SARS-CoV-2 is rather unlikely. Consequently, we would not recommend for these patients an extensive screening for *B. pertussis*.

Funding

None.

Authors' contributions

All authors contributed equally to data collection and manuscript writing.

Conflicts of interest

The authors declare no conflicts of interest.

References

1. Edwards KM, Berbers GA. Immune responses to pertussis vaccines and disease. *J Infect Dis.* 2014;209 Suppl. 1:S10–5.
2. Mbayei SA, Faulkner A, Miner C, et al. Severe pertussis infections in the United States, 2011–015. *Clin Infect Dis.* 2019;69:218–26.
3. Nicolai A, Nenna R, Frassanito A, et al. Respiratory viruses and *Bordetella pertussis* co-infections: a frequent occurrence in children hospitalized with *Bordetella pertussis*. *Eur Respir J.* 2016;48:PA1275.
4. Zangrillo A, Beretta L, Scandroglio AM, et al. COVID-BioB Study Group. Characteristics, treatment, outcomes and cause of death of invasively ventilated patients with COVID-19 ARDS in Milan, Italy. *Crit Care Resus.* 2020 [in press].
5. van der Zee A, Schellekens JF, Mooi FR. Laboratory diagnosis of pertussis. *Clin Microbiol Rev.* 2015;28:1005–26.

Samuele Renzi^a, Massimo Clementi^{b,c}, Sara Racca^b, Milena Mucci^d, Paolo Beccaria^d, Giovanni Borghi^{d,*}, Giovanni Landoni^{c,d}, Alberto Zangrillo^{c,d}

^a The Hospital for Sick Children, Division of Haematology/Oncology, Toronto, Canada

^b IRCCS San Raffaele Scientific Institute, Laboratory of Microbiology and Virology, Milan, Italy

^c Vita-Salute San Raffaele University, Milan, Italy

^d IRCCS San Raffaele Scientific Institute, Anesthesia and Intensive Care Department, Milan, Italy

* Corresponding author.

E-mail: borghi.giovanni@hsr.it (G. Borghi).

Received 25 August 2020; accepted 26 September 2020

<https://doi.org/10.1016/j.bjane.2020.09.008>

0104-0014/ © 2020 Sociedade Brasileira de Anestesiologia.

Published by Elsevier Editora Ltda. This is an open access article under the CC BY-NC-ND license (<http://creativecommons.org/licenses/by-nc-nd/4.0/>).

Potentially disastrous reversal of neuromuscular block agents before removing Mayfield head holder



Dear Editor,

Precision in all surgical procedures is critical, and it is an undeniable factor. The millimetric accuracy, however, is essential in the majority of neurosurgical cases, especially in functional stereotactic and neuronavigation procedures, where long instruments are placed through the cerebral parenchyma aiming for deep specific encephalic points. Even with an exhaustive study of tractography, for instance, or any other imaging guidance software during surgery, the risk of damaging a “non-silent” central nervous system structure such as the internal capsule is always present and impersonates catastrophic consequences. For that reason, the complete immobilization of the head while performing these procedures is mandatory. One of the most employed devices to provide skull stability, allowing outstanding required precision, is the head holder. The pioneering work of Dr. James Gardner, in his brilliant article published in 1935,¹ displayed a head holder apparatus that became the prototype for the succeeding devices designed later. Currently, the Mayfield device is the most ordinarily employed worldwide. It is fashioned by a three-pin skull clamp (Fig. 1) that sustains the cranium in a motionless state. Several complications have been reported associated with the misuse of this equipment. The surgeon precipitates the preponderance of them, such as skull fractures and epidural hematomas.²

Nevertheless, the surgeon is not the sole blameworthy in this complicated multifactorial equation known as surgical-anesthetic procedure. The misapplication of basic concepts of pharmacology allied to the lack of understanding of the surgical timeline and sequential operational steps could imply harmful outcomes. One of the most common consequences of the sequential misconception above described is

the scalp laceration. It occurs while the patient superficializes and without following commands starts moving, usually as a response to the painful stimulus granted by the sharp pins attached to the skull. This uncoordinated movement can result in losing the pins from the skull and ultimately serving as a scalpel that could promote terrifying scalp lacerations. Furthermore, the temptation of early recovery from the deep neuromuscular block status necessary throughout surgery is often described, especially by inexperienced anesthesia providers.

Another significant point that should not be neglected is the unpleasant financial consequences that could accompany this fiasco. Even though patients undergo an awake craniotomy and regain consciousness with pins in place, they face a completely different situation. First of all, surgeons and anesthesiologists have previously scrutinized them who decide if the patient is emotionally able to tolerate this event. Additionally, the patient is informed about the situation, and the scalp block performed for these procedures plays a huge rule in offering more comfort and pain control.

For the reasons addressed before, we strongly suggest that the reversal of the neuromuscular block agent should be

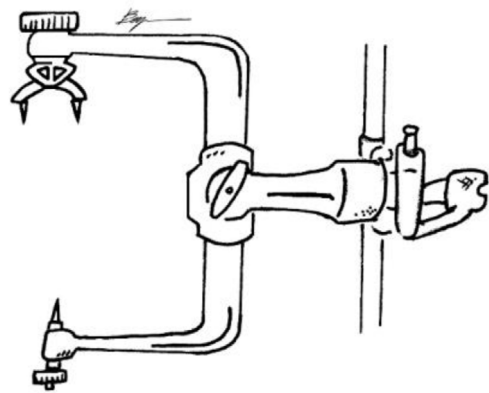


Figure 1 Three-pin skull holder (Mayfield) with sharp points.