

LETTERS TO THE EDITOR

Asynchronous differential lung ventilation in a patient with unilateral lung disease undergoing laparoscopic Heller myotomy



Dear Editor,

Differential lung ventilation has been used in unilateral lung disease cases; wherein protective ventilation strategies failed to maintain adequate oxygenation without damaging the lung parenchyma. It has also been used to manage bronchopleural fistula cases, caused or exacerbated by positive pressure ventilation.¹ Although this ventilatory strategy is useful for preventing mechanical ventilation damage in critically ill patients, there have only been a few reports of the application of differential lung ventilation in surgery.²⁻⁴ We report the perioperative management and outcome of a unilateral lung disease patient who underwent laparoscopic surgery with differential lung ventilation under general anesthesia. The patient in this report provided written informed consent for publication.

Case description

The patient was a 43-year-old man with no comorbidities. He had a weight of 56 kg, a height of 1.72 m, and an Ideal Body Weight (IBW) of 68 kg. He had a history of dysphagia, chest pain, persistent cough, sputum, and weight loss of 30 kg. He was hospitalized due to necrotizing pneumonia in the left upper lobe secondary to aspiration of gastric contents. He was diagnosed with achalasia type 2 and was recommended for laparoscopic Heller myotomy. After being evaluated by a multidisciplinary team (Anesthesia, Surgery, Bronchopulmonary, and Infectiology), the patient completed six weeks of antibiotic treatment and nutritional status optimization. The preoperative computed tomography scan revealed left upper lobe cavitation, connected to the segmental bronchus adjacent to the pleura (Fig. 1A).

Hence, differential lung ventilation was proposed as a safer strategy to avoid placing higher stress on the affected lung during surgery.

Preoperatively, the patients had a normal Spirometry and normal Oxygen Saturation (SpO₂) without supplemental oxygen therapy.

For differential lung ventilation with anesthetic delivery independent of pulmonary function, the bispectral index-guided Propofol-Remifentanyl target-controlled site effect infusion technique was performed. The patient received propofol (2.5 mcg.mL⁻¹) (Schnider model), remifentanyl (6 ng.mL⁻¹) (Minto model), rocuronium (50 mg), and lidocaine (60 mg). The anesthesia maintenance target was set to propofol (2.5 mcg.mL⁻¹), and remifentanyl was titrated according to surgical stimulation. The neuromuscular block was monitored using the Trend of Four (TOF)-Watch® in continuous mode. The dose of rocuronium was maintained at a target TOF of 0. The patient required a total of 30 mg of rocuronium. Manual bag ventilation was avoided since this can increase the pulmonary volume and pressure. After a preoxygenation period of five minutes, a left 42-Fr double-lumen tube was inserted and confirmed via fiberoptic bronchoscopy. Subsequently, two anesthesia machine stations, each connected to its respective tube lumen, were used to conduct asynchronous differential mechanical ventilation.

The mechanical ventilator settings were programmed in pressure-controlled ventilation mode to avoid overpressure-induced injury to the cavitated lung. The peak inspiratory pressure was set to 10 cmH₂O with a Positive End-Expiratory Pressure (PEEP) of 5 cmH₂O and a Respiratory Rate (RR) of 14 min. The non-injured lung (right) was programmed in volume-controlled ventilation mode, with a Tidal Volume (Vt) of 5 ccKg⁻¹ IBW, PEEP of 6 cmH₂O, and RR guided to CO₂ 35–45 mmHg. The patient was then positioned with an intraperitoneal inflation pressure of 15 mmHg, and the surgery was initiated. Intraoperatively, the Vt decreased from 150–175 mL to 100 mL. In the lung with limited pressure ventilation. The steady inspiratory pressure and PEEP pressure were 10 and 5 cmH₂O, respectively. The right lung maintained a Vt of 350 cc (5 cc.kg⁻¹ IBW). The peak, plateau, and driving pressure before the occurrence of pneumoperitoneum were 16, 14, and 8 cmH₂O, respectively. These pressures increased to 22, 20, and 16 cmH₂O, respectively, during the onset of pneumoperitoneum. The respiratory acidosis, following pneumoperitoneum, was corrected by increasing the alveolar ventilation of the healthy lung. Additionally, the RR was increased from 14 to 18 min, while the minute ventilation was increased from 5 to 6.3 L.min⁻¹. Adequate gas exchange was maintained throughout the procedure. The patient had a SpO₂ of 99–100% and PaO₂/FIO₂ > 400. He remained

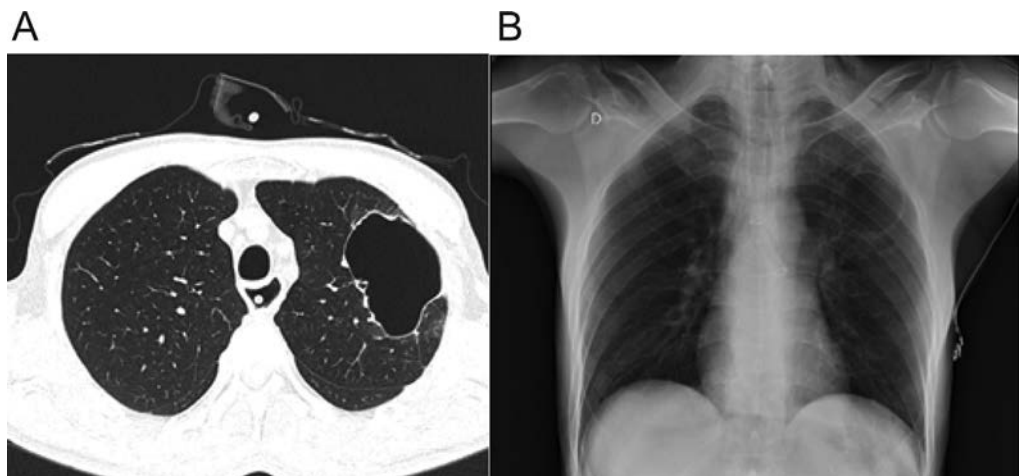


Figure 1 (A) Left-upper lobe cavitation. Non-contrasted computed tomography scans with extensive cavitation in the left upper lobe that contacts the pleural surface. (B) Postoperative image. Chest X-Ray confirms the absence of pneumothorax and other complications.

hemodynamically stable with a heart rate of 70–90 bpm and a mean arterial pressure of 70–85 mmHg.

After 2h30 min, the surgery was completed, and a chest radiograph showed the absence of pneumothorax (Fig. 1B). Sugammadex (200 mg) was administered to completely reverse the neuromuscular block with a 100% TOF index. The patient was extubated without complications. Postoperatively, the adequate respiratory mechanics were maintained without additional oxygen supplementation. No pulmonary complications were noted, and he was discharged on the third postoperative day.

Discussion

Maintaining adequate gas exchange and lung protection under general anesthesia is challenging in unilateral lung disease patients. In the present case, a laparoscopic Heller myotomy was successfully performed via differential lung ventilation in a patient with cavitation, communicating with a segmental bronchus. The major risk of surgery under general anesthesia and mechanical ventilation is the development of a bronchopleural fistula.

This case emphasized numerous learning points in the management of unilateral lung disease. First, patients with lung disease have decreased lung compliance. Thus, the conventional ventilation methods fail to determine the optimal ventilatory parameters to homogeneously distribute the ventilation. PEEP titration is challenging since high levels induce overdistension of normally ventilated areas. Secondly, in cases, involving communication between the airway and pleural space, positive pressure ventilation further exacerbates airway and lung injury in the diseased lung.⁵

In this case, differential lung ventilation utilized protective ventilatory parameters for both the healthy and diseased lungs. Most importantly, the airway pressure in the affected lung was limited using pressure-controlled ventilation. A driving pressure of 5 cmH₂O was employed throughout the surgery to prevent barotrauma in the affected lung.

Additionally, the application of PEEP in the affected lung maintained alveolar recruitment without increasing mean airway pressure, avoiding recruitment maneuvers. Although differential lung ventilation reduced the risk of airway injury, it was still possible since positive pressure ventilation was maintained in the affected lung.

Although there are case reports on differential lung ventilation in different settings, to the best of our knowledge, this is the first report describing the rare condition of differential lung ventilation and pneumoperitoneum.

Abbreviations

Ideal Body Weight (IBW); Positive end-Expiratory Pressure (PEEP).

Conflicts of interest

The authors declare no conflicts of interest.

Financing

This research did not receive any specific grant from funding agencies in the public, commercial, or not-for-profit sectors.

Supplementary materials

Supplementary material associated with this article can be found in the online version at [doi:10.1016/j.bjane.2022.02.003](https://doi.org/10.1016/j.bjane.2022.02.003).

References

1. Garlick J, Maxson T, Imamura M, Green J, Prodhon P. Differential lung ventilation and venovenous extracorporeal membrane oxygenation for traumatic bronchopleural fistula. *Ann Thorac Surg.* 2013;96:1859–60.
2. Shoman BM, Ragab HO, Mustafa A, et al. High frequency/small tidal volume differential lung ventilation: a technique of ventilating the nondependent lung of one lung ventilation for robotically assisted thoracic surgery. *Case Rep Anesthesiol.* 2015;2015:631450.
3. Kimura H, Hiraki T, Arata S, et al. Anesthetic management of pleurectomy/decortication under differential lung ventilation. *Kurume Med J.* 2018;65:23–5.
4. Kremer R, Aboud W, Haberfeld O, et al. Differential lung ventilation for increased oxygenation during one lung ventilation for video assisted lung surgery. *J Cardiothorac Surg.* 2019;14:89.
5. Thomas AR, Bryce TL. Ventilation in the patient with unilateral lung disease. *Crit Care Clin.* 1998;14:743–73.

Roberto González ^{a,*}, Karen Venegas^a, Felipe Maldonado^{a,c}, Rodrigo Cornejo^b

^a Hospital Clínico Universidad de Chile, Departamento de Anestesia y Medicina Perioperatoria, Facultad de Medicina, Santiago, Chile

^b Hospital Clínico Universidad de Chile, Departamento de Medicina, Unidad de Pacientes Críticos, Facultad de Medicina, Santiago, Chile

^c The Wound Repair, Treatment and Health (WoRTH) Initiative, Santiago, Chile

* Corresponding author.

E-mail: robgonzalez@uchile.cl (R. González).

Received 19 August 2021; accepted 8 February 2022

Available online 26 March 2022

<https://doi.org/10.1016/j.bjane.2022.02.003>

0104-0014/© 2022 Sociedade Brasileira de Anestesiologia. Published by Elsevier Editora Ltda. This is an open access article under the CC BY-NC-ND license (<http://creativecommons.org/licenses/by-nc-nd/4.0/>).

Perception of preceptors of medical residency in anesthesiology on their roles in educational activities: a watchful eye



Dear Editor,

Medical Residency (MR) is a lengthy medical training program that has been regulated in Brazil since 1977 and aims to prepare medical specialists for developing their professional activities with responsibility and quality.¹

In 2020, anesthesiology was the medical specialty with the fifth highest number of registered specialist titles (5.9%) in Brazil.² Medical Residency in Anesthesiology has direct access, lasts 3 years with a weekly workload of 60 hours, and must follow Brazilian Society of Anesthesiology (SBA) guidelines and structure.¹

The preceptor is essential for the improvement of MR. In addition to assisting in resident training, the preceptor coaches' residents to act competently during clinical practice. However, preceptors need professional experience and curricular knowledge.³ Training of preceptors and the role of preceptors in training specialists are relevant topics and therefore have been subject for debate.

A quantitative descriptive study was carried out at Universidade Estadual de Ciências da Saúde de Alagoas (UNCISAL) to determine the teaching profile of preceptors and examine their perceptions regarding MR. The study was approved by the UNCISAL Ethics Committee decision number 17781419.0.0000.5011.

The sample studied comprised 52 preceptors (80% of the total number of preceptors) from the three Anesthesiology Medical Residency Programs (MRPs) in the city of Maceió (AL).

Data was collected face-to-face between September 2019 and February 2020, and remotely from June to August 2020, using a tool for online questionnaires (Google Forms).

The preceptors answered both a sociodemographic questionnaire and another questionnaire developed and

validated by Giroto,⁴ comprising 35 statements on preceptorship, with Likert-type scale answers.

Positive Perception (PP) was attributed to respondents choosing the answers "Totally Agree" (TA) and "Partially Agree" (PA). On the other hand, the answers "Indifferent" (I), "Partially Disagree" (PD) and "Totally Disagree" (TD) were put together in another group, defined as negative perception (NP), presenting points to be improved.⁴ According to Giroto⁴ five domains are identified: 1. Educational competence; 2. Learning support and resources; 3. Planning of the Learning Program; 4. Integration between teaching and service; and 5. Presence of students in the practice field.

When examining overall data, we observed that the mean age was 42.69 ± 11.97 years, revealing a younger population compared to the overall mean age of anesthesiologists, which in 2020 was 49.1 ± 13.3 years.² Probably, this is due to the new anesthesiology MRPs recently accredited.²

When examining the experience of the preceptors regarding MR, the finding of 7.36 ± 8.14 years may suggest experienced preceptorship, which is beneficial regarding the teaching and training of residents. In addition, we observed that preceptors have a mean practice time as anesthesiologists of 12.74 ± 13.46 years, indicating they were also clinically experienced.

Regarding MSc and PhD degrees (*stricto sensu* postgraduate courses), none of the preceptors had a PhD degree, with the majority (88.45%) being specialists (RM), and only 3.85% had a MSc degree. As preceptors are required to hold a MR specialty certificate or certificate of specialization,¹ this criterion can generate less interest of preceptors in pursuing MSc/PhD degrees.

In regard to the Giroto⁴ questionnaire (Table 1), in Domain 1 (Educational Competence) a predominance of Positive Perception was recorded, showing an awareness of preceptors regarding the importance of using their competences in MR. This may also reflect confidence in their clinical skills, revealing competence in assisting residents' learning process.

Regarding Domain 2 (Learning Support and Resources), from the point of view of the preceptors, RM programs offer