



CLINICAL RESEARCH

The place of ultrasonography in confirming the position of the laryngeal mask airway in pediatric patients: an observational study

Sule Arican ^{a,*}, Sevgi Pekcan ^b, Gulcin Hacibeyoglu ^a, Merve Yusifov ^a, Sait Yuce ^a, Sema Tuncer Uzun ^a

^a University of Necmettin Erbakan, Medical Faculty, Department of Anaesthesiology, Konya, Turkey

^b University of Necmettin Erbakan, Medical Faculty, Department of Pediatric Chest Diseases, Konya, Turkey

Received 20 February 2020; accepted 24 December 2020

Available online 3 February 2021

KEYWORDS

Anesthesia;
Child;
Laryngeal mask
airway;
Ultrasonography

Abstract

Background and objectives: Laryngeal mask airways are increasingly used as supraglottic devices during general anesthesia. Ultrasonography can provide a dynamic image simultaneous to placing the supraglottic airway device. In the current study, the incidence of suboptimal laryngeal mask airway position and replacement in children was evaluated using simultaneous ultrasonographic imaging.

Methods: A prospective observational study was conducted on 82 patients aged 3–15 years with American Society of Anesthesiologists (ASA) physical status I or II. Patients under general anesthesia and with airway provided by a laryngeal mask airway were included. The position of the laryngeal mask airway was evaluated by ultrasonography on two planes. According to our scoring system, Grade I and Grade II were determined to indicate acceptable placement, while Grade III was determined to indicate unacceptable placement. Suboptimal laryngeal mask airway placement rates and the requirement of replacement were determined. Laryngeal mask airway placement optimized by ultrasonography was evaluated with both leak tests and a fiberoptic laryngoscope.

Results: The average age of the patients was 6.27 ± 4.66 years. After evaluation with ultrasonography, 65 (79.3%) of the laryngeal mask airways were found to be optimally positioned, while the position of 13 (15.9%) had to be corrected, and 4 (4.9%) had to be replaced. There was a moderate positive correlation between the ultrasonographic evaluation and leak test evaluation ($p < 0.001$; $r = 0.628$). Relocation of the laryngeal mask airway was determined to be an independent risk factor affecting the development of complications (OR = 2.961; $p = 0.046$; 95% CI 2.850–30.745).

* Corresponding author.

E-mail: drsulearican@hotmail.com (S. Arican).

Conclusion: The use of ultrasonography to verify and relocate laryngeal mask airway placement is noninvasive and effective.

© 2021 Sociedade Brasileira de Anestesiologia. Published by Elsevier Editora Ltda. This is an open access article under the CC BY-NC-ND license (<http://creativecommons.org/licenses/by-nc-nd/4.0/>).

Introduction

A Laryngeal Mask Airway (LMA) is a safe and effective supraglottic device used in children to provide lung ventilation under general anesthesia in surgery or diagnostic procedures, including fiberoptic bronchoscopy.

The large internal diameter of LMAs compared with tracheal tubes allows the use of a relatively large fiberoptic bronchoscope without a significant increase in airway resistance. Thus, pediatric diagnosis and interventional bronchoscopy can be performed under optimal conditions.¹ At the same time, LMAs are considered an alternative to endotracheal tubes in positive pressure ventilation due to the low complication rates and ease of placement.^{2,3} Although an LMA is easier to place than an endotracheal tube, it is also more likely to be misplaced. Inadequate ventilation, the requirement of relocation, and hypoxemia may develop as a result of improper LMA placement. If the reason for insufficient ventilation is not misplacement, replacing the LMA with an unnecessary intervention may further exacerbate existing hypoxemia by interrupting ventilation.³

A number of clinical tests have been used to evaluate the placement of LMAs, but none of these methods are visualizable. Thus, they cannot be used to determine whether the LMA is acceptably positioned.⁴

LMA placement needs to be validated to ensure adequate lung ventilation and maximize potential benefits.⁵⁻⁹ For this purpose, a Fiberoptic Examination (FOE) can be used, though this is an invasive method that requires the cessation of ventilation and can cause the airway to become contaminated with secretions. With ultrasonography (US), the assessment of LMA position and rate of detection of suboptimal LMA placement is high.⁷ No study has yet evaluated LMA placement using simultaneous US imaging and optimal image obtaining rates under US guidance in pediatric patients.

The current study aimed to determine the incidence of suboptimal LMA placement and replacement in children using simultaneous US imaging.

Material and methods

This study was performed at our hospital after the approval of the university ethics committee. The prospective observational study was conducted in 82 patients aged 3–15 years with American Society of Anesthesiologists (ASA) physical status I or II. Written informed consent was obtained from the parents of all children included in the study. Patients who underwent diagnostic and therapeutic bronchoscopy under general anesthesia and with airway provided by LMA were included. Patients with a difficult airway (according to thyromental height and the Mallampati test), a history of neck

surgery, airway malformation, upper respiratory tract infection, congenital heart disease, risk of aspiration, or who refused to participate or did not meet inclusion criteria were excluded from the study.

We calculated that the total of 82 patients would require an F-test with 85% power, 5% type-I error levels, and 25% effect size. The necessary sample size was estimated based on a pilot test. All patients were premedicated with oral midazolam (0.4–0.5 mg.kg⁻¹). Children transferred to the operation room were placed in supine position. The neck was supported using a rounded surgical cotton pad. Standard monitoring was performed with noninvasive arterial blood pressure tests, pulse oximetry, capnography, and continuous electrocardiography. Anesthesia depth was tracked using bispectral index monitoring. Anesthesia induction was continued with propofol (2–3 mg.kg⁻¹) and remifentanyl (0.5–1 µg.kg⁻¹.min⁻¹) and then maintained with sevoflurane. Neuromuscular medication was not given.

When a sufficient anesthesia depth was reached (40 < bispectral index < 60), an Ambu Aura Once (Ambu AO) LMA (Ambu A/S, Copenhagen, Denmark) was placed simultaneously by the same anesthesiologist (> 600 successful placements) accompanied by US. The LMA size was chosen based on the patient's weight as recommended by the producer. The LMA was held like a pen and inserted using the index finger, with pressure placed against the palate and posterior pharyngeal wall, and advanced until the mask tip reached the oropharynx. All LMAs were evaluated by the same anesthesiologist experienced in airway management with US.

LMA placement was imaged with US, and the cuff was inflated with air to 60 mmHg using a cuff inflation pressure manometer. LMA's ease of placement was evaluated and recorded using a Numerical Rating Scale (NRS) from 0 to 10 (It was considered that 0 was inserted without any sense of resistance in a continuous motion, and 10 was not possible to insert).

The LMA placement was imaged with a LA523 linear transducer (4–10 MHz) and a MyLab70 X vision ultrasound scanner (Esaote, Genova, Italy). Two standard image planes were obtained.³ The first of these was transverse between the hyoid and thyroid bones, with the typical image obtained being the shadow of the cuff sitting symmetrically on both sides of the midline with its smooth and plump cuff edge (Fig. 1a). The second image was taken on the parasagittal plane of the pharynx and larynx. The typical image in this plane included a sharp and clear view of the edge of the cuff, with the cuff and esophagus being shown on the same sagittal plane (Fig. 1b). Anatomical points were determined on the US images including the thyroid and epiglottis.

The transverse-plane image was evaluated as having 0 point if the tip of the cuff was smooth and full and the shadow of the cuff was symmetric. If the tip of the cuff

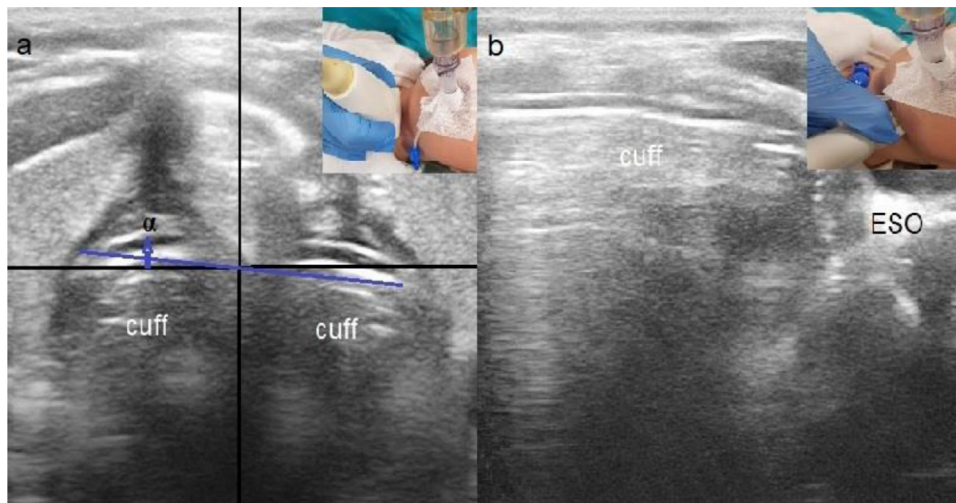


Figure 1 Acceptable placement images with US. (a) Transverse plane. Cuff tip is smooth and plump, and the shadow of cuff is symmetrical; α , The malrotation degree of the LMA (angulation < 10 degrees); (b) Parasagittal plane. Cuff tip is clearly seen, and the cuff and esophagus are on the same plane; ESO, Esophagus.

Table 1 US examination presentation points, gas leaks, and fiberoptic laryngoscope evaluation.

US evaluation	Gas leak evaluation	Fiberoptic laryngoscope evaluation
Transverse plane 0: The edge of the cuff is smooth and plump, and the shadow of the cuff is symmetrical. 1: The edge of the cuff is not smooth and plump, and the shadow of the cuff is not symmetrical.	Grade I (perfect): No audible leak Grade II (good): There is an audible leak with sufficient ventilation ($\text{paCO}_2 < 40$ mmHg) Grade III (unacceptable): Clinically significant air loss and insufficient ventilation requiring replacement of the device	A: While epiglottis is not determined, glottis can be seen completely B: 1-25% of glottic opening is covered by epiglottis C: 26-50% of glottic opening is covered by epiglottis D: 51-75% of glottic opening is covered by epiglottis
Parasagittal plan 0: The edge of the cuff is clearly visible, and the cuff and esophagus are in the same sagittal plane. 1: The cuff tip cannot be seen, and the cuff and esophagus are not in the same sagittal plane.	*Air entry into the stomach and abnormal airway sounds over the larynx were recorded Bilateral symmetrical chest movements and Grade I and Grade II: Acceptable placement (C-A) Grade III: Unacceptable placement (C-U)	E: 76%-100% of glottic opening is covered by epiglottis A and B: Acceptable placement (FOL-A) C-E: Unacceptable placement (FOL-U)
Grade I = 0, Grade II = 1, Grade III = 2 Grade I and Grade II: Acceptable placement (US-A) Grade III: Unacceptable placement (US-U)		

was not smooth and plump and the shadow of the cuff was not symmetrical, the image was evaluated as having 1 point. The parasagittal plane image was evaluated as having 0 point if the tip of the cuff was clearly visible and the cuff and esophagus were on the same plane. If it was impossible to see the cuff tip, and the esophagus and cuff were not on the same plane, the image was evaluated as having 1 point. Grading was performed according to the scores obtained as a result of these evaluations. If the total score obtained was 0, the patient was defined as Grade I. If the total score was 1 point, the patient was defined as Grade II. If the total score was 2 points, the patient was defined as Grade III. Grade I and Grade II were considered to indicate acceptable

placement (US-A), while Grade III was considered to indicate Unacceptable placement (US-U); (Table 1).³

In the transverse-plane image, if the position of the LMA between the hyoid and thyroid bones was not symmetrical (malrotation), the tilt was calculated. If there was rotation on the right side (> 10 degrees), the LMA was evacuated and pushed ventrally slightly to the left side. If there was rotation on the left side (> 10 degrees), the LMA was pushed ventrally slightly to the right side. The cuff was then inflated once again with air. Simultaneously, the LMA was continuously monitored with US, and the LMA tube was fixed by touching the chin when an optimal view was obtained. In cases where it was impossible to ventilate via the LMA, an additional placement attempt was allowed.

After placing the LMA, a 6–8 mL.kg⁻¹ tidal volume, 10–20 breath.min⁻¹ respiratory rate (end-tidal CO₂ = 35–40 mmHg), and volume-controlled ventilation with an inspiratory-expiratory ratio of 1:2 was initiated. Anesthesia was maintained using sevoflurane.

After evaluation of the LMA placement with US examination, the LMA placement was confirmed by clinical tests and Fiberoptic Laryngoscope (FOL) evaluation. A leak test was used as a clinical test to evaluate the airway, and the results were recorded.¹⁰ FOL evaluations were made 1 cm proximal to the tube by passing the FOL through the LMA tube. The airway view was evaluated using a built-in system (Table 1).¹¹

Possible complications (hypoxia, desaturation, laryngospasm, cough, etc.) were evaluated and recorded during both awake time and recovery time.

Several secondary goals in the current study were planned as follows: (i) Determine the rate of optimization for suboptimal LMA placements detected by US; (ii) Compare the incidence of LMA malposition among US, clinical evaluation, and FOL; and (iii) Determine the rate of postoperative complications and risk factors.

Statistical analysis

Data were analyzed using the SPSS 18.0 software (Statistical Package for the Social Sciences Inc., Chicago, IL). Continuous variables were expressed as a mean (\pm Standard Deviation [SD]), and categorical variables as a frequency (n) and percentage (%). Data were tested for normal distribution using the Kolmogorov-Smirnov test, a histogram, and \pm SD. Cut-off values were calculated using a Receiver Operating Characteristic (ROC) curve. When a significant cut-off value was observed, sensitivity and specificity were calculated. The relationship between US grade and leak test was investigated by Spearman's rank correlation coefficient (r). A logistic regression analysis including age, gender, ASA score, and relocation or correction after US was performed to determine independent risk factors affecting the development of complications. A value of $p < 0.05$ was considered to indicate statistical significance.

Results

The average age of the patients included in the study was 6.27 ± 4.66 years (min = 3, max = 15). The demographic data and clinical features of the patients are shown in Table 2.

Based on US, 27 of the LMA placements were assessed as Grade I (32.9%), 38 as Grade II (46.3%), and 17 as Grade III (20.8%). Thus, 65 (79.3%) of the LMAs were found to have acceptable placement overall. At the same time, the position of 13 (15.9%) Grade III LMAs had to be corrected, and 4 (4.9%) LMAs had to be relocated.

According to the leak tests, 69 of the LMA placements were evaluated as acceptable (84.1%; C–A), and 13 were evaluated as unacceptable (15.9%; C–U). After correction and relocation of the LMA position (n = 17), the US grades were evaluated again. According to the evaluation, 6 were assessed as Grade I (7.3%), 10 as Grade II (12.2%), and 1 as Grade III (1.2%).

Table 2 Demographics and clinical characteristics of the patients.

n = 82	
Age (years/mean \pm SD / min–max)	6.34 \pm 3.55 (3–15)
ASA, n (%)	
I	26 (31.7%)
II	56 (68.3%)
LMA size, n (%)	
no = 2	24 (29.3%)
no = 2.5	30 (36.6%)
no = 3	28 (34.1%)
Placement of LMAs, n (%)	
NRS = 0	40 (48.8%)
NRS = 1	7 (8.5%)
NRS = 2	10 (12.2%)
NRS = 3	10 (12.2%)
NRS = 4	7 (8.5%)
NRS = 5	4 (4.9%)
NRS = 7	2 (2.4%)
NRS = 8	2 (2.4%)
Propofol (mg)	80.49 \pm 56.78
Remifentanyl (μ g)	51.80 \pm 29.42

ASA, American Society of Anesthesiologists physical status; LMA, Laryngeal Mask Airway; NRS, Numeric Rating Scale.

Table 3 Distribution of LMA position according to ultrasonography and leak test.

n (%) / (n = 82)	
US	
US–A	65 / 79.3
US–U	17 / 20.8
Leak test	
C–A	69 / 84.1
C–U	13 / 15.9
US grades after correction/replacement	
US–A	16 / 19.6
US–U	1 / 1.2
Leak grades after correction/replacement	
C–A	17 / 20.8
C–U	0 / 0

US–A, Acceptable Placement; US–U, Unacceptable Placement; C–A, Acceptable Placement; C–U, Unacceptable Placement.

According to the leak test, 7 of the placements were evaluated as Grade I (8.5%) and 10 as Grade II (12.2%) after correction and relocation of the LMA position (Table 3). When the positions of the LMAs placed with US were evaluated using FOL, all LMA placements were observed as acceptable, receiving a characterization of either A (n = 52; 63.4%) or B (n = 30; 36.6%).

Regarding complications during awake time, hypoxia developed in 4 (4.8%) patients, desaturation in 4 (4.8%), retching in 2 (2.4%), laryngospasm in 6 (7.3%), and cough in 11 (13.4%). During recovery time, cough was observed in 15 (18.2%) patients, sore throat in 7 (8.5%), and hoarseness in 5 (6.1%).

According to the Spearman's correlation analysis, there was a moderate correlation between the US grade and the

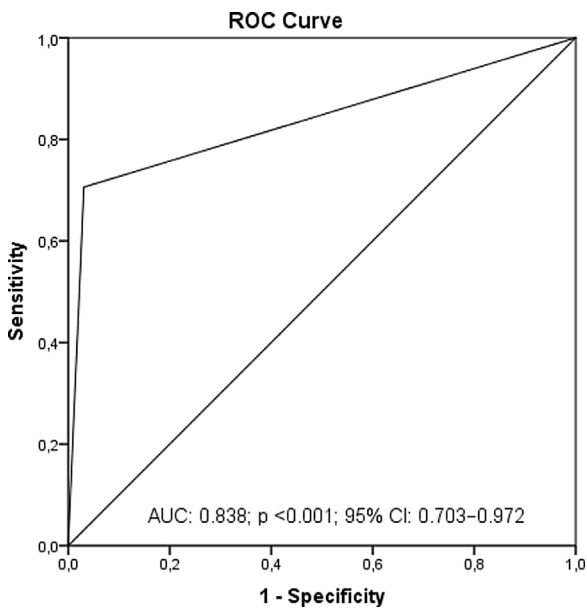


Figure 2 ROC analysis.

leak grade ($p < 0.001$; $r = 0.628$). According to the ROC analysis, the sensitivity of the leak test (AUC = 0.838; $p < 0.001$; 95%CI: 0.703–0.972) was found to be 96.9% and 70.6% when the LMA was in acceptable position according to the US (Fig. 2). A logistic regression analysis including age, gender, ASA score, and relocation or correction after US was performed to determine independent risk factors affecting the development of complications. Relocation of the LMA (OR=2.961; $p = 0.046$; 95% CI: 2.850–30.745) was determined to be an independent risk factor affecting the development of complications.

Discussion

In this study, which included children undergoing diagnostic and therapeutic fiberoptic bronchoscopy under general anesthesia, airway management provided with LMA was evaluated using US. Using this technique, suboptimal LMA placement was detected at a rate of 20.8%. While nearly a third of these suboptimal placements required optimization by US guidance, only 4.9% of them made relocation necessary. Optimal LMA positions were confirmed by FOL evaluations, and the results indicate that US is an effective and reliable method for confirming the position of LMAs.

Successful LMA placement is usually evaluated clinically based on a capnogram, appropriate excursion, and the absence of an audible leak at a peak respiratory pressure of 20 cm H₂O.

However, although all these clinical signs can be reassuring, they do not ensure that correct positioning has been obtained. FOL studies have shown that even when ventilation is sufficient, suboptimal anatomic positioning is still frequently found due to small pediatric LMAs partially or completely impeding the view of the glottic patency.⁹ It is important to place an appropriately sized LMA in the optimal position to provide adequate ventilation and prevent complications, such as mucosal injury, glossoptosis and aspiration potential, or gastric insufflation.^{9,12}

In adults, airway pressure (consisting of effective aeration and ventilation) has shown a high correlation with correct LMA positioning.¹³ Similarly, in adult patients LMA position grading according to US closely correlates with LMA position grading based on FOL.¹⁴

A suboptimally placed LMA can protect the airway to some extent. However, there is a high risk of displacement during operation. It is therefore important to ensure that LMAs placed in children are optimally positioned. Many studies on the evaluation of LMA position using FOL report that the majority of children (12.8–49%) need to have the LMA repositioned.^{9,15–17}

US can detect the rotation of the LMA even if it is positioned at the optimum depth. If the LMA deviates intra-operatively from the midline position, the US device may also assist in proper repositioning of the device. US thus helps achieve better interpretation of optimal LMA positioning in pediatric patients.⁷

In our study, LMA placement was found to be suboptimal in 20.8% (17) of patients after US evaluation. The position of 15.9% of the LMAs was corrected, while 4.9% were relocated to the optimal position. According to the leak test, the sub-optimal placement rate was 15.9%. A significant correlation was found between the US grade and leak test.

In cases in which the placement was confirmed to be optimal by FOL but ventilation was insufficient, the ventilation insufficiency may have occurred due to airway spasm caused by insufficient anesthesia depth.³

In our study, the anesthesia depth of the patients was monitored to prevent insufficient ventilation caused by airway spasm. The incidence of transient laryngospasm after placement of the LMA device was similar to that reported in other studies in which precautions were taken to ensure adequate depth of anesthesia prior to placement of the device.^{10,18,19} There has also been one study in which this rate was significantly higher.²⁰

There is great interest in the use of US in airway management. US examination is highly performance-dependent and subjective, not only in airway assessment but also in other areas. The peculiar nature of the US technique means that observer bias is sometimes inevitable. Detailed anatomy assessment is not required to confirm the position of the LMA. The only requirement is an image that can detect the end of the cuff and show the surrounding structure, as these can be used to confirm correct orientation and contact with the larynx.⁷

FOL studies have shown that although ventilation is adequate, small-sized pediatric LMAs are more frequently associated with suboptimal anatomical positioning, partially or completely obstructing glottic aperture vision.

LMAs in younger children are more frequently associated with partial obstruction of the glottis, insertion success, and quality of ventilation.^{8,9} In a previous study in which the airway management was performed by a single anesthetist, high rates of suboptimal LMA positioning were found using US.⁷

A standard concept has been designed to maintain homogeneity between different practitioners, and a score system similar to the clinical leak test has been defined to reduce observer bias.³

In this study, we designed two standard image planes to evaluate LMA positioning in pediatric patients, one on

the transverse and one on the sagittal plane. These were based on the spatial conformation of the pharynx and larynx, respectively. The strength of this study is that LMA placements were also evaluated with FOL in all patients. The position of 79.3% of the LMAs was considered acceptable by US assessment and this was confirmed by FOL. These results indicate that US is an effective imaging method for the evaluation of LMA position in pediatric patients.

Even a slight rotation of the LMA can be easily detected by the appearance of two asymmetric cuff shades on the transverse plane in the pharynx. A serious rotation of the LMA will cause one of the cuff shadows to be much smaller and deeper than the other and the edge of the cuff to be flat and stiff rather than full. However, rotation may not always impair ventilation.³

In this study, we did not interfere with rotations that were <10 degrees due to the fact that a slight rotational state caused the epiglottis to fold but did not completely block the airway, and a moderate leak in the leak test revealed acceptable ventilation.

There is a significant positive relationship between airway management and increased incidence of preoperative adverse events, such as cough, laryngospasm, bronchospasm, arterial oxygen desaturation, apnea or breath-holding, hospitalization, and even death.²¹⁻²³ Although LMA is not suitable for children who have undergone surgery in all cases, it has demonstrated clear benefits compared with endotracheal intubation in many children undergoing elective surgery. The frequency of preoperative adverse events in children using LMA in airway management is lower than when using other tools or endotracheal tubes.²⁴ Data have also shown that inappropriate LMA position is associated with airway complications.^{25,26}

In our study, LMA placement, correction, and relocation were performed using US for an optimal view. Since our patient group was composed of patients who underwent bronchoscopy for diagnostic and therapeutic purposes, adverse events were expected to be high. However, our results were observed to be compatible with the literature. Mild cough was associated with bronchoalveolar lavage accompanied by bronchoscopy and biopsy. Relocation of the LMA was identified as an independent risk factor for the development of adverse events. More care should be taken in patients with LMA relocation due to higher complication rates.

Our study has one main limitation. Namely, we used only Ambu AO LMAs, which are relatively easy to insert and have few manipulation requirements, perform well for all ages and weights and have been associated with only a few negative events. The leak pressure of these LMAs is approximately 22 cm H₂O.²⁷ For other LMA types, different leak pressures could lead to different results.

In our study, it was found that the optimization rate was high in the suboptimal LMA locations determined by US. Complication rate was low after LMA placement using US.

Conflicts of interest

The authors declare no conflicts of interest.

References

1. Jazbeck-Karam VG, Aouad MT, Baraka AS. Laryngeal mask airway for ventilation during diagnostic and interventional fiberoptic bronchoscopy in children. *Paediatr Anaesth.* 2003;13:691-4.
2. Yu SH, Beirne OR. Laryngeal mask airways have a lower risk of airway complications compared with endotracheal intubation: a systematic review. *J Oral Maxillofac Surg.* 2010;68:2359-76.
3. Song K, Yi J, Liu W, et al. Confirmation of laryngeal mask airway placement by ultrasound examination: a pilot study. *J Clin Anesth.* 2016;34:638-46.
4. Keller C, Brimacombe J, Keller K, et al. Comparison of four methods for assessing airway sealing pressure with the laryngeal mask airway in adult patients. *Br J Anaesth.* 1999;82:286-7.
5. Park JS, Kim KJ, Oh JT, et al. A randomized controlled trial comparing Laryngeal Mask Airway removal during adequate anesthesia and after awakening in children aged 2 to 6 years. *J Clin Anesth.* 2012;24:537-41.
6. Shimbori H, Ono K, Miwa T, et al. Comparison of the LMA-ProSeal and LMA-Classic in children. *Br J Anaesth.* 2004;93:528-31.
7. Kim J, Kim JY, Kim WO, et al. An ultrasound evaluation of laryngeal mask airway position in pediatric patients: an observational study. *Anesth Analg.* 2015;120:427-32.
8. Kaplan A, Crosby GJ, Bhattacharyya N. Airway protection and the laryngeal mask airway in sinus and nasal surgery. *Laryngoscope.* 2004;114:652-5.
9. Von Ungern-Sternberg BS, Wallace CJ, Sticks S, et al. Fiberoptic assessment of paediatric sized laryngeal mask airways. *Anaesth Intensive Care.* 2010;38:50-4.
10. Goldmann K, Jakob C. A randomized crossover comparison of the size 2 1/2 laryngeal mask airway ProSeal versus laryngeal mask airway-Classic in pediatric patients. *Anesth Analg.* 2005;100:1605-10.
11. Campbell RL, Biddle C, Assudmi N, et al. Fiberoptic assessment of laryngeal mask airway placement: blind insertion versus direct visual epiglottoscopy. *J Oral Maxillofac Surg.* 2004;62:1108-13.
12. Daya H, Fawcett WJ, Weir N. Vocal fold palsy after use of the laryngeal mask airway. *J Laryngol Otol.* 1996;110:383-4.
13. Joshi S, Sciacca RR, Solanki DR, et al. A prospective evaluation of clinical tests for placement of laryngeal mask airways. *Anesthesiology.* 1998;89:1141-6.
14. Gupta D, Srirajakalidindi A, Habli N, et al. Ultrasound confirmation of laryngeal mask airway placement correlates with fiberoptic laryngoscope findings. *Middle East J Anaesthesiol.* 2011;21:283-7.
15. Ghai B, Ram J, Makkar JK, et al. Fiber-optic assessment of LMA position in children: a randomized crossover comparison of two techniques. *Paediatr Anaesth.* 2011;21:1142-7.
16. Soh CR, Ng AS. Laryngeal mask airway insertion in paediatric anaesthesia: comparison between the reverse and standard techniques. *Anaesth Intensive Care.* 2001;29:515-9.
17. Tsujimura Y. Downfolding of the epiglottis induced by the laryngeal mask airway in children: a comparison between two insertion techniques. *Paediatr Anaesth.* 2001;11:651-5.
18. Goldmann K, Jakob C. Size 2 ProSeal laryngeal mask airway: a randomized, crossover investigation with the standard laryngeal mask airway in paediatric patients. *Br J Anaesth.* 2005;94:385-9.
19. Goldmann K, Roettger C, Wulf H. The size 1(1/2) ProSeal laryngeal mask airway in infants: a randomized, crossover investigation with the Classic laryngeal mask airway. *Anesth Analg.* 2006;102:405-10.
20. Karippacheril JG, Varghese E. Crossover comparison of airway sealing pressures of 1.5 and 2 size LMA-ProSeal™ and LMA-Classic™ in children, measured with the manometric stability test. *Paediatr Anaesth.* 2011;21:668-72.

21. Mir Ghassemi A, Neira V, Ufholz LA, et al. A systematic review and meta-analysis of acute severe complications of pediatric anesthesia. *Paediatr. Anaesth.* 2015;25:1093–102.
22. Von Ungern-Sternberg BS, Boda K, Chambers NA, et al. Risk assessment for respiratory complications in paediatric anaesthesia: a prospective cohort study. *Lancet.* 2010;376:773–83.
23. Rolf N, Cote CJ. Frequency and severity of desaturation events during general anesthesia in children with and without upper respiratory infections. *J. Clin. Anesth.* 1992;4:200–3.
24. Li L, Zhang Z, Yao Z, et al. The impact of laryngeal mask versus other airways on perioperative respiratory adverse events in children: A systematic review and meta-analysis of randomized controlled trials. *Int J Surg.* 2019;64:40–8.
25. Brimacombe J, Berry A. Insertion of the laryngeal mask airway – a prospective study of four techniques. *Anaesth Intensive Care.* 1993;21:89–92.
26. Cooke MS, Wei SH. A comparative study of southern Chinese and British Caucasian cephalometric standards. *Angle Orthod.* 1989;59:131–8.
27. Alzahem AM, Aqil M, Alzahrani TA, et al. Ambu AuraOnce versus i-gel laryngeal mask airway in infants and children undergoing surgical procedures. A randomized controlled trial. *Saudi Med J.* 2017;38:482–90.