

Tooth morphology, implantation and replacement system of *Hoplias malabaricus* (Teleostei, Characiformes, Erythrinidae)

Hassunuma, RM.^a, Stipp, ACM.^a, Heubel, MTCD.^b, Cestari, TM.^a, Ceolin, DS.^a, Nakamura, RSB.^a, Rosseti, PHO.^a and Assis, GF.^{a*}

^aDepartamento de Ciências Biológicas, Faculdade de Odontologia de Bauru - FOB, Universidade de São Paulo - USP, Bauru, SP, Brasil

^bDepartamento de Ciências Biológicas, Universidade do Sagrado Coração - USC, Bauru, SP, Brasil
*e-mail: gfassis@fob.usp.br

Received February 2, 2012 - Accepted October 3, 2012 - Distributed November 29, 2013
(With 2 figures)

Abstract

The oropharyngeal cavity of *Hoplias malabaricus*, an ichthyophagous freshwater fish, is anatomically adapted to predation. Macroscopic and microscopic analyses were conducted in order to study the morphology and system of implantation and replacement of teeth. The results showed that this teleost has conical and caniniform teeth, with an orthodontin crown covered by an enameloid cap and a vascularised orthodontin in the root. With regard to the implantation system, there is a junction between the tooth and the bone tissue, as a typical physiological dental ankylosis. The teeth are replaced by a resorption process of multinucleated giant cells that actively eliminate the dentin and bone tissue.

Keywords: tooth, Traíra, *Hoplias malabaricus*, *Erythrinidae*, morphology.

Morfologia, implantação e sistema de substituição dentária do *Hoplias malabaricus* (Teleostei, Characiformes, Erythrinidae)

Resumo

A cavidade orofaríngea do *Hoplias malabaricus*, um peixe de água doce ictiófago, é anatomicamente adaptado à predação. Análises macroscópica e microscópica foram realizadas com o objetivo de estudar a morfologia e o sistema de implantação e substituição dentária. Os resultados mostraram que este teleosteo apresenta dentes cônicos e caniniformes, com coroa de ortodentina coberta por capuz enamelóide e ortodentina vascularizada na raiz. Em relação ao Sistema de implantação, existe uma junção entre o dente e o tecido ósseo, semelhante a uma anquilose dentária fisiológica típica. Os dentes são substituídos por um processo de reabsorção por células gigantes multinucleadas que ativamente eliminam a dentina e o tecido ósseo.

Palavras-chave: dente, Traíra, *Hoplias malabaricus*, *Erythrinidae*, morfologia.

1. Introduction

The traíra (*Hoplias malabaricus*, *Erythrinidae*, *Cipriniformes*, *Pisces*) is a teleost fish of wide neotropical distribution in South America. This specimen is found from South Mexico to the central region of Argentina (Buckup, 1999; Carvalho et al., 2002; Mazzoni and Iglesias-Rios, 2002; Morais et al., 2012; Oyakawa, 1998), principally in lentic environments (Hauser and Benedito, 2012; Moraes and Barbola, 1995), and in shallow waters close to marginal or submersed vegetation (Bistoni et al., 1995; Resende et al., 1996; Sabino and Zuanon, 1998). This fish is relatively consumed by populations living on the margin of rivers where this specimen is found, demonstrating its economic importance (Godoy, 1975).

The dietary habits are typical of teleost fishes, consuming fruits, insects and smaller fishes. This specimen has typical predatory behaviour. The body surface is changed to mimic the environment and luminosity. The rows of sharp teeth are anatomically adapted to predation. Furthermore, this specimen has high organic resistance to environmental aggressions. However, because it is not a good hunter, *H. malabaricus* has nocturnal activity and prefer smaller, weaker or slower fishes. Consequently, this fish has considerable ecological importance. Pisciculturists use this specimen to eliminate the weaker specimens in artificial cultures (Santos, 1987).

The teeth of *H. malabaricus* are very important morphological components, since their presence during all life stages, from the larva to the adult, characterise the *Erythrinidae* family (Godoy, 1975). Studies on the di-

etary habits of *H. malabaricus* in the natural environment have been conducted by several authors (Almeida et al., 1997; Alvim and Peret, 2004; Bistoni et al., 1995; Caraschi, 1979; Catella, 1992; Loureiro and Hahn, 1996; MORAES And Barbola, 1995; Paiva, 1972, 1974; Peletti, 2006; Resende, 2000; RESENDE et al., 1996; Sabino and Zuanon, 1998; Soares, 1979; Uieda, 1983; Wine-miller, 1996), yet few articles in the literature describe the replacement of teeth in teleost fishes (Menin and Mimura, 1991; Torezan, 1978). Therefore, the current research aimed to study the dentition of *H. malabaricus*, especially considering the replacement of teeth.

2. Material and Methods

Fifteen specimens of several sizes and both sexes of *H. malabaricus* were collected in an experimental station of the University of Sagrado Coração (USC) on Vicinal road Córrego Campo Novo, s/n°, in the city of Agudos (SP). The fishes were transported to the Histology Laboratory of Bauru Dental School of the University of São Paulo. The animals were euthanized by brain concussion, using a straight and thin tip scissor. The oropharyngeal area of two animals was heated in a conventional oven and immersed in 2.5% sodium hypochlorite to remove the soft tissues for anatomical study of the skeleton and tooth structures. The remaining thirteen specimens were processed for light microscopy analysis. The specimens were immersed in 10% formalin solution for one week. After demineralization in 20% formic acid and sodium citrate (1:1), the material was processed and embedded in Paraplast resin. Longitudinal semi-serial 6- μ m thick sections were stained with Erlich's hematoxylin and Lison's eosin (H. E.).

3. Results

3.1. Results of Macroscopic Analysis

The *H. malabaricus* is an ichthyophagous species of fresh water. The wide oral opening, the elongated oral-aboral axis of the oral cavity and the reduced thickness of the pharyngeal masticatory apparatus favour the capture and swallowing of larger prey. Due to the type of oral and pharyngeal dentition, pre-digestive food preparation does not occur. The pointed and curved teeth, together with the tongue that is relatively mobile, do not allow the prey to escape from the oropharyngeal cavity. The passage of food is also enhanced by the disposition of oral and pharyngeal teeth.

The *H. malabaricus* has a homodont dentition, i.e. all teeth show the same morphology. Observation of the tooth *in situ* can show that they are covered by the soft tissue of the lips (Figure 1A). The teeth are conical or caniniform and can vary in number, size and spacing between them (Figure 1B). These teeth are implanted in the four maxillary bones (two pre-maxillas and two maxillas) and in the mandibles. The mandibles are constituted by two strong bones that articulate in the anterior region of the mouth. They are more anteriorly positioned in rela-

tion to the maxilla, characterising the *H. malabaricus* as a prognathic fish.

The dental crown has a pyramidal format and can be divided in incisal and basal portions (Figure 1C). The incisal region is very pointed and corresponds to the pyramid vertices. The basal region is wider and finishes in the cervical sulcus, which delimits the transition between dental crown and root. In the cervical region, a narrowing allows clear distinction between crown and root. The crown can be also divided in buccal and lingual aspects. The buccal aspect is concavo-convex in lateral view. The concavity is located in the incisal half and the convexity in the basal region. The buccal aspect has a triangular shape and is divided in mesial and distobuccal aspects that meet in the medial portions of the crown. The lingual aspect is plane-convex. The plane surface is located in the incisal portion and the convex surface in the basal region. Both lingual and buccal aspects have a triangular shape, as well as mesial and distolingual aspects that meet in medial portion, establishing a distinctly sharp edge.

The terminal portion of the root, different from that observed in humans, does not finish in an apex. Because of this, it is called basal region. The root has a cylindrical shape with a smaller circular region in the crown surface limit and a larger area in the basal portion.

Under the area of tooth implantation, wide circular orifices in each tooth are observed in the lingual or palatal aspect of the maxillary and mandibular bone. The orifices establish a communication between the pulp and the oral mucosa tissues. Smaller and numerous orifices are observed in the buccal aspect.

In addition to the teeth in the premaxillae, maxillae and mandibles, dentigerous areas are seen in the ectopterygoid and accessory ectopterygoid bones (Figure 1D and 1E) and in the pharynx (Figure 1F). The small teeth in these areas are oriented in a sequence reminiscent of a saw.

3.2. Results of Microscopic Analysis

3.2.1. Microscopic description of teeth

The *H. malabaricus* exhibits several dental groups that are constituted by a functional tooth and several buds in different developmental stages, located at the lingual or palatal aspect of the maxillary or mandibular bone. Many of them fuse with the bone tissue by physiological ankylosis (Figure 2A). Generally, the buds close to the functional tooth are in a more advanced stage of odontogenesis. These buds show similar morphology to mammals' teeth.

3.2.2. Description of dental lamina

Morphologically, the dental lamina exhibits cubic cells arranged in islands (Figure 2B). Frequently, the dental lamina leaves a connection between sequential buds, in a laminar shape, which can be considered potentially proliferative. The root formation is guided by

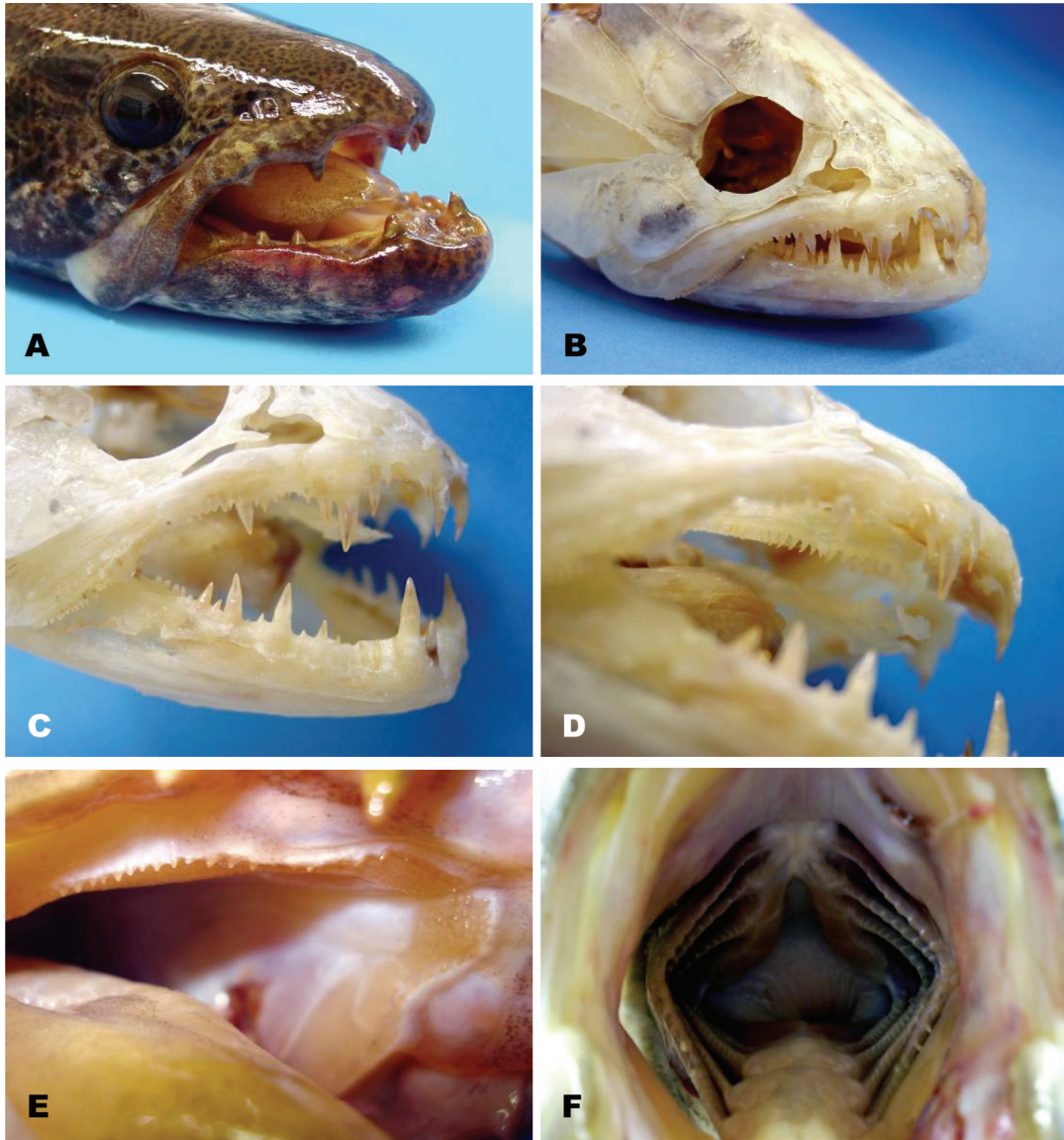


Figure 1A-F - Macroscopic photos of *Hoplias malabaricus* and its skeleton. Observe: A) Lateral view of the head; B) Lateral view of dissected cranium with closed mandible; C) Lateral view of dissected cranium with partially opened mandible; D) Dentigerous areas of ectopterygoid and accessory ectopterygoid bones inside the dissected oral cavity; E) Dentigerous areas of ectopterygoid and accessory ectopterygoid in the oral cavity; F) Dentigerous area in the pharynx.

Hertwig's epithelial sheath (Figure 2C), with similar morphological aspect as observed in mammal teeth.

3.2.3. Description of enamel

The enamel is produced by ameloblasts (Figure 2D) originated from the inner epithelium of the enamel organ, which is originated from the dental lamina. The ameloblasts are cubical in the basal region of the root. As they develop, the ameloblasts become more prismatic and elongated. Thus, the closer to the incisal region, the higher these cells will be. Their nuclei are arranged in palisade with basal polarity. Different than observed in mammals, the ameloblasts do not exhibit the Tomes' pro-

cess. Thus, although the enamel has a prismatic aspect, it is probably produced in a different manner than observed in humans.

The enamel shows a characteristic undulation in the region contacting the ameloblasts; the region contacting the dentin is irregular. As odontogenesis takes place, the ameloblasts lose the undulated contact with the enameloid matrix.

Sometimes, an intermediate layer of cells can be observed above the ameloblasts. The meeting of the inner and outer epithelia with the intermediate layer cells in the basal region of the tooth bud originates the Hertwig's epithelial sheath. Structures similar to mammals' stellate re-

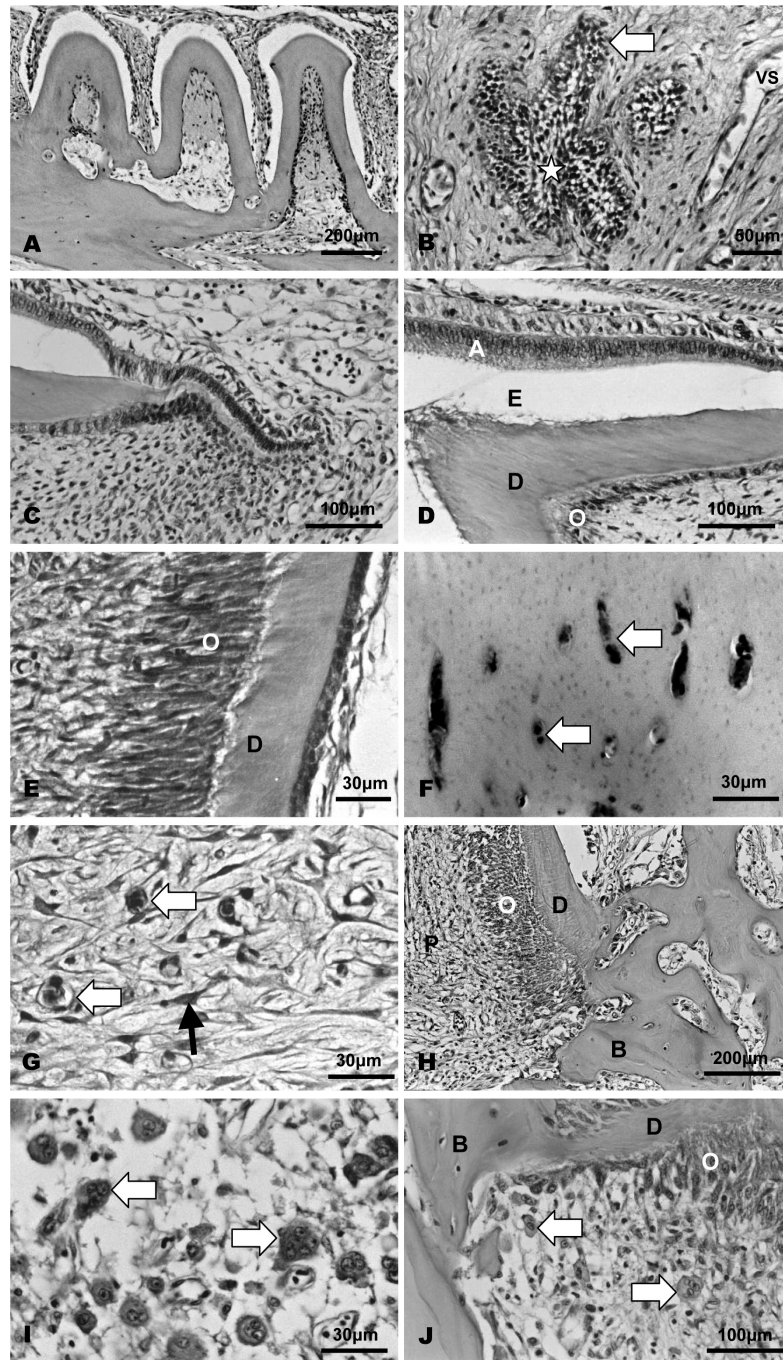


Figure 2A-J - Histological sections of maxillary and mandibular teeth of *H. malabaricus*. Observe: A) Several ankylosed mandibular teeth in the posterior mandibular region; B) Dental lamina in medial-third region of the mandible (arrow) with stellate reticulum in the central region (star) and blood vessels (VS); C) Hertwig's epithelial sheath in basal area of mandibular tooth from the anterior mandibular region; D) Ameloblasts (A), odontoblasts (O), dentin matrix (D) and the space filled by enameloid matrix removed by demineralization (E) of mandibular tooth from the anterior mandibular region; E) Odontoblasts and dentin matrix in from a maxillary tooth of the medial maxillary region; F) Vascular canals (arrow) in vascularized orthodontin of tooth from the anterior region of the premaxilla; G) Connective tissue rich in fibroblasts (narrow arrow) and blood vessels (large arrow) of pulp of mandibular tooth from the posterior mandibular region; H) Area of physiological ankylosis between dentin matrix (D) and bone tissue (B). Observe the odontoblasts (O) in the pulp (P) of a tooth from a posterior mandibular region; I) Odontoclasts (arrow) in the pulp of anterior mandibular tooth in physiological resorption; J) Odontoclasts (arrow) in the pulp near the area of physiological ankylosis of dentin matrix (D) and bone tissue (B) in tooth from the posterior mandibular region. Odontoblasts (O).

ticulum are not seen in any of the tooth buds. Therefore, the outer epithelium is juxtaposed to the inner epithelium.

3.2.4. Description of dentin-pulp complex

As observed in humans, the dentin is produced by odontoblasts (Figure 2E) and the thickness is enhanced at the incisal region. The cervical portion has more predentin than the incisal region. The population of odontoblasts is more abundant at the cervical third and less abundant toward the incisal region. The odontoblasts show a nucleus in the basal region and cytoplasmic projections that penetrate in the dentinal tubules.

The dentin in the crown has a conical shape in longitudinal view, and is grooved by dentinal tubules of straight trajectory that converge toward the tooth axis. The dentin in the root forms the major part of the tooth and is connected with the bone tissue in the basal portion. At this region, the dentin also presents dentinal tubules; however, twisted tubules can be seen close to twisted blood vessels, with blood cells. This characterises the vascularised orthodentin in some dental elements (Figure 2F).

The pulp is composed of soft connective tissue rich in blood vessels (Figure 2G), with odontoblasts near the dentin, collagen fibres and young fibroblasts. There is no transitional layer between the odontoblast layer and the pulp layer. Small vessels can be seen throughout the pulp.

3.2.5. Description of bone tissue, physiological ankylosis, physiological tooth resorption and dental replacement

In the basal region of the root, the bone matrix contacts the pulp and dentin (Figure 2H). Thus, there is no periodontal ligament between tooth and bone. The pulp fibre content is reduced by phagocytosis by giant multinucleated cells (Figure 2I). Some scattered fibrils and resistant fibroblasts remain near the dentin. The giant multinucleated cells are originated from the fusion of macrophages and are observed close to the dentin matrix and bone matrix (Figure 2J). Therefore, some osteoclasts and large Howship's lacunae are seen on the bone tissue surface. The lacunae are larger than observed in mammals.

Although the replacement resorption and osteodentin formation are considered pathologic in humans, in this specimen it is physiological and is associated with fast exfoliation and serial tooth irruption. Thus, the multinucleated cells are responsible for the resorption that precedes the exfoliation of teeth. Therefore, this exfoliation system is responsible for the serial eruption in this fish species.

4. Discussion

The *H. malabaricus* is considered a preferably piscivorous teleost (Almeida et al., 1997; Carvalho et al., 2002; loureiro and Hahn, 1996; Lowe-McConnell, 1987; RESENDE et al., 1996). The diet also includes shrimps

(Peletti, 2006; Resende et al., 1996), insects and other invertebrates (Moraes and Barbola, 1995; Peletti, 2006; Pompeu and Godinho, 2001), algae, organic debris and vegetables (Moraes and Barbola, 1995; Peletti, 2006). However, the presence of vegetable fragments and other components in the stomach can be considered accidental because of the voracious behaviour of this specimen, which ingests parts of the vegetation that is near the prey (Moraes and Barbola, 1995).

The characteristics of developed oral dentition, relatively mobile tongue, pharynx with denticles arranged in dentigerous areas are anatomical adaptations for feeding that are shared by other ichthyophagous *Characiformes* species such as *Hoplias lacerdae*, *Salminus brasiliensis*, *S. maxillosus*, *S. hilarii*, *Acestorhynchus lacustris* and *A. britskii* (Rodrigues and Menin, 2006).

Although many fishes, like the *Serrasalmus marginatus*, ingest dilacerated preys, the traíra uses the teeth for immobilization and ingestion (Godoy, 1975; Moraes and Barbola, 1995; Peletti, 2006). Thus, the teeth of *H. malabaricus* are not functional for prey grinding or dilaceration (Menin and Mimura, 1991), and the oral apparatus favor the ingestion of the whole preys, avoiding their escape (Moraes and Barbola, 1995). The tips of palatal teeth are posteriorly directed and arranged in a single row. This arrangement can avoid the prey escape in the orobranchial cavity and lacerate the prey skin, exposing the prey muscles for easier digestion (Jobling, 1995; Rodrigues and Menin, 2006). Another factor that contributes to avoid the prey escape in the digestive tract is the skeletal striated muscle in the initial portion of the stomach (Peletti, 2006). Besides, the traíra exhibits dentigerous plates in the tongue (Oyakawa, 1990) and dentigerous areas in the pharynx (Menin and Mimura, 1991) and in ectopterygoid and accessory ectopterygoid bones that favour the capture of live, agile and slippery organisms, the transit to the stomach, the ingest of whole preys and difficult regurgitation (Menin and Mimura, 1991, Pacheco, 2004).

The teeth of *H. malabaricus* do not have individual denomination as in mammals. Menin and Mimura (1991) detailed the anatomical distribution of traíra's teeth. In the premaxilla, there are teeth of different sizes: a canine is near the symphysis and another five or six conical teeth are laterally positioned in each hemimaxilla (the first and the last are the largest). Laterally to them, there are other canine and two small conical teeth. In the maxilla, there are three small conical teeth reminiscent of a saw. After this, there is other canine and a saw with 14 or 16 conical teeth until the end of the maxilla. These teeth are smaller than the others and are disposed in the ventral border of the maxilla. All these described teeth are disposed in a single row in the premaxilla and maxilla. In the mandible, two conical teeth in the medial region remain between the two maxillary canines when the animal closes its mouth. In each mandibular bone, there are many canines interposed between smaller teeth, and interposed between the premaxillary and maxillary teeth. A continuous saw of several conical teeth is observed in the mandible. Similar

to the maxilla and premaxilla, these teeth are disposed in a single row. In the palate, there are small conical teeth in the ectopterygoid and accessory ectopterygoid bones. They are disposed in two rows, in a V shape with the vertices in cranial direction.

The enamel has low organic content and high inorganic material, with hydroxyapatite crystals parallelly oriented in a plane tangent to the surface. This superficial layer can result from the mineralization of an organic matrix under the inner epithelium of the enamel organ. A similar matrix is observed in other teleosts and is considered a primitive form of enamel matrix (Torezan, 1978). The enameloid matrix seems to be produced by inner epithelium cells that contribute with high production of carbohydrates, resorption of organic matrix, deposition of inorganic matrix (Prostak and Skobe, 1986, 1988, 1993; SASAGAWA, 1997) and mineralization of enameloid matrix (Sasagawa, 1997). Probably, the odontoblasts are responsible for collagen synthesis in the enameloid matrix (Prostak and Skobe, 1986, 1988, 1993). However, more studies are necessary to characterize the enameloid matrix and the participation of inner epithelium cells, ameloblasts and odontoblasts in enameloid matrix production. Besides, there are no theoretical models that explain the secretion of enameloid matrix, since there is no Tomes' process in ameloblasts.

Under the enamel of some teeth, there is a vascularised orthodontin, also known as orthovasodontin. It contains vascular canals that seem to be unrelated with the nutrition of odontoblasts' process, only presenting a topographic relationship. The dentin matrix has high fibre content, especially collagen fibres that are deposited in a centripetal and incremental manner, originating the growth lines or bands.

The system of tooth implantation of *H. malabaricus* involves ankylosis, a type of dental support that is frequent in several inferior vertebrates. The ankylosis, as observed in others carnivorous fishes, is associated with the predatory habit of *H. malabaricus* and is also related with the absence of periodontal ligament. The degeneration signals observed in the pulp of functional teeth of adult animals can be related to the tooth resorption process, since they are not observed in young animals (Torezan, 1978).

References

- ALMEIDA, VLL., HAHN, NS. and VAZZOLER, AEAM., 1997. Feeding patterns in five predatory fishes of the high Paraná River floodplain (PR, Brazil). *Ecol. Freshw. Fis.*, vol. 6, p. 123-133.
- ALVIM, MCC. and PERET, AC., 2004. Food resources sustaining the fish fauna in a section of the upper São Francisco River in Três Marias, MG, Brazil. *Braz. J. Biol.*, vol. 64, p. 195-202.
- BISTONI, MA., HARO, JG. and GUTIÉRREZ, M., 1995. Feeding of *Hoplias malabaricus* in the wetlands of Dulce river (Córdoba, Argentina). *Hydrobiologia*, vol. 316, p. 103-7.
- BUCKUP, PA., 1999. Sistemática e biogeografia de peixes de riachos. In CARAMASCHI, EP., MAZZONI, R. and PERES-NETO, PR. (Eds.). *Ecologia de peixes de Riachos. Vol. VI*. Rio de Janeiro: PPGE-UFRJ. p. 91-138.
- CARAMASCHI, EMP., 1979. *Reprodução e alimentação de Hoplias malabaricus (Bloch, 1794) na Represa do rio Pardo (Botucatu, SP) (Osteichthyes, Cypriniformes, Erythrinidae)*. São Carlos: Universidade Federal de São Carlos. Dissertação de Mestrado em Ecologia e Recursos Naturais.
- CARVALHO, LN., FERNANDES, CHV. and MOREIRA, VSS., 2002. Alimentação de *Hoplias malabaricus* (Bloch, 1794) (*Osteichthyes, Erythrinidae*) no rio Vermelho, Pantanal Sul Mato-grossense. *Rev. Bras. Zootecias Juiz de Fora* vol. 4, p. 227-236.
- CATELLA, AC., 1992. *Estrutura da comunidade e alimentação de peixes da baía da Onça, uma lagoa do Pantanal do rio Aquidauana, MS*. Campinas: Universidade Estadual de Campinas. Dissertação de Mestrado.
- GODOY, MP., 1975. *Peixes do Brasil Sub-Ordem Characoidei – Bacia do Rio Mogi-Guaçu. Vol. 3*. Piracicaba: Editora Franciscana. p. 401-444.
- JOBLING, M., 1995. *Environmental Biology of Fishes*. Londres: Chapman & Hall.
- HAUSER, M. and BENEDITO, E., 2012. Species of the *Hoplias aff malabaricus* complex (*Characiformes: Erythrinidae*): An investigation of coexistence in a neotropical floodplain. *Zoologia (Curitiba)* vol. 9, p. 59-69.
- LOUREIRO, VE. and HAHN, NS., 1996. Dieta e atividade alimentar da traíra, *Hoplias malabaricus* (Bloch, 1794) (*Osteichthyes, Erythrinidae*), nos primeiros anos de formação do Reservatório de Segredo – PR. *Acta limnol. bras.*, vol. 8, p. 195-205.
- LOWE-McCONNELL, RH., 1987. *Ecological studies in tropical fish communities*. Cambridge: Cambridge University Press.
- MAZZONI, R. and IGLESIAS-RIOS, R., 2002. Distribution pattern of two fish species in a coastal stream in southeast Brazil. *Braz. J. Biol.*, vol. 62, p. 171-178.
- MENIN, E. and MIMURA, OM., 1991. Anatomia funcional da cavidade bucofaringeana de *Hoplias malabaricus* (Bloch, 1794) (*Characiformes, Erythrinidae*). *Revista Ceres*, vol. 38, p. 240-55.
- MORAES, MFPG. and BARBOLA, IF., 1995. Hábito alimentar e morfologia do tubo digestivo de *Hoplias malabaricus* (*Osteichthyes; Erythrinidae*) da Lagoa Dourada, Ponta Grossa, Paraná, Brasil. *Acta Biol. Par.*, vol.24, p. 1-23.
- MORAIS, ALS., PESSOA, EKR., CHELLAPPA, S. and CHELLAPPA, NT., 2012. Composição ictiofaunística da lagoa do Jiqui, Rio Grande do Norte, Brasil. *Biota Amazônica*, vol. 2, p. 51-58.
- OYAKAWA, TO., 1990. *Revisão sistemática das espécies do gênero Hoplias (grupo Lacerdae) da Amazônia brasileira e região leste do Brasil. (Teleostei, Erythrinidae)*. São Paulo: Universidade de São Paulo. Dissertação de Mestrado.
- OYAKAWA, TO., 1998. *Relações filogenéticas das famílias Pyrrhulinidae, Lebiasinidae e Erythrinidae (Osteichthyes: Characiformes)*. São Paulo: Universidade de São Paulo. Tese de Doutorado.
- PACHECO, MR., 2004. *Estudo morfológico de duas populações de Hoplias grupo malabaricus (Characiformes: Erythrinidae) procedentes da bacia do Rio Grande, Estado de São Paulo*. São Carlos: Universidade Federal de São Carlos. Dissertação de Mestrado.
- PAIVA, MP., 1972. *Fisioecologia da traíra, Hoplias malabaricus (Bloch), no nordeste brasileiro. Crescimento, resistência à salinidade, alimentação e reprodução*.

- São Paulo: Universidade de São Paulo. Tese de Doutorado.
- PAIVA, MP., 1974. *Crescimento, alimentação e reprodução da traíra, Hoplias malabaricus (Bloch) no nordeste brasileiro*. Fortaleza: Editora da Universidade Federal do Ceará.
- PELETTI, D., 2006. *Alimentação e análise morfológica de quatro espécies de peixes (Astyanax altiparanae, Parauchenipterus galeatus, Serrasalmus marginatus e Hoplias aff. Malabaricus) na planície de inundação do alto Rio Paraná, Brasil*. Maringá: Universidade Estadual de Maringá. Tese de Doutorado.
- POMPEU, PS. and GODINHO, AL., 2001. Mudança na dieta da traíra *Hoplias malabaricus* (Bloch) (Erythrinidae, Characiformes) em lagoas da bacia do rio Doce devido à introdução de peixes piscívoros. *Rev. Bras. Zool.*, vol. 18, p. 1219-1225.
- PROSTAK, KS. and SKOBE, Z., 1986. Ultrastructure of the dental epithelium and odontoblasts during enameloid matrix deposition in cichlid teeth. *J. Morphol.*, vol. 187, p. 159-172.
- PROSTAK, KS. and SKOBE, Z., 1988. Ultrastructure of odontogenic cells during enameloid matrix synthesis in tooth buds from an elasmobranch, *Raja erinacae*. *Am. J. Anat.*, vol. 182, p. 59-72.
- PROSTAK, KS. and SKOBE, Z., 1993. Enameloid formation in two tetraodontiform fish species with high and low fluoride contents in enameloid. *Arch. Oral Biol.*, vol. 38, p. 1031-1044.
- RESENDE, EK., 2000. Trophic structure of fish assemblages in the Lower Miranda River, Pantanal, Mato Grosso do Sul State, Brazil. *Rev. Brasil. Biol.*, vol. 60, p. 389-403.
- RESENDE, EK., PEREIRA, RAC., ALMEIDA, VLL. and SILVA, AG., 1996. *Alimentação de peixes carnívoros da planície inundável do rio Miranda, Pantanal, Mato Grosso do Sul, Brasil*. Boletim de Pesquisa. Corumbá: EMBRAPA-CPAP.
- RODRIGUES, SS. and MENIN, E., 2006. Anatomia da cavidade bucofaringeana de *Salminus brasiliensis* (Cuvier, 1817) (Pisces, Characidae, Salmininae). *Biotemas*, vol. 19, p. 41-50.
- SABINO, J. and ZUANON, J., 1998. A stream fish assemblage in central Amazônia: distribution, activity patterns and feeding behaviour. *Ichthyol. Explor. Freshwaters*, vol. 8, p. 201-210.
- SANTOS, E., 1987. *Peixes de água doce*. Belo Horizonte: Editora Itatiaia.
- SASAGAWA, I., 1997. Fine structure of the cap enameloid and of the dental epithelial cells during enameloid mineralization and early maturation stages in the tilapia, a teleost. *J. Anat.*, vol. 190, p. 589-600.
- SOARES, MGM., 1979. Aspectos ecológicos (alimentação e reprodução) dos peixes do Igarapé do Porto, Aripuanã, MT. *Acta Amazônica*, vol. 9, p. 325-352.
- TOREZAN, MA., 1978. *Estudo do mecanismo de substituição, da morfologia macro e microscópica do sistema de implantação e dos dentes funcionais da traíra (Hoplias malabaricus) (Bloch, 1794)*. (Pisces, Cypriniformes, Erythrinidae). Piracicaba: Universidade Estadual de Campinas. Dissertação de Mestrado.
- UIEDA, VS., 1983. *Regime alimentar, distribuição especial e temporal de peixes (Teleostei) em um riacho na região de Limeira, São Paulo*. Campinas: Universidade Estadual de Campinas. Dissertação de Mestrado.
- WINEMILLER, KO., 1996. Ontogenetic diet shifts and resource partitioning among piscivorous fishes in the Venezuelan llanos. *Environ. Biol. Fish*, vol. 26, p. 177-99.