



# The Brazilian Journal of INFECTIOUS DISEASES

[www.elsevier.com/locate/bjid](http://www.elsevier.com/locate/bjid)



## Clinical image

# Disseminated cutaneous leishmaniasis: ulcerovegetative and ulcero-crusted lesions

Isabela Martins Sgarbi<sup>a</sup>, Flávia da Silva Domingos Santos<sup>a</sup>, Veridiana Elisa Monteiro<sup>a</sup>,  
Silvia Nunes Szente Fonseca<sup>b</sup>, Fred Bernardes Filho<sup>a,\*</sup>

<sup>a</sup> Hospital São Francisco, Departamento de Medicina Interna, Ribeirão Preto, SP, Brazil

<sup>b</sup> Hospital São Francisco, Departamento de Doenças Infecciosas e de Controle de Infecções, Ribeirão Preto, SP, Brazil

## ARTICLE INFO

### Article history:

Received 7 October 2016

Accepted 26 October 2016

Available online 21 December 2016

A 69-year-old male patient, with history of multiple furuncles for two months, without improvement after the use of cephalexin and amoxicillin/clavulanate for 20 days, and daily fever for a week. On dermatological examination, multiple ulcerovegetative and ulcero-crusted cutaneous lesions on the face, ears, scalp, back, upper and lower limbs and genitalia were observed (Figs. 1 and 2). There was no lymphadenopathy. Based on the clinical picture the hypotheses of disseminated cutaneous leishmaniasis, paracoccidioidomycosis, and malignant syphilis were raised. Laboratory tests (blood count, renal function, hepatography, and coagulogram) were normal. Serology for hepatitis, syphilis, HIV, and *Leishmania donovani* were negative.

Swabs taken from open lesions for direct mycological examination and culture for fungi were negative. Histopathological of the edge of an ulcer on the dorsum demonstrated dense lymphohistiocytic inflammatory infiltrate with plasma and mast cells, in addition to neutrophils and granuloma formation; hyperplastic skin surrounded with

areas of pseudoepitheliomatous pattern. Giemsa and Ziehl-Neelsen staining were negative for fungi and acid-fast bacilli, respectively. Rounded and oval structures with kinetoplast, phagocytosed in macrophages were observed.

Based on clinical and histological picture of chronic ulcerated dermatitis associated with leishmaniasis, the diagnosis of disseminated cutaneous leishmaniasis was established, the treatment with meglumine antimoniate 20 mg/kg/day was started, and administered for 30 days. After 20 days of the end of treatment, there was healing of skin and mucosal lesions. He is in the ninth month of follow-up, with no appearance of new lesions and complications (Fig. 3).

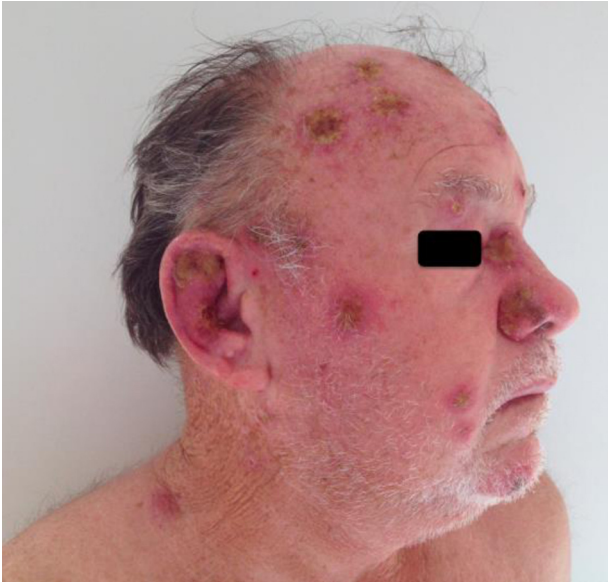
A negative serology for *L. donovani* came as no surprise, as this agent causes visceral leishmaniasis, with rare cases of skin lesions described in the literature.<sup>1,2</sup> Currently considered an emerging form of the disease,<sup>3</sup> disseminated leishmaniasis should be detected early, recognizing its clinical spectrum and disabling potential.

\* Corresponding author.

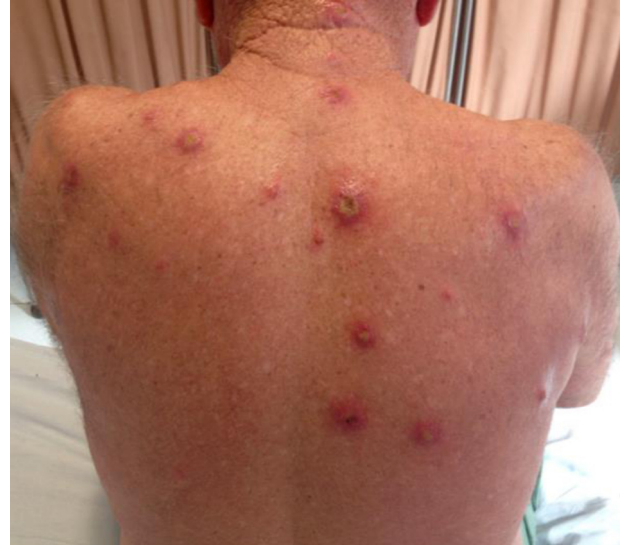E-mail address: [f9filho@gmail.com](mailto:f9filho@gmail.com) (F. Bernardes Filho).

<http://dx.doi.org/10.1016/j.bjid.2016.10.014>

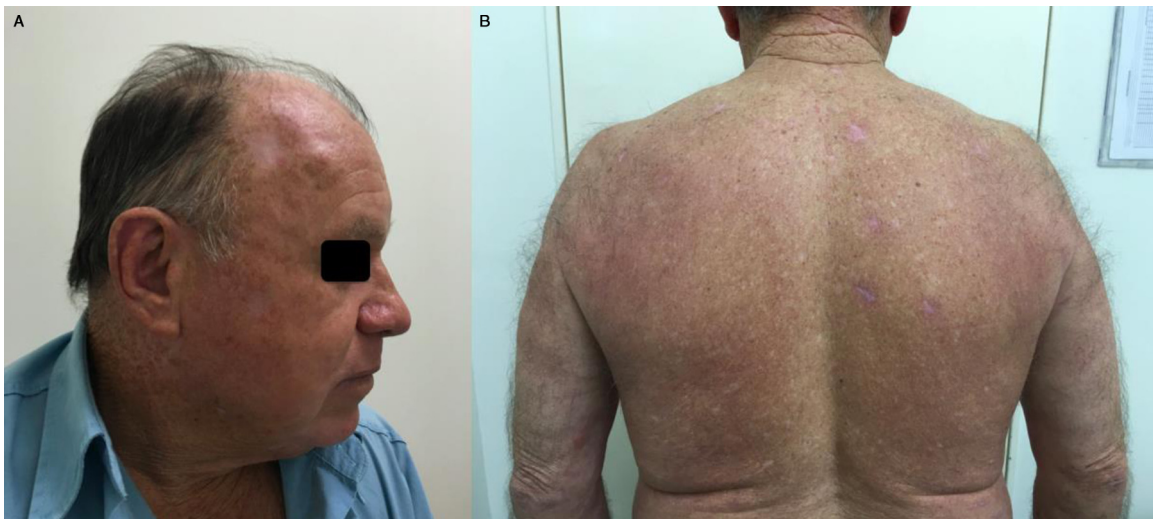1413-8670/© 2016 Sociedade Brasileira de Infectologia. Published by Elsevier Editora Ltda. This is an open access article under the CC BY-NC-ND license (<http://creativecommons.org/licenses/by-nc-nd/4.0/>).



**Fig. 1** – Multiple cutaneous ulcerovegetative and ulcero-crusted reddish lesions were observed on the ears, face, and scalp. Superficial involvement of mucosae was recognized on the nose.



**Fig. 2** – Papules, nodules, infiltrated erythemas were found on the dorsum. Induration of the lesions was palpable.



**Fig. 3** – Clinical cure after the treatment. (A) Absence of skin and mucosal lesions; (B) hypochromic-atrophic scars on the dorsum.

### Conflicts of interest

The authors declare no conflicts of interest.

### REFERENCES

1. Bernardes Filho F, Bonatto DC, Martins G, Maier LM, Nery JAC, Azulay-Abulafia L. Occurrence of two autochthonous cases of American cutaneous leishmaniasis in the neighborhood of Caju, city of Rio de Janeiro, Brazil. *An Bras Dermatol.* 2014;89:848–50.
2. Gelanew T, Hurissa Z, Diro E, et al. Disseminated cutaneous leishmaniasis resembling post-kala-azar dermal leishmaniasis caused by *Leishmania donovani* in three patients co-infected with visceral leishmaniasis and human immunodeficiency virus/acquired immunodeficiency syndrome in Ethiopia. *Am J Trop Med Hyg.* 2011;84:906–12.
3. Vernal S, De Paula NA, Gomes CM, Roselino AM. Disseminated leishmaniasis by *Leishmania viannia* subgenus: a series of 18 cases in southeastern Brazil. *Open Forum Infect Dis.* 2016;3:ofv184.