

Cryosurgery as adjuvant therapy in cutaneous sporotrichosis

Sporotrichosis is a subacute or chronic disease that affects animals and humans caused by the dimorphic fungus *Sporothrix schenckii*.¹ An epidemic of sporotrichosis has been noticed in the city of Rio de Janeiro from 1998 onwards and having the cat as the main link in the epidemiological chain.² We have missed a large proportion of these patients and adjuvant cryosurgery with liquid

nitrogen^{3,4} has been performed in patients that persisted with one or two active lesions whereas the other healed after 2-3 months of treatment. This study aims at evaluating the role of adjuvant treatment in these patients. Methods: 9 patients (7 women/2 men, mean age 45.8 years-old) with cutaneous-lymphatic and fixed sporotrichosis were selected (Figures 1 and 2). All patients

Authors

Cassio Porto Ferreira¹
Maria Clara Gutierrez Galhardo²

Antônio Carlos Francescone do Valle³

¹ MSc, Technologist; Dermatologist, Laboratory of Clinical Research in Infectious Dermatology (IPEC/FIOCRUZ)

² Post-Doctorate; Researcher, Laboratory of Clinical Research in Infectious Dermatology (IPEC/FIOCRUZ)

³ PhD; Researcher, Laboratory of Clinical Research in Infectious Dermatology (IPEC/FIOCRUZ)

Figure 1: Sporotrichosis: pre-treatment.

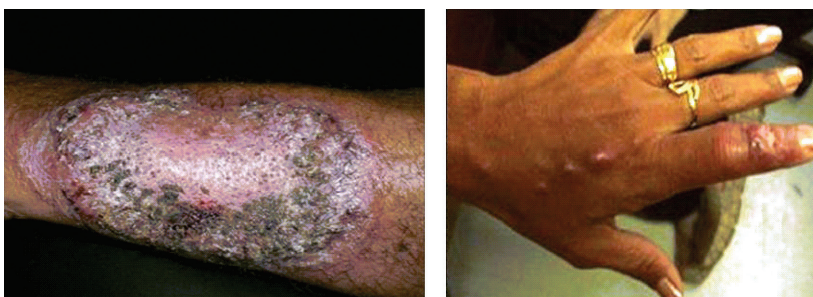
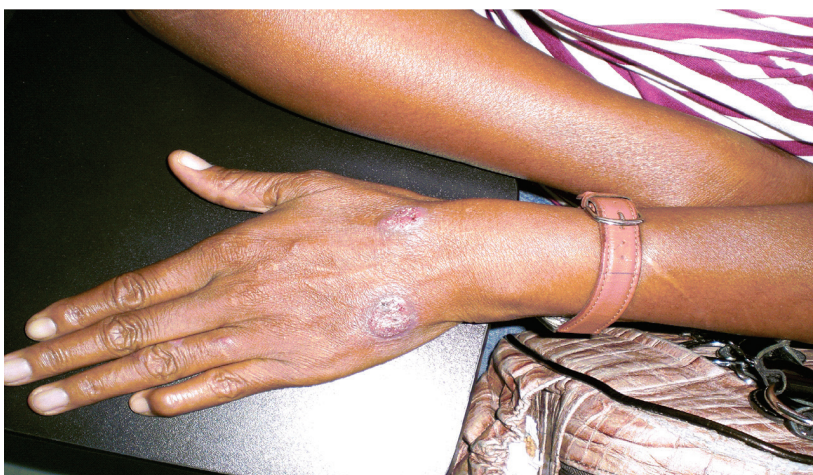
Figure 2: Sporotrichosis: before cryosurgery.



Submitted on: 9/29/2010

Approved on: 10/5/2010

Correspondence to:

Cassio Porto Ferreira
Av. Brasil 4365,
Manguinhos
Rio de Janeiro, Brazil
21040-900
Fax: 00.55-21-2209-4110
Phone:
00.55-21-3865-8102
drcassioferreira@yahoo.
com.br

We declare no conflict of interest.

had isolated *Sporothrix schenckii* in culture (Figure 3). Results: Patients underwent monthly sessions of cryosurgery with liquid nitrogen with two cycles of 15 seconds and halo of 5 mm (Figures 4 and 5) with an average of 2.2 sessions (range 1-4 sessions). Five patients had exclusive use of itraconazole for a mean period of 28.8 weeks (range 4-56 weeks) and after the introduction of adjuvant therapy were discharged after a mean period of 12 weeks (range 4-36 weeks). The patient who made use of potassium iodide was discharged after two adjuvant therapy ses-

sions, totaling 12 weeks of treatment. The three patients who used itraconazole and terbinafine, itraconazole used primarily by an average of 21.2 weeks and due to lack of response initiated terbinafine, which when combined with adjuvant therapy were discharged after a mean period of 16 weeks (range 4-28 weeks). In conclusion, cryosurgery with liquid nitrogen⁴ used in patients with slower response to systemic antifungal agents in a few sessions reduces treatment time and thus reducing cost and side effects.

[Braz J Infect Dis 2011;15(2):181-183]©Elsevier Editora Ltda.

Figure 3: Dimorphic fungus *Sporothrix schenckii*. (A): mycelium form (250C); (B): yeast form (370C).

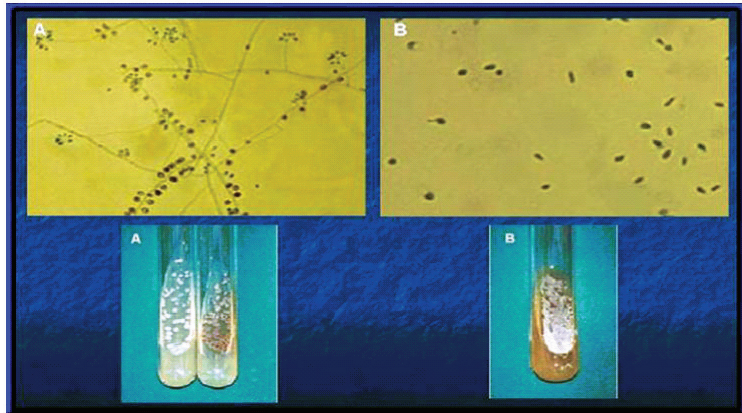
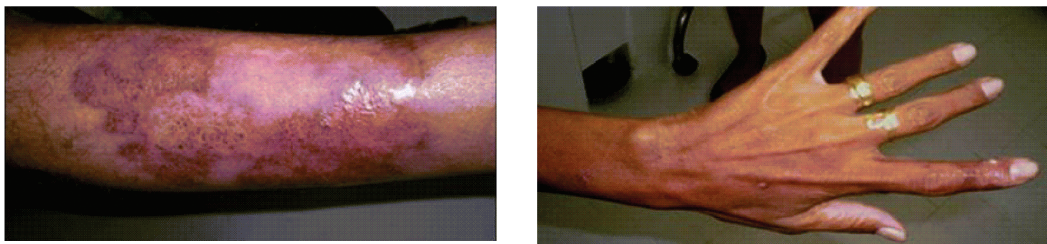


Figure 4: Technique of cryosurgery with liquid nitrogen and halo.

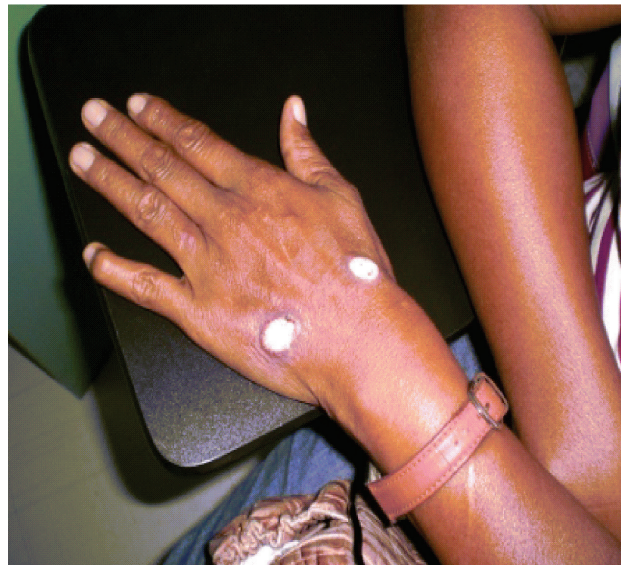

Figure 5: Sporotrichosis: post-treatment.



REFERENCES

1. de Lima Barros MB, de Oliveira Schubach A, Galhardo MC *et al.* Sporotrichosis with widespread cutaneous lesions: report of 24 cases related to transmission by domestic cats in Rio de Janeiro, Brazil. *Int J Dermatol* 2003; 42:677-681.
2. Barros MB, Schubach A de O, do Valle AC *et al.* Cat-transmitted sporotrichosis epidemic in Rio de Janeiro, Brazil: description of a series of cases. *Clin Infect Dis.* 2004; 38:529-35.
3. Moraes AM, Velho PENFV, Magalhães RF. Criocirurgia com nitrogênio líquido e as dermatoses infecciosas. *An Bras Dermatol.* 2008; 83(4):285-98.
4. Bargman H. Successful treatment of cutaneous sporotrichosis with liquid nitrogen: report of three cases. *Mycoses;* 1995; 38:285-7.