

Bilateral Facial Palsy Associated With Leptospirosis

Andressa Alves da Silva¹, Marcelo Ducroquet² and Jeff Chandler Pedrozo Junior³

¹Internal Medicine Department, Hospital de Clínicas da Universidade Federal do Paraná; ²Department of Emergency Medicine, Universidade Federal do Paraná, Associate Professor of Infectious Diseases, Universidade Positivo; Medical Student, Universidade Federal do Paraná; Curitiba, PR, Brazil

Leptospirosis is a zoonosis of worldwide occurrence caused by the spirochete *Leptospira interrogans*. It is an acute feverish disease with a broad clinical spectrum and follows a characteristic biphasic course. Bilateral facial palsy is a rare clinical condition and the differential diagnosis of its causes is extensive. The objective of this exploratory study, presented as a case report, is to describe the occurrence of bilateral facial palsy as an unusual manifestation of leptospirosis. This suggestion should not be overlooked when analyzing the causes for bilateral facial palsy, and should be considered with other possible differential diagnoses, some of which are potentially fatal.

Key-Words: Leptospirosis, bilateral facial palsy.

Leptospirosis is a zoonosis occurring worldwide and is caused by the infectious agent *Leptospira interrogans*. The disease occurs where the sanitary infrastructure is precarious and infected rodents proliferate. It is endemic in Brazil and its incidence is rising particularly during times of heavy rain and flooding, generally from January to April. Data provided by the Damage Notification Information System (*Sistema de Informação de Agravos de Notificação - SINAN*), indicates that 4334 cases of leptospirosis were notified in 2006 – two new cases per year for each 10,000 of the population. Among the reported cases, 273 occurred in the state of Paraná - the sixth greatest incidence among the Brazilian states [1]. Leptospirosis is an acute feverish disease with a broad clinical spectrum and a characteristic biphasic course (leptospiemia and immune phases). Numerous neurological manifestations have been described during the immune phase [2-12].

Bilateral facial palsy is a rare clinical condition, with an incidence of approximately one per five million per year [13]. Unlike unilateral palsy, the bilateral form is rarely considered idiopathic – only 20% of the cases – and frequently indicates a potentially severe subjacent condition [13]. Up to the present, few reports on the association between facial palsy and leptospirosis have been located in the literature [10-12], and only one of these previous reports refers to the bilateral form [11].

The objective of this study is to describe and present a most unusual occurrence of a patient suffering from leptospirosis who developed bilateral facial palsy in the course of the disease. The patient signed an informed consent for the use of photographs and clinical data derived from the hospital records in this case report.

Case Report

In August 2007, a 56-year-old man born and resident in *Cerro Azul* in the southern Brazilian State of Paraná who

Received on 20 May 2009; revised 6 July 2009.

Address for correspondence: Dr. Andressa Alves da Silva. Av. Ceres, 129, ap 905, CEP 91530-030, Porto Alegre - RS, Brazil. Phone: (International) +555191807469; (Brazil) (051)91807469. E-mail: andressa.ads@gmail.com.

The Brazilian Journal of Infectious Diseases 2009;13(4):319-321.
© 2009 by The Brazilian Journal of Infectious Diseases and Contexto Publishing. All rights reserved.

worked in reforestation and the extraction of eucalyptus lumber, was admitted to the emergency ward of the *Hospital de Clínicas* of the Federal University of Paraná, Brazil. Previously healthy, he had developed fever, weakness, oliguria, nausea, diffuse abdominal pain and myalgia, particularly in the calves of the legs, nine days before admission. On the fifth day after the symptoms initiated, he presented ocular hyperemia and jaundice.

During the clinical examination, the vital signs were normal, and he did not have a fever. There were obvious signs of rubinic jaundice, ocular hyperemia, and discrete hepatomegaly while gentle palpation of the abdomen and calves caused considerable pain. Neither signs of meningeal irritation nor cardiac or pulmonary alterations were detected.

The initial laboratory examinations showed left shift leukocytosis (15,310 leukocytes and 12% of rod neutrophils) and thrombocytopenia (123,000 platelets). Serum creatinine was 5.4mg/dL (normal: 0.3-1.2mg/dL) and urea 191mg/dL (normal: 10-50mg/dL), with serum potassium of 3.8mmol/L (normal:3.5-5.0mmol/L). Aspartate aminotransferase (AST) and alanine aminotransferase (ALT) were normal. Total bilirubin was 5.75mg/dL (normal: 0.3-1.3mg/dL), with a prevalence of direct fraction (4.39/dL). Creatinine kinase (CK) was 90 U/L (normal: 0 – 190 U/l) and hemosedimentation velocity of 90mm/h. Imaging studies of the abdomen (radiography and ultrasonography) were performed, both were found normal. A lumbar puncture was not performed initially.

Because of the clinical and laboratorial findings, the patient was transferred to the semi-intensive therapy center with a diagnostic hypothesis of leptospirosis. Supportive care was initiated, with emphasis on the volemic reposition to improve the renal function. Antibiotic therapy was not used because its efficacy is uncertain when the period from the onset of the symptoms is greater than five days.

On the fifth day of hospitalization, when hospital discharge was being considered due to the significant clinical and laboratorial improvement, bilateral peripheral facial palsy was diagnosed with upper and lower facial involvement together with bilateral Bell's phenomenon (Figure 1). Other cranial pairs, motricity, sensibility and reflexes were preserved. There was no history of previous trauma, epidemiology and clinical signs

of Lyme disease or new biochemical or hematologic findings. Serum VDRL and HIV test were negative. The analysis of the cerebrospinal fluid was performed on the sixth day after admission, and showed 10 red blood cells/mm³, 16.9 leukocytes/mm³ with 100% lymphocytes, glucose of 59mg/dL (normal: 50-80mg/dL) and protein level of 39mg/dL (normal: 15-45 mg/dL). A second lumbar puncture was performed five days later with similar results in the cerebrospinal fluid analysis. An electroneuromyography was executed and demonstrated bilateral axonal neuropathy of the facial nerve. Prednisone 40 mg daily was initiated and terminated gradually after seven days.

The patient was discharged to his home on the eleventh day after admission. He showed partial improvement on the neurological symptoms and prednisone was prescribed on a step-down course.

The leptospirosis diagnosis was confirmed by the ELISA IgM test from a blood sample collected on the tenth day from the beginning of the symptoms. A sample of cerebrospinal fluid was sent for microagglutination test for leptospirosis but the result was negative.

The patient was evaluated again in the outpatient's clinic two months after hospital discharge and at that time he presented complete recovery from bilateral facial palsy (Figure 2).

Discussion

This exploratory study, prepared as a case report, is justified by the rare character of the occurrence. Although there are limitations with respect to the true relation between the symptom and the disease, this study should contribute to scientific knowledge of the subject and facilitate communication among clinical investigators, because it draws attention to factors that in our opinion ought to be further analyzed in studies with greater discriminative capabilities.

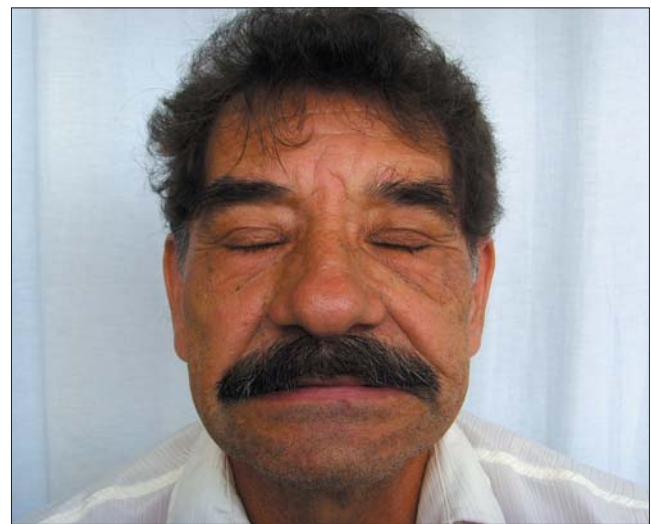
The differential diagnosis of the causes for bilateral facial palsy covers a wide field, including genetic, infectious, traumatic, neoplastic, metabolic, neurological, vascular, iatrogenic and idiopathic etiologies. The most common causes are Lyme disease, Guillain-Barré syndrome, Bell's palsy (idiopathic), leukemia, sarcoidosis, bacterial meningitis, syphilis, Hansen's disease, Moebius syndrome, infectious mononucleosis and cranial fracture [13]. Among the infectious diseases, leptospirosis needs to be considered despite the rareness of incidence. In the case mentioned, the clinical and laboratory findings were typical of those of Weil's disease, an icterohemorrhagic form of leptospirosis. The other causes of bilateral facial palsy cited above were excluded by the medical history and/or additional testing, as described in this document.

Nevertheless, we emphasize the importance of a differential diagnosis for Guillain-Barré syndrome. It is an acute inflammatory demyelinating polyneuropathy of post-infectious occurrence. The clinical presentation is variable and initially tends to produce motor damage of the inferior

Figure 1. Patient with bilateral facial palsy hospitalized for treatment of leptospirosis.

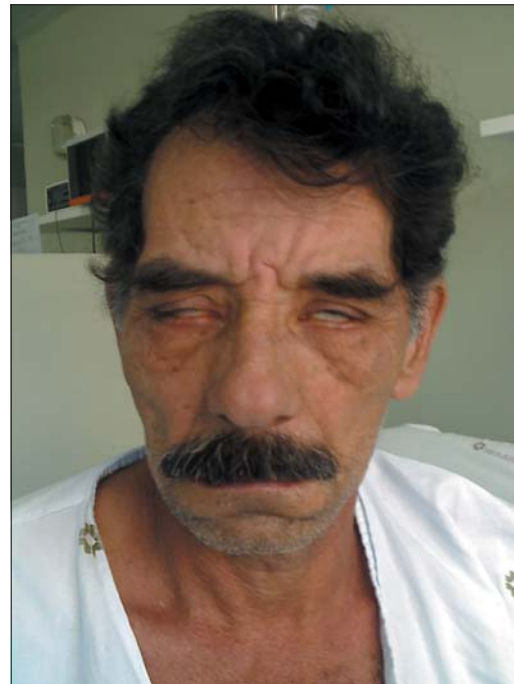

Figure 2. Patient completely recovered from bilateral facial palsy after two months.



limbs with ascending characteristics and areflexia. The facial nerve is affected in at least 50% of the cases and is usually associated with other motor symptoms. Bilateral facial palsy is also described, and may be the only clinical manifestation of the disease [14-15]. Moreover, in more than 50% of the fatal cases, bilateral facial palsy occurred [13]. The presence of a high level of protein with normal cellular content in the cerebrospinal fluid and demyelinating conduction abnormalities, associated to the clinical findings, confirm the diagnosis [14-15]. In the case presented above, there was no

clinical sign of the syndrome other than the facial paralysis and the cerebrospinal fluid was normal. Thus, Leptospirosis remains as the probable triggering factor for bilateral facial palsy.

Leptospirosis is a zoonose found worldwide which is caused by the spirochete *Leptospira interrogans*. It is an acute feverish disease with a broad clinical spectrum and follows a characteristic biphasic course. The acute or septicaemic phase lasts approximately one week, followed by the immune phase that runs a thirty-day course. The pathogenesis of leptospirosis remains uncertain. A direct effect of *Leptospira interrogans* would be most probable in the phase of leptospiremia, because the systemic vasculitis occurring in the immune phase is probably responsible for the majority of the complications observed [16-17].

Neurological manifestations are frequent in leptospirosis, especially aseptic meningitis [2]. Other syndromes described include cerebrovascular accidents [5-6], polyneuropathies [7], transverse myelitis [3], Guillain-Barré syndrome [4], mononeuritis multiplex [8-9] and cranial nerve palsies [10-12]. However, the occurrence of facial paralysis, especially the bilateral form, is uncommon. No data is found in the literature on the incidence of this condition associated with leptospirosis. A research performed through the PubMed database turned up only one case of bilateral facial palsy attributed to leptospirosis. [12]. As in the cases previously reported [11-12], the development of the facial palsy herein reported occurred in the convalescence period of the immune phase – the fourteenth day in the present study – when the symptoms of the disease had already decreased. This fact is consistent with the hypothesis that facial paralysis associated to infectious diseases must be mediated by immunological mechanisms. One possible theory is that the immunologic response associated with the infection triggers a cranial or generalized polyneuropathy culminating in facial nerve compression, degeneration and paralysis [18].

Final Considerations

Although it is not possible to exclude the possibility that both conditions occurred simultaneously by coincidence, we believe that bilateral facial palsy should be included amongst the clinical manifestations deriving from leptospirosis, as a direct consequence of systemic vasculitis observed during

the immune phase of the disease. Thus, this condition should not be overlooked in investigating the causes for bilateral facial palsy considering the possible differential diagnosis, some of which are potentially fatal.

References

1. Brazil, Ministério da Saúde. Informações de Saúde, 2008. Available from: URL: <http://www.datasus.gov.br>
2. Karande S, Patil S, Kulkarni M, Joshi A, Bharadwaj R. Acute aseptic meningitis as the only presenting feature of leptospirosis. *Pediatr Infect Dis* 2005; 24:390-1.
3. Heath CW, Alexander AD, Galton MM. Leptospirosis in the United States: analysis of 483 cases in man, 1949-1961. *N Engl J Med* 1965; 273:1-15.
4. Morgan AG, Cawish F. Ascending polyneuropathy in leptospirosis: a case study. *Ann Trop Med Parasitol* 1980; 74:567-8.
5. Lessa I, Cortes E. Cerebrovascular accident as a complication of leptospirosis. *Lancet* 1981; 2:1113.
6. Forwell MA, Redding PG, Brodie MJ et al. Leptospirosis complicated by fatal intracerebral haemorrhage. *Br Med J* 1984; 289:1583.
7. Azouvi P, Hostachy T, Desi M, Said G. Polyneuropathie axonale aigue et reversible dans les suites d'une leptospirose. *Rev Neurol* 1989; 145:805-7.
8. Yaqoob M, Ahmad R. Mononeuritis multiplex as an unusual complication of leptospirosis. *J Infect* 1989; 19:188-9.
9. Hancox RJ, Karalus N, Singh V. Mononeuritis multiplex in leptospirosis. *Scand J Infect Dis* 1991; 23:395-6.
10. Sharma OP, Eltahir N, Roy M. Facial palsy in a patient with leptospirosis: causal or accidental. *Sarcoidosis Vasc Diffuse Lung Dis* 1999 mar; 16(1):104-6.
11. Costa E, Sacramento E, Lopes AA, Bina JC. Facial nerve palsy associated with leptospirosis. *Rev Soc Bras Med Trop* 2001 mar-abr; 34(2):219-20.
12. Maldonado F, Portier H, Kisterman JP. Bilateral facial palsy in a case of leptospirosis. *Scand J Infect Dis* 2004; 36:386-8.
13. Price T, Fife DG. Bilateral simultaneous facial nerve palsy. *J Laryngol Otol* 2002; 116:46-8.
14. García Callejo FJ, Velert Vila MM, Pardo Mateu L, Mallea Cañizares I, Marco Algarra J. Bilateral peripheral facial paralysis and Guillain-Barré syndrome. *Acta Otorrinolaringol Esp* 1998 oct; 49(7):561-8.
15. Piñol Ripoll G, Larrodé Pellicer P, de la Puerta González-Miró I, Tejero Juste C, Iñiguez Martínez C, Santos Lasaosa S et al. Facial diplegia: a regional variant of Guillain-Barré syndrome. *An Med Interna* 2007 jan; 24(1):24-6.
16. Levett PN. Leptospirosis. In: *Clinical microbiology reviews*. American Society for Microbiology 2001; 14(2):296-326.
17. Souza AL, Sztajnbock J, Spichler A, Carvalho SM, Oliveira ACP, Seguro AC. Peripheral nerve palsy in a case of leptospirosis. *Royal Society of Tropical Medicine and Hygiene* 2006; 100:701-3.
18. Morgan M, Nathwani D. Facial palsy and infection: the unfolding story. *Clin Infect Dis* 1992; 14(1):263-71.