



The Brazilian Journal of INFECTIOUS DISEASES

www.elsevier.com/locate/bjid



Clinical Images

Terry's nails

A 64-year-old man with cirrhosis associated with hepatitis B virus infection presented to the hospital with dystrophy and slurred speech for nine hours. He had been on lamivudine for five years. Physical examination showed uniform abnormalities of his fingernails (Fig. 1A). All of his fingernails revealed a distal thin brown to pink transverse band of 0.5-2.0 mm in width, white nail bed, and absence of the lunula (Fig. 1B), characteristic findings of Terry's nails.

This characteristic nail pattern is classically associated with liver cirrhosis.¹ It is also associated with congestive heart disease, adult-onset diabetes mellitus, thyrotoxicosis, malnutrition, and advanced age.¹⁻³ Fully developed Terry's nails exhibit a ground-glass-like opacity of almost the entire nail bed. The condition is bilaterally symmetrical, with a tendency to be more marked in the thumb and forefinger.¹ The mechanism underlying white nails has not yet been clarified, although the pathological findings showed

telangiectasias at distal band and proximal nail region.³ Neither hypoalbuminaemia or anaemia nor the severity of liver cirrhosis have a relationship with Terry's nails and the width of the distal color band of the nails.³

The most important differential diagnosis of Terry's nails is the uremic half-and-half nails, which are typically seen in chronic renal failure. The clinical differentiation of both nail-bed abnormalities are the transverse band in the latter commonly occupies 20% to 60% of the nail length.⁴ The easily recognizable abnormality of the nail bed should alert clinicians to the possibility of an underlying systemic disease, especially advanced liver diseases.

Conflict of interest

All authors declare to have no conflict of interest.

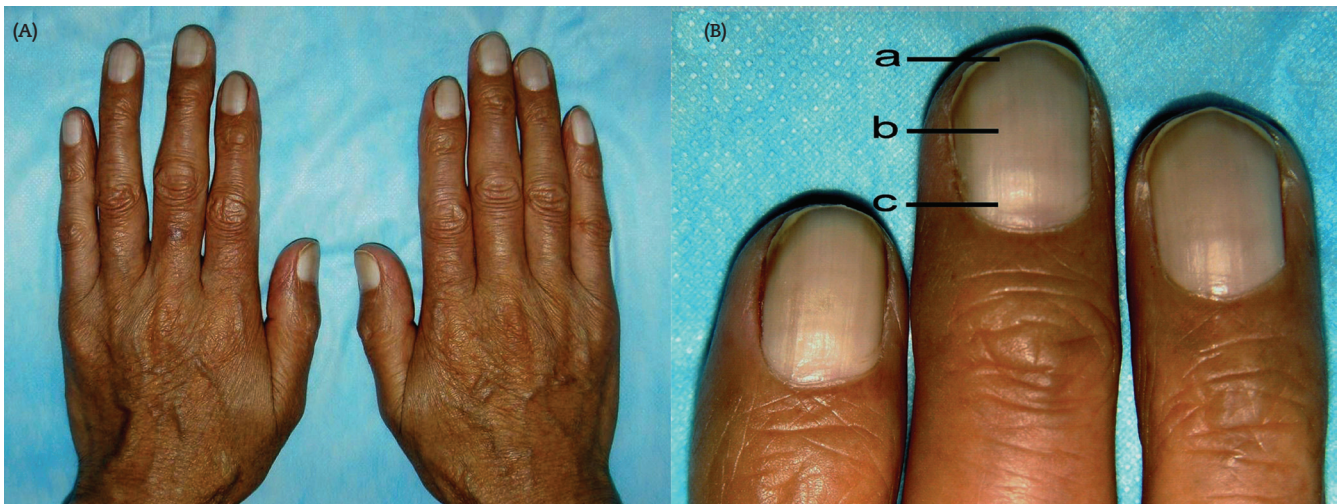


Fig. 1 - (A) All of the fingernails have a white nail bed; (B-a) a distal thin brown transverse band of 1.0 millimetres in width; (B-b) white nail bed; (B-c) lunula is not present in right middle finger.

R E F E R E N C E S

1. Terry R. White nails in hepatic cirrhosis. *Lancet*. 1954;266:757-9.
2. Nia AM, Ederer S, Dahlem KM, Gassanov N, Er F. Terry's nails: a window to systemic diseases. *Am J Med*. 2011;124:602-4.
3. Holzberg M, Walker HK. Terry's nails: revised definition and new correlations. *Lancet*. 1984;323:896-9.
4. Lindsay PG. The half-and-half nail. *Arch Intern Med*. 1967;119:583-7.

Zhengxiao Li
Department of Dermatology and Venereology, The Second Affiliated Hospital, College of Medicine, Xi'an Jiaotong University, China

Fanpu Ji*, Hong Deng
Department of Infectious Diseases, The Second Affiliated Hospital, College of Medicine, Xi'an Jiaotong University, China

*Corresponding author. Department of Infectious Diseases,
The Second Affiliated Hospital, College of Medicine,
Xi'an Jiaotong University, 157 Xi Wu Road, Xi'an 710004,
Shaanxi Province, China
E-mail address: jifanpu1979@163.com

Received 1 November 2011

Accepted 5 November 2011

1413-8670

© 2012 Elsevier Editora Ltda. All rights reserved.