



# The Brazilian Journal of INFECTIOUS DISEASES

www.elsevier.com/locate/bjid



## Case report

# New therapy of pleural empyema by deoxyribonuclease

Grzegorz Kacprzak<sup>a</sup>, Andrzej Majewski<sup>a,b</sup>, Jerzy Kolodziej<sup>a</sup>, Adam Rzechonek<sup>a</sup>,  
Robert Gürlich<sup>c</sup>, Vladimír Bobek<sup>a,c,d,\*</sup>

<sup>a</sup> Wrocław Thoracic Surgery Centre, Department of Thoracic Surgery of Lower Silesian Centre, Department of Thoracic Surgery of Medical University Wrocław, Poland

<sup>b</sup> Department of Thoracic Surgery, Nottingham City Hospital, Nottingham, UK

<sup>c</sup> Department of Surgery, 3rd Faculty of Medicine Charles University and Hospital Kralovské Vinohrady Prague, Czech Republic

<sup>d</sup> Department of Tumor Biology, 3rd Faculty of Medicine Charles University Prague, Czech Republic

## ARTICLE INFO

### Article history:

Received 23 March 2012

Accepted 5 August 2012

Available online 16 January 2013

### Keywords:

Empyema

Lung

Viscosity

Deoxyribonuclease

## ABSTRACT

Empyema is a severe complication of different diseases and traumas. Management of this complication is difficult and should comprise general and local procedures. The general procedure is mainly based on administering wide-spectrum antibiotics. Local management depends on patient general condition, but in all cases the essential procedure is to insert a drain into the pleural cavity and to evacuate the pus. Sometimes pus is very thick and its evacuation and following re-expansion of the lung is rather impossible. In these patients surgical intervention is needed. The use of intrapleural enzymes to support the drainage was first described in 1949 by Tillett and Sherry using a mixture of streptokinase and streptococcal deoxyribonuclease. Nowadays, purified streptokinase has come into widespread use, but recent studies reported no streptokinase effect on pus viscosity. On the other side, deoxyribonuclease reduces pus viscosity and may be more useful in treatment. We report two cases of intrapleural administration of Pulmozyme (alfa dornase – deoxyribonuclease (HOFFMANN-LA ROCHE AG) in dosage  $2 \times 2.5$  mg with a significant improvement caused by changes in pus viscosity.

© 2013 Elsevier Editora Ltda. All rights reserved.

In this study we describe case reports of two patients with pleural empyema treated by intrapleural administration of deoxyribonuclease (DNase).

### Patient no. 1

A 33-year-old male was admitted to the Pneumology Department because of chest pain on the right side, high

temperature ( $\pm 39^\circ\text{C}$ ) and weight loss of about 5 kg which has been observed within 3 weeks. Clinical examination and chest X-ray revealed a pleural empyema. Laboratory examination of the peripheral blood was done. (There were 20.9 K/ $\mu\text{L}$  leucocytes, 4.32 K/ $\mu\text{L}$  erythrocytes, 12.4 g/dL haemoglobin, 1.1  $\mu\text{mol/L}$  creatinine, 357.1 mg/L CRP protein, thrombocytes 406 K/ $\mu\text{L}$ , 4.6 mmol/L kalium, LDH 694 U/L, albumin 2.6 g/dL, GOT/AspAT 43 U/L, and GPT/ALAT 42 U/L) The patient was treated with intravenous broad spectrum

\* Corresponding author at: 3rd Faculty of Medicine Charles University Prague, Department of Tumor Biology, Ruska 87, 100 97 Prague, Czech Republic. Tel.: +420 267 102 108; fax: +420 267 102 650.

E-mail address: vbobek@centrum.cz (V. Bobek).

1413-8670/\$ – see front matter © 2013 Elsevier Editora Ltda. All rights reserved.

<http://dx.doi.org/10.1016/j.bjid.2012.08.019>

antibiotics: cefuroxim (Zinacef  $3 \times 750$  mg iv), amikacin (Biodacin  $2 \times 500$  mg iv), Metronidazol ( $3 \times 500$  mg iv). At the beginning microbiological cultivation was negative. Later *Staphylococcus aureus* K (-) metycilin resistant was detected. According to the sensitivity Lincomycin 600 mg iv every 8 h was introduced. Zinacef and Biodacin were put aside.

Thoracentesis was performed but no fluid was obtained. The patient was relocated to the Thoracic Surgery Centre, where the chest tube was inserted into the pleural cavity. Drain was inserted into the pleural cavity in local analgesia (1% lignocain). Drain (size 36) was introduced in the posterior axillary line in the VIII intercostal space and was connected to the sucking system 20 mmH<sub>2</sub>O. Ultrasonography of pleural cavity was done and loculated fluid was diagnosed. Second drain was introduced into the empyema cavity. Additionally the suppurative infiltration of the chest wall was confirmed. The incision of the chest wall was done and the second drainage (drain size 28) was introduced into the suppurative space of the chest wall. Drains were connected into the two different sucking systems. The position of both drains was controlled by X-ray. The effect of treatment was not satisfactory. During the first days only a small amount of pus from pleural cavity was removed because of high pus density. Within the first day the amount of pleural fluid was 300 mL, within the second only 30 mL, and on the third 20 mL. In the subsequent two days Pulmozyme was administered directly into the pleural cavity through the drain. The total amount of Pulmozyme administered was 5 mg. 2.5 mg of dornase alfa and 50 mL of normal saline were instilled into the pleural cavity daily for 2 consecutive days. The tube was clamped for 4 h after instillation of this agent. During this period patient changed the position (lateral, supine, face down position). On the day 1 after Pulmozyme application 900 mL of thin pus was drained; on the day 2, a further 300 mL of drainage was collected with

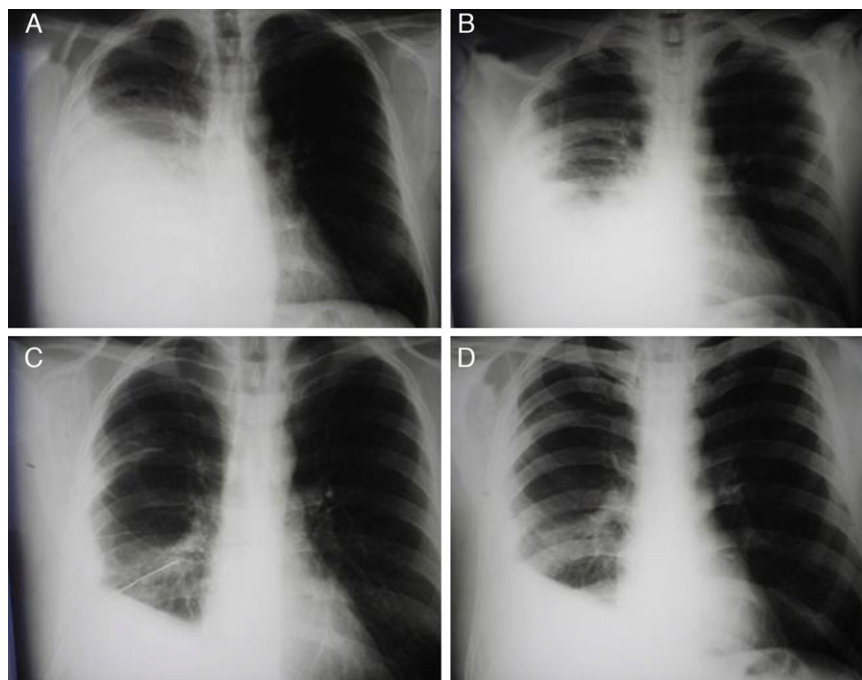
considerable improvement in the X-ray and the patient's clinical status. His appetite improved and temperature decreased. The chest drain was removed on day 10.

## Patient No. 2

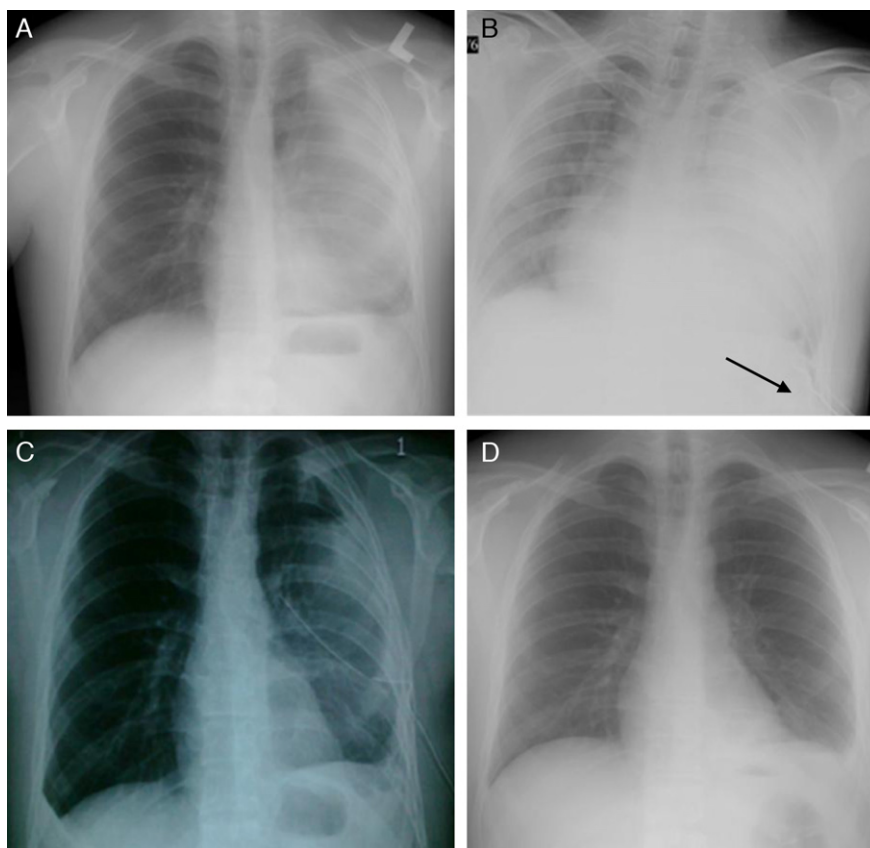
A 21-year-old male was admitted with a 4 weeks history of fevers and rigours with breathlessness. The patient was treated in out-patient regime by antibiotics (erythromycin) without microbiological investigation or antibiotic sensitivity testing. Thoracentesis was performed with evacuation of 100 mL of pus. The patient was relocated to the Thoracic Surgery Centre, where the chest tube was inserted into the pleural cavity. Drain was inserted into the pleural cavity in local analgesia (1% lignocain). Drain (size 32) was introduced in the posterior axillary line in the VIII intercostal space and was connected to the sucking system 20 mmH<sub>2</sub>O. Control ultrasonography and X-ray of pleural cavity were performed. The patient was treated with intravenous broad spectrum antibiotics: cefuroxim (Zinacef  $3 \times 750$  mg iv) amikacin (Biodacin  $2 \times 500$  mg iv), Metronidazol ( $3 \times 500$  mg iv). The *Streptococcus pneumoniae* was detected and examined as sensitive for applied antibiotics mentioned above.

Clinical examination and chest X-ray revealed a pleural empyema. Laboratory examination of the sample of the peripheral blood was done. (There were 16.7 K/ $\mu$ L leucocytes, 4.2 K/ $\mu$ L erythrocytes, 16.7 g/dL haemoglobin, 254 mg/L CRP protein, thrombocytes 412 K/ $\mu$ L, bilirubin total 0.5 mg/dL, kalium 4.1 mmol/L, LDH 594 U/L, albumin 2.9 g/dL, GOT/AspAT 47 U/L, and GPT/ALAT 45 U/L.)

During the first days only a small amount of pus from pleural cavity was removed because of high pus density. On day 1 the amount of pleural fluid was 220 mL, day 2 only 80 mL,



**Fig. 1 – Patient no. 1. (A) Chest X-ray performed before treatment. (B) Chest X-ray performed after inserting drain. (C) Chest X-ray performed after introducing two doses of Pulmozyme. (D) Chest X-ray performed after removing drain.**



**Fig. 2 – Patient no. 2. (A) Chest X-ray performed before treatment. (B) Chest X-ray performed after inserting drain. (C) Chest X-ray performed after introducing two doses of Pulmozyme. (D) Chest X-ray performed after removing drain.**

and day 3 – 40 mL. In the subsequent two days Pulmozyme was administered directly into the pleural cavity through the drain. The total amount of the administered Pulmozyme was 5 mg. 2.5 mg of dornase alfa and 50 mL of normal saline were instilled into the pleural cavity daily for 2 consecutive days. The tube was clamped for 4 h after instillation of this agent. On first day after Pulmozyme application 700 mL of thin pus was drained; on second day a further 400 mL of drainage was obtained with considerable improvement in the X-ray and the patient's clinical status. His appetite improved and temperature decreased. The chest drain was removed on day 12.

In both patients the first chest X-ray (Figs. 1A and 2A) was performed before treatment and the last one (Figs. 1D and 2D) after removing the drain. After release from the hospital the patient was controlled in the hospital outpatient clinic. The X-ray done after 1 month was better than the ones shown in Fig. 2.

### Measurement of viscosity

To measure drainability a 2 mL medical syringe fitted with 1.2 × 40 (18G × 1<sup>1/2</sup>”) needle was used.

#### Patient no. 1

The measurement of viscosity before instillation of the dornase alfa was 56 drops/min. After instillation of the first

dornase alfa dose it was 210 drops/min and after the second dose 225 drops/min.

#### Patient no. 2

The viscosity before instillation of dornase alfa was 10 drops/min and after instillation of dornase alfa 86 drops/min.

### Discussion

Successful treatment of pleural empyema depends on adequate drainage of pleural cavity. There are other factors which prevent successful drainage by intercostals tube: chest tube size, loculation of the fluid and increasing viscosity, and adherence of the pus to the pleural surfaces, possibly preventing lung re-expansion by coating the visceral pleura. There are many studies which suggest to use intra-pleural fibrinolytic therapy especially streptokinase and urokinase in treatment of multiloculated pleural empyemas with good success rate. Some authors suggest that intrapleural instillation of fibrinolytic agents appears to be an effective and less invasive alternative to surgical treatment.<sup>3-6</sup> The results of some control studies using purified streptokinase are divergent.<sup>7,8</sup> Simpson et al. suggest that purified streptokinase was less effective than the older drug preparation which has contained a small proportion of streptococcal DNase.<sup>2,9</sup>

In the randomized, multicentre trial (MIST-1) the positive effect of streptokinase in pleural infections could not be substantiated.<sup>10</sup>

Although streptokinase lyses adhesions, it does not reduce pus viscosity.<sup>2</sup> It is possible that combination of agents that reduce pus viscosity and break down loculations may be more effective in the infected pleural space drainage. Recently, an intrapleural DNase-administration could be used in combination with thrombolytic therapy to enhance pus drainage. In an animal model, the combination of recombinant tissue plasminogen activator (alteplase) and recombinant human deoxyribonuclease (rhDNase) has been shown to be more effective in treating empyema than either agent used alone.<sup>11</sup>

Intrapleural use of a fibrinolytic agent (to disrupt adhesions) and DNase (to decrease pus viscosity) may promote efficient drainage of pus in empyema. This should be confirmed by the recently completed Multi-centre Intrapleural Sepsis Trial (MIST-2). To date, this is the largest, multicentre, randomized, controlled trial, in which patients were randomized in a 1:1 fashion into 4 treatment arms. The four treatment groups included: (1) fibrinolytics plus DNase; (2) fibrinolytics alone; (3) DNase alone; and (4) saline.

Combination of intrapleural tPA/DNase was significantly superior to the other combinations in improving pleural fluid drainage. DNase or tPA alone are ineffective. The proportion of patients dying or requiring surgery for their infection was higher in the DNase and saline group.

Pulmozyme is a recombinant DNase that digests DNA in the mucous secretions in lungs. Alteplase and Reteplase are the second generation recombinant tPAs. Pulmozyme cleaves extracellular DNA in mucus of cystic fibrosis patients, reducing the adhesiveness and viscoelasticity of the mucus.

Human recombinant DNase seems to be extremely safe and effective when it is administered by nebulization in the treatment of cystic fibrosis.<sup>1</sup> Similarly, treating empyema by DNase could be promising for patients in future.

## Conclusion

Pulmozyme may be used in some patients with pleural empyema with good results.

## Conflict of interest

All authors declare no conflict of interest.

## Acknowledgement

Supported by the Research project P 27/2012 awarded by Charles University in Prague, 3rd Faculty of Medicine, Prague, Czech Republic.

## REFERENCES

1. Tillet WS, Sherry S. The effect in patients of streptococcal fibrinolysin (streptokinase) and streptococcal deoxyribonuclease on fibrinous, purulent and sanguineous pleural exudations. *J Clin Invest.* 1949;28:173-90.
2. Simpson G, Roomes D, Herron M. The effects of streptokinase and deoxyribonuclease on viscosity of human surgical and empyema pus. *Chest.* 2000;117:1728-33.
3. Khan N, Mian I, Javed A, Wazir S, Yousaf M. Efficacy, safety and tolerability of streptokinase in multiloculated empyema. *J Ayub Med Coll Abbottabad.* 2003;15:20-2.
4. Cochran JB, Tecklenburg FW, Turner RB. Intrapleural instillation of fibrinolytic agents for treatment of pleural empyema. *Pediatr Crit Care Med.* 2003;4:39-43.
5. Banga A, Khilnani GC, Sharma SK, Dey AB, Wig N, Banga N. A study of empyema thoracis and role of intrapleural streptokinase in its management. *BMC Infect Dis.* 2004;4:19.
6. Barthwal MS, Deoskar RB, Rajan KE, Chatterjee RS. Intrapleural streptokinase in complicated parapneumonic effusions and empyema. *Indian J Chest Dis Allied Sci.* 2004;46:257-61.
7. Davies RJO, Traill ZC, Gleeson FV. Randomised controlled trial of intrapleural streptokinase in community acquired pleural infection. *Thorax.* 1997;52:416-21.
8. Chin NK, Lim TK. Controlled trial of intrapleural streptokinase in the treatment of pleural empyema and complicated parapneumonic effusions. *Chest.* 1997;111:275-9.
9. Simpson G, Roomes D, Reeves B. Successful treatment of empyema thoracis with human recombinant deoxyribonuclease. *Thorax.* 2003;58:365-6.
10. Maskell NA, Davies CW, Nunn AJ, et al. U.K. controlled trial of intrapleural streptokinase for pleural infection. *N Engl J Med.* 2005;352:865-74.
11. Zhu Z, Hawthorne ML, Guo Y, et al. Tissue plasminogen activator combined with human recombinant deoxyribonuclease is effective therapy for empyema in a rabbit model. *Chest.* 2006;129:1577-83.