

Successful treatment of pulmonary *Nocardia farcinica* infection with linezolid: case report and literature review

Authors

Tian Shen¹
Lihua Wu¹
Lei Geng¹
Zeqing Wei¹
Shusen Zheng¹

¹Key Laboratory of Combined Multi-organ Transplantation, Ministry of Public Health, Department of Hepatobiliary and Pancreatic Surgery, the First Affiliated Hospital, Zhejiang University School of Medicine, Hangzhou, China

Submitted on: 03/16/2011
Approved on: 04/26/2011

Correspondence to:

Shusen Zheng
First Affiliated Hospital
Zhejiang University
School of Medicine
Qingchun Road 79#
Hangzhou 310003, China
shentian17@yahoo.com.cn

Financial Support: This work was Supported by National Basic Research Program of China (973 Program) (No.2009CB522403).

We declare no conflict of interest.

©2011 Elsevier Editora Ltda.
All rights reserved.

ABSTRACT

Nocardia infection is rare but potentially fatal. Therapy of *Nocardia* infection remains difficult. Linezolid, a novel oxazolidinone antibiotic, has proven to be effective, but clinical data are limited. Here we describe a case of a 45-year-old man with pulmonary *N. farcinica* infection following a liver transplantation. The initial therapy was trimethoprim-sulfamethoxazole, which showed no effect. According to susceptibility test, linezolid was administered with clearly improving the patient's condition. The treatment was stopped for anemia as drug related adverse event, and the therapy lasted for as long as 5 months. At the end of treatment clinical cure was confirmed and anemia reversed after discontinuation of linezolid. We also analyzed the clinical data of previously published reports by literature review, focusing on the efficacy and safety of linezolid treatment for *Nocardia* infection.

Keywords: *Nocardia*; linezolid; drug therapy; transplantation.

INTRODUCTION

Nocardia species are widespread ubiquitous saprophytes, showing positive and filamentous bacilli in Gram staining.¹ T lymphocyte-mediated immune response plays a dominant role in preventing *Nocardia* infection.² Therefore, the most common underlying conditions happen in immunosuppressive hosts, and solid organ transplant recipients are predominant in the population susceptible to *Nocardia* infection.^{1,3,4} The reported prevalence of *Nocardia* infection in solid organ transplant recipients varies between 0.7-3.5%.³ *Nocardia* infection demonstrates a variety of clinical and radiologic manifestations. The microorganism mostly prefers to affect lung, ranging from granulomatous to purulent, subacute to chronic infection, and other organs such as brain, skin, bone, kidney and testis may be attacked as well.^{1,3-5}

In spite of the low incidence, *Nocardia* infection is potentially lethal, with high morbidity and mortality. In some large scale studies, the mortality rate is about 14%, and for patients with central nervous system (CNS) infection, it may be as high as 50%.^{1,3,4} Therapy is quite difficult. Drug resistance, drug related adverse events, absence of effective oral antibiotics for long-term therapy (pulmonary infection should be treated for 6 months, and if CNS is involved, it must be prolonged for 9-12

months), recurrence of infection and drug interactions are all major limitations.^{1,3} The best antibiotic therapy has not been well established. Conventional regimens include trimethoprim-sulfamethoxazole (TMP-SMX), amikacin, imipenem, cephalosporin, minocycline and so on, but the prognosis remains depressing.^{1,3,4} Linezolid has emerged as an attractive drug for *Nocardia* infection in recent years, but the efficacy, feasibility and safety of linezolid treatment has not been well discussed.

Here we describe a patient with pulmonary *Nocardia farcinica* infection treated successfully by linezolid following a liver transplantation.

CASE REPORT

A 45-year-old man underwent living donor liver transplantation on June 11, 2009 for subacute liver failure due to hepatitis B. Surgical technique and perioperative treatment were performed according to standard protocol. The early post-transplant course was unremarkable. Immunosuppressive agents consisted of tacrolimus (1 mg, q12h, orally), mycophenolate mofetil (500 mg, q12h, orally) and methylprednisolone [1,000 mg, intravenously (IV), only used during operation]. The concentration of tacrolimus varied between 8 and 10 ng/mL. Sulbactam/cefoperazone was administered for prophylaxis for a period of

two weeks. The allograft had played normal function one week after transplantation.

However, the patient developed an episode of acute rejection on the 10th postoperative day, which was confirmed by pathology. He was then treated with high dose IV steroids. At the same time, the dose of tacrolimus was increased to 15 ng/mL. His liver function gradually got better. On the 15th postoperative day, he started presenting fever as high as 38.5°C, and cough with little expectoration. Physical examination was inconclusive. Laboratory investigation showed leucocytosis (15.4 x 10⁹/L, of which 89.8% granulocytes), and an elevated C-reactive protein (105 ng/mL). A computed tomography (CT) showed a 3-cm large nodule affecting the lower lobe of his left lung (Figure 1A). The immunosuppression then tapered off and empiric antimicrobial therapy was administered (ceftriaxone and voriconazole), showing, however, no clinical improvement. The patient developed chest pain and mild dyspnea, in combination with more sputum. Culture of sputum did not provide useful information. In order to define the etiology, we performed a fine needle lung biopsy guided by CT on the 17th postoperative day. Five days later, culture of lung tissue turned out positive for *Nocardia* species (Figure 2) and the biopsy revealed abscess in pathology. Therefore, diagnosis of nocardial pneumonia was established. We performed magnetic resonance imaging (MRI) of the brain to exclude cerebral abscess. The initial therapy was oral TMP-SMX (TMP 160 mg and SMX 800 mg three times a day) for three days with no improvement. Then another CT showed the lesion had become larger with formation of abscess, infiltration and pleural effusion (Figure 1B). At the time, the bacilli were identified as *N. farcinica*, which was resistant to cotrimoxazole but sensitive to amikacin, linezolid and amoxicillin/clavulanic acid. The antibiotic treatment was then set to linezolid (600 mg, twice a day, IV).

The patient's clinical symptoms and laboratory data improved quickly after use of linezolid. Clear resolution of the lung infiltration and pleural effusion was obtained (Figure 1C). After 1 month of IV therapy, the regimen was replaced by oral linezolid (600 mg, twice a day) as follow-up therapy, and the patient was discharged. He was kept under regular follow-up since then.

He remained asymptomatic except for a gradually aggravated anemia (hemoglobin 79 g/L) during follow-up, which was considered as a drug related adverse event attributed to linezolid. To rule out other reasons for the anemia, linezolid treatment was stopped after five months. At the end of therapy, the lesion had been completely absorbed in the lung CT. He was confirmed to be clinically cured, and anemia recovered after discontinuation of linezolid. There was no evidence of clinical or radiological recurrence. The patient is alive with a well functioning allograft more than 16 months following his transplant.

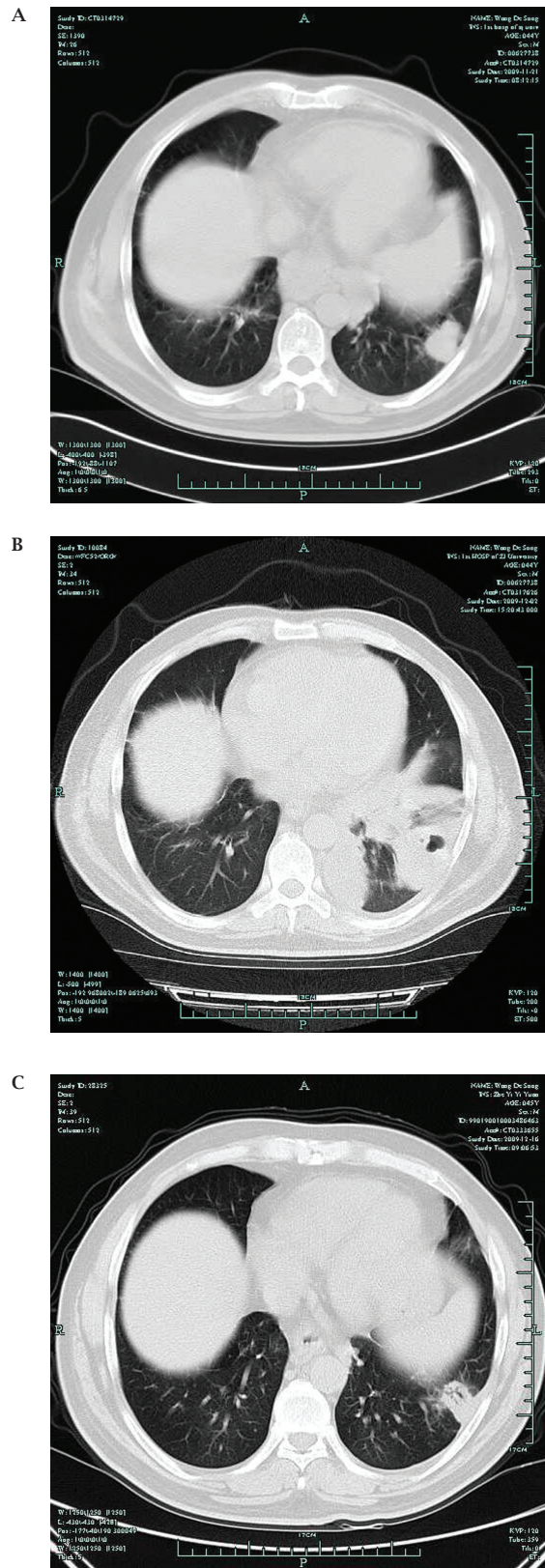


Figure 1: CT demonstrates a 3-cm large nodule in the lower lobe of the left lung, at the time of symptoms onset (A). The lesion became larger with formation of abscess, infiltration and pleural effusion, after therapy of TMP-SMX (B). The lesion was smaller, with absorbed infiltration and pleural effusion after 2 weeks of linezolid treatment (C).

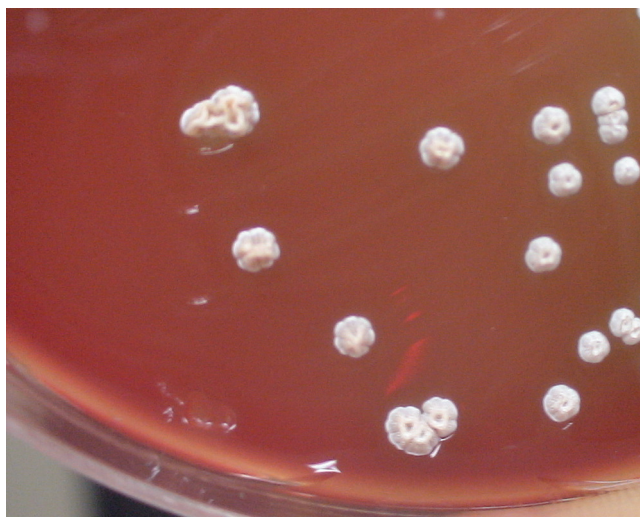


Figure 2: In blood agar, typical colonies showed a chalky white, cotton candy appearance with reductus on the surface, which indicated *Nocardia* spp. growth.

DISCUSSION

Antibiotic therapy for *Nocardia* infection has been difficult for years. Based on the available literature, there are more than 50 species of *Nocardia* identified by phenotypic and molecular methods.¹ The most frequently isolated species include *N. asteroides*, *N. farcinica*, *N. nova* and *N. brasiliensis*. Isolates of *N. farcinica* usually show high resistance to antibiotics and is associated with high mortality.^{1,3}

TMP-SMX has functioned as first-line therapy for more than 60 years.¹ But the mortality rate associated with TMP-SMX monotherapy is as high as 50%, especially in disseminated infection and CNS involvement, mostly due to drug resistance to some species such as *N. farcinica*.⁶ Although amikacin and imipenem show good activity to most part of the isolated species, renal toxicity may be enhanced when simultaneous therapy of cyclosporine or tacrolimus is administered to transplant recipients.³ Research on alternative antibiotics such as cephalosporins and minocycline is scarce.

Linezolid, a novel oxazolidinone antibiotic, has gained more and more attention as primary therapy for *Nocardia* infection in recent years. *In vitro* investigations show consistent sensitivity of all isolates of *Nocardia* species to linezolid, and, *in vivo*, the tissue penetration of linezolid is satisfactory, even in the cerebral spinal fluid.^{7,8} Furthermore, it is suitable for long-term therapy because it can be administered not only intravenously but also orally with 100% bioavailability.⁸ Linezolid has little renal or hepatic toxicity, and rarely has interactions with other drugs such as immunosuppressants, for it is not metabolized by human cytochrome P450.²

Through literature review, we identified 14 additional cases of linezolid monotherapy or combined therapy

for *Nocardia* infection published in English literature, and detailed clinical data about these reports are shown in Table 1.

The earliest report was from 2003. Six of these cases were reported in an original article.⁹ Two of them were associated with liver transplantation.⁵ Most of the strains isolated were *N. farcinica* (6 cases) and *N. asteroides* (6 cases). In more than half of the patients (8 cases) CNS was involved. The duration of linezolid therapy could be as long as 24.5 months.⁹ In most cases linezolid was not initially prescribed. It was only used as salvage therapy when previous therapy failed. Sometimes it was administered in combination with other regimens, such as TMP-SMX, amikacin, meropenem and minocycline. The outcome of linezolid therapy was quite good, with 13 cases confirmed to have reached clinical cure. Drug related adverse events were not rare, especially in prolonged usage for several months. Adverse events attributed to linezolid were observed in 10 cases. The most common severe side-effects were myelosuppression (7 cases), lactic acidosis (2 cases), peripheral neuropathy (3 cases) and optic neuropathy (1 case). Myelosuppression often induced anemia and thrombocytopenia. As a result, drug toxicity was the most significant reason for discontinuation of linezolid treatment, which led to discontinuation of therapy in 8 cases.

In the present case, considering that empiric treatment with TMP-SMX did not show effectiveness and according to the species identification and susceptibility test, we chose linezolid as primary antibiotic regimen. Linezolid showed excellent efficacy with clear improvement of clinical and radiologic manifestations. There was no evidence for interaction with immunosuppressant, but anemia was observed and was confirmed to be linezolid-related, which eventually resulted in treatment discontinuation. Therapy lasted for five months and no recurrence occurred during follow-up. Monotherapy of linezolid may avoid the need to use multiple treatments such as amikacin and imipenem, whose renal toxicity may be enhanced by the use of tacrolimus; they are also unsuitable for long-term therapy as they are not available orally. The good prognosis of this case may be attributed to the early effective therapy of linezolid and no organ involved other than lung.

In conclusion, linezolid shows superior effectiveness to treat *Nocardia* infection in relation to traditional antibiotics such as TMP-SMX. It has significant activity against all species including *N. farcinica* and appears to be a potential reasonable agent to treat *Nocardia* infection. But the safety of prolonged use of linezolid should be a concern and its value as first or second-line therapy, initial or salvage therapy for *Nocardia* infection warrants more clinical data.

ACKNOWLEDGEMENTS

This work was supported by National Basic Research Program of China (973 Program, No.2009CB522403).

Table 1. Published reports of *Nocardia* infection treated with linezolid

Case reports (number of patients)	Involved organs	<i>Nocardia</i> spp.	Linezolid therapy period	Adverse events	Stopped for due to adverse events	Outcome
Moylett et al. ⁹ (6)	Skin (3), CNS (2), lung (4), liver (1), kidney (1), adrenal glands (1),	<i>N. asteroides</i> (3), <i>N. brasiliensis</i> (1), <i>N. otitidiscaviarum</i> (2)	12 m, 3 m, 2 m, 4 m, 24.5 m, 12 m	Myelosuppression (3), lactic acidosis (1), peripheral neuropathy (1)	Yes (2)	Cure (5), suspected recurrence (1)
Lewis et al. ¹⁰ (1)	Lung, skin, kidney, CNS	<i>N. farcinica</i>	4 m	Myelosuppression, visual impairment	Yes	Cure
Moitra et al. ¹¹ (1)	Lung, CNS	<i>N. asteroides</i>	4 m	Peripheral neuropathy	Yes	Cure
Rupprecht et al. ¹² (1)	CNS	<i>N. farcinica</i>	1.6 m	None	No	Cure
Viganò et al. ¹³ (1)	Lung, CNS	<i>N. farcinica</i>	2 m	Anemia	Yes	Cure
Justiniano et al. ¹⁴ (1)	CNS	<i>N. asteroides</i>	NR	None	No	Improvement
Rivero et al. ¹⁵ (1)	Pleura, pericardium	<i>N. farcinica</i>	17 m	Peripheral neuropathy	No	Cure
del Pozo et al. ⁵ (1)	Soft tissue, bone, CNS	<i>N. asteroides</i>	1 m	Lactic acidosis	Yes	Cure
Gowrinath et al. ¹⁶ (1)	Lung	<i>N. farcinica</i>	0.5 m	Myelosuppression	Yes	Cure
This report (1)	Lung	<i>N. farcinica</i>	5 m	Anemia	Yes	Cure

REFERENCES

- Brown-Elliott BA, Brown JM, Conville PS et al. Clinical and laboratory features of the *Nocardia* spp. based on current molecular taxonomy. *Clin Microbiol Rev* 2006; 19:259-82.
- Deem RL, Doughty FA, Beaman BL. Immunologically specific direct T lymphocyte-mediated killing of *Nocardia asteroides*. *J Immunol* 1983; 130:2401-6.
- Clark NM. *Nocardia* in solid organ transplant recipients. *Am J Transplant* 2009; 9(Suppl 4):S70-S7.
- Peleg AY, Husain S, Qureshi ZA et al. Risk factors, clinical characteristics, and outcome of *Nocardia* infection in organ transplant recipients: A matched case-control study. *Clin Infect Dis* 2007; 44:1307-14.
- del Pozo JL, Herrero JI, Manubens A et al. Disseminated *Nocardia asteroides* infection presenting as an atraumatic leg fracture in a liver transplant recipient. *Liver Transpl* 2008; 14:257-8.
- Mandell GL, Bennett JE, Dolin R, eds. *Mandell, Douglas, and Bennett's principles and practice of infectious diseases*. 6th ed. New York: Churchill Livingstone; 2005.
- Noskin GA, Siddiqui F, Stosor V et al. *In vitro* activities of linezolid against important gram-positive bacterial pathogens including vancomycin-resistant enterococci. *Antimicrob Agents Chemother* 1999; 43:2059-62.
- Brown-Elliott BA, Ward SC, Crist CJ et al. *In vitro* activities of linezolid against multiple *Nocardia* species. *Antimicrob Agents Chemother* 2001; 45:1295-7.
- Moylett EH, Pacheco SE, Brown-Elliott BA et al. Clinical experience with linezolid for the treatment of *Nocardia* infection. *Clin Infect Dis* 2003; 36:313-8.
- Lewis KE, Ebden P, Wooster SL et al. Multi-system Infection with *Nocardia farcinica*-therapy with linezolid and minocycline. *J Infect* 2003; 46:199-202.
- Moitra RK, Auckland C, Cawley MI et al. Systemic nocardiosis in a splenectomized patient with systemic lupus erythematosus: successful treatment using linezolid. *J Clin Rheumatol* 2003; 9:47-50.
- Rupprecht TA, Pfister HW. Clinical experience with linezolid for the treatment of central nervous system infections. *Eur J Neurol* 2005; 12:536-42.
- Viganò SM, Edefonti A, Ferrareso M et al. Successful medical treatment of multiple brain abscesses due to *Nocardia farcinica* in a paediatric renal transplant recipient. *Pediatr Nephrol* 2005; 20:1186-8.
- Justiniano M, Glorioso S, Dold S et al. *Nocardia* brain abscesses in a male patient with SLE: successful outcome despite delay in diagnosis. *Clin Rheumatol* 2007; 26:1020-2.
- Rivero A, García-Lázaro M, Pérez-Camacho I et al. Successful long-term treatment with linezolid for disseminated infection with multidrug-resistant *Nocardia farcinica*. *Infection* 2008; 36:389-91.
- Gowrinath K, Baig WW, Prabhu AR et al. Pulmonary nocardiosis due to *Nocardia farcinica* in a renal transplant recipient. *Indian J Chest Dis Allied Sci* 2009; 51:237-9.