



The Brazilian Journal of INFECTIOUS DISEASES

www.elsevier.com/locate/bjid



Case report

Subcutaneous infection by *Graphium basitruncatum* in a heart transplant patient



Analía L. Fernández^{a,b}, Patricia O. Andres^a, Cecilia H. Veciño^b, Claudia B. Nagel^c,
María Teresa Mujica^{b,*}

^a Hospital Universitario Fundación Favaloro, Laboratorio Central Servicio de Microbiología, Buenos Aires, Argentina

^b Universidad de Buenos Aires, Facultad de Medicina, Departamento de Microbiología y Parasitología Médica, Buenos Aires, Argentina

^c Hospital Universitario Fundación Favaloro, División Infectología, Buenos Aires, Argentina

ARTICLE INFO

Article history:

Received 3 May 2017

Accepted 14 August 2017

Available online 18 September 2017

Keywords:

Graphium basitruncatum

Phaeohyphomycosis

Heart transplant

Subcutaneous infection

ABSTRACT

Graphium basitruncatum, a synanamorph of *Pseudoallescheria* has been rarely reported in human infections. We report a case of subcutaneous phaeohyphomycosis caused by this fungus in a heart transplant recipient. We also describe the phenotypic, molecular methods and matrix-assisted laser desorption/ionization time-of-flight mass spectrometry (MALDI-TOF MS) used to achieve isolate identification.

© 2017 Sociedade Brasileira de Infectologia. Published by Elsevier Editora Ltda. This is an open access article under the CC BY-NC-ND license (<http://creativecommons.org/licenses/by-nc-nd/4.0/>).

Introduction

Members of the genus *Pseudallescheria*, producing *Scedosporium* and eventually *Graphium* synanamorphs, are frequently found in subcutaneous and systemic infections.¹ These species are also encountered as persistent colonizers of the respiratory tract in patients with cystic fibrosis. The genus *Graphium sensu lato* has been identified by usually well-developed dark synnemata, producing single-celled conidia in slimy masses at their apices. Monomorphic *Graphium* species have been isolated from soil, plant debris, woody substrate and galleries of bark beetles in conifer wood.² However, a few human cases^{3,4}

and one dog case⁵ of infection with *Graphium* species have been reported previously.

The epidemiology of invasive fungal infections is also changing with many species not previously described as pathogens now contributing to the disease burden.⁶ We describe a case of fungal infection in subcutaneous tissue by *Graphium basitruncatum* in a heart transplant patient. Furthermore, phenotypic and molecular methods used for the identification of fungi are also discussed.

Case report

A 48-year-old white man was admitted at Fundación Favaloro, University Hospital, Buenos Aires in December 2015. He had undergone heart transplantation in 2011 and received tacrolimus (2 mg/12 h) and diltiazem (6 mg/days) as immunosuppressive regimen. Physical examination showed neither

* Corresponding author.

E-mail address: mtmujica@gmail.com (M.T. Mujica).

<http://dx.doi.org/10.1016/j.bjid.2017.08.001>

1413-8670/© 2017 Sociedade Brasileira de Infectologia. Published by Elsevier Editora Ltda. This is an open access article under the CC BY-NC-ND license (<http://creativecommons.org/licenses/by-nc-nd/4.0/>).

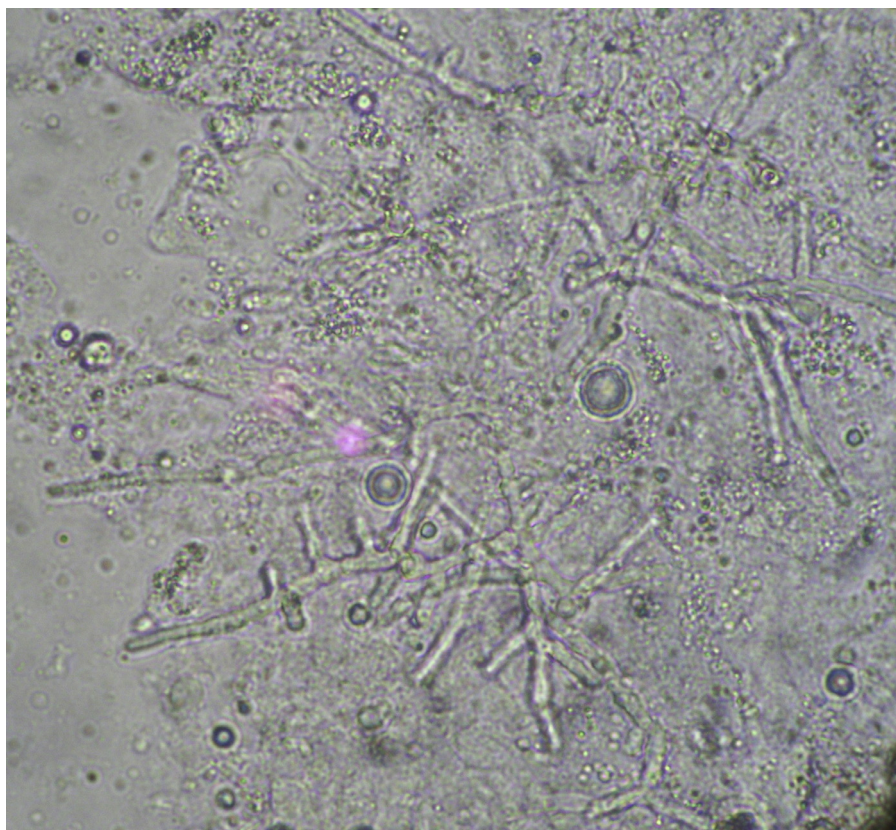

Fig. 1 – K(OH) 40% P/V smear from scrapped lesion in the right palm, illustrating the presence of septate hypha (400×).

fever nor septicemic signs. The patient presented with a lesion in the palm of his right hand which had evolved for six months, involving the cutaneous plane to the fascia without affecting the flexor level. The lesion was a non-tender, erythematous skin nodule with central softening. Computed tomography (CT) scans of thorax, paranasal sinuses and abdomen revealed no lesions. The right hand lesion was punctured and the aspirated material was sent to the laboratory. It was fresh mounted with and without KOH 10%. Neither bacteria nor acid-fast bacteria were observed in Gram and Ziehl-Neelsen staining. The smears showed septate hyphae with slightly uneven widths (2–4 μm), irregular branching and thin walls with focal bulbous dilation (Fig. 1). It was inoculated onto blood agar (BioMerieux[®]), chocolate agar (BioMerieux[®]), and Sabouraud dextrose agar (Britania[®]) and incubated at 28 and 37 °C. Upon dermatomycosis diagnosis, voriconazole was empirically administered with a loading dose of 300 mg twice a day the first day, and subsequently 200 mg every 12 h for 30 days. Surgery was scheduled to be performed at the end of January 2016. The excised material was processed as in the previous sample and demonstrated the same fungal elements observed in Fig. 1. The isolates were subcultured onto an in-house potato dextrose agar medium and incubated at 28 °C for 10 days to assess the macroscopic morphology and microscopic features formed in slide cultures. Colonies were fluffy, relatively flat, and white initially, becoming gray-brown centrally with an invisible margin (Fig. 2). Distinctive microscopic features included hyphae in prominent fascicles (Fig. 3a),

“sausage shaped” or curved (allantoid) hyaline conidia with truncate bases (2.5–5.0 mm long by 1.5–2.5 mm wide) borne from single annellated conidiogenous cells (Fig. 3A and B), larger, brown, oval conidia (4–6.5 mm long and 3–4 mm wide) (Fig. 3A) and prominent synnemata (Fig. 3C). Based upon morphologic features, the isolates were presumptively identified as *Graphium* spp.

As in our case, it is often challenging to identify such rare fungal pathogens by conventional methods. However, definitive identification is possible using DNA sequencing methods.

Molecular identification was undertaken using a PCR (polymerase chain reaction) assay. The ITS region of the rDNA gene was amplified by PCR following the protocol described by White et al.⁷ Subsequently, the amplicon was bidirectionally sequenced. The amplification of the ITS region resulted in a fragment of 536 bp. The nucleotide sequence was compared with those available in the GenBank database using BLASTN [National Center for Biotechnology Information (NCBI) Internet homepage, (<https://blast.ncbi.nlm.nih.gov/Blast.cgi>). Sequences of the ITS region of *Graphium* isolates obtained in this study were submitted to the GenBank database and assigned the following Accession No.: KY552920. The *Graphium* culture has been deposited at the Mycology Center in the University of Buenos Aires, School of Medicine.

Alignment of over 536 bp corresponding to ITS1 (partial sequence), the 5.8S ribosomal gene (complete sequence), and ITS2 (partial sequence) showed 100% similarity by partial sequencing of rDNA gene of *G. basitruncatum* (Accession No.

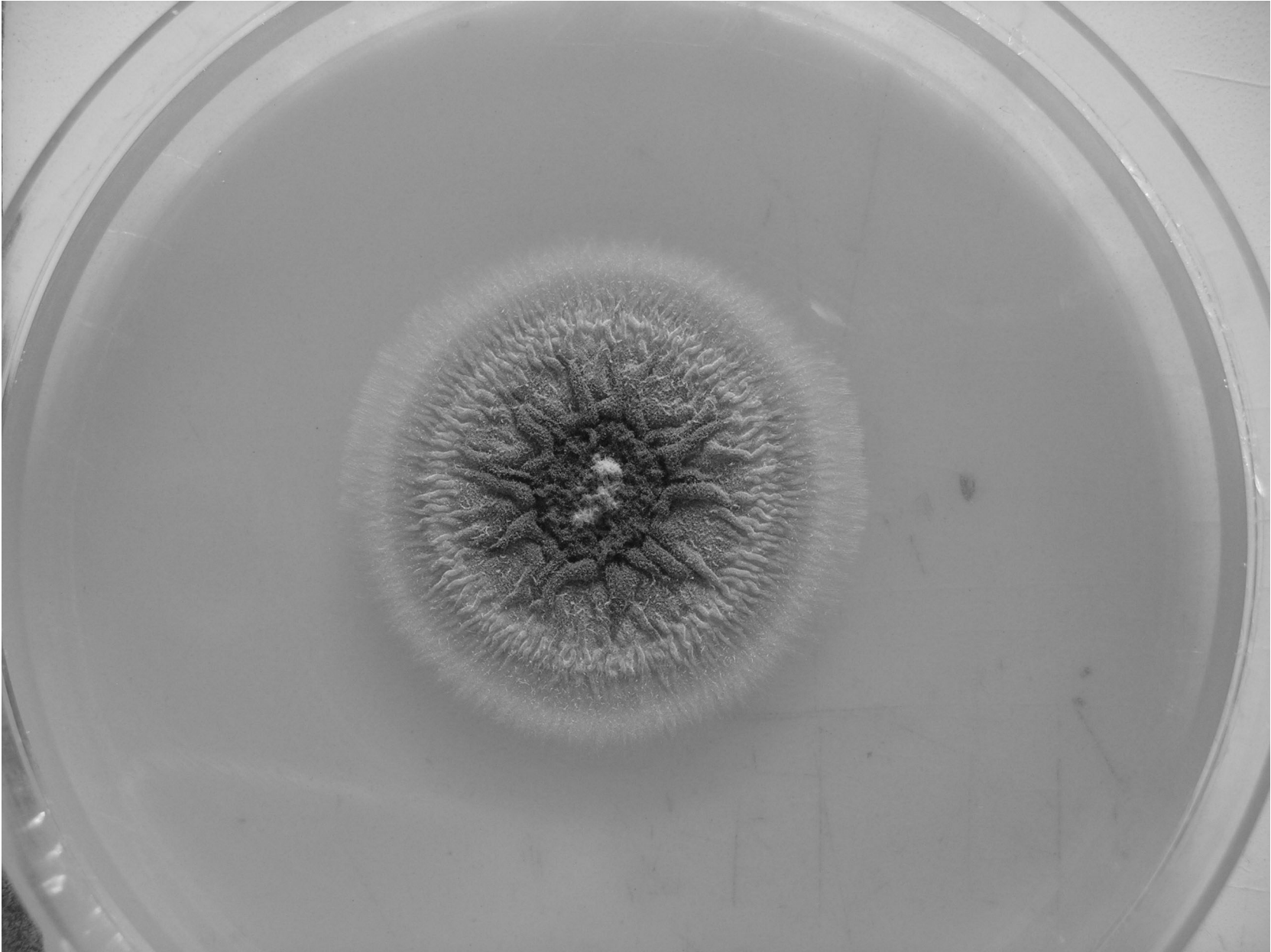


Fig. 2 – *Graphium* spp. colony on potato dextrose agar medium from a 10-day old, 28 °C.

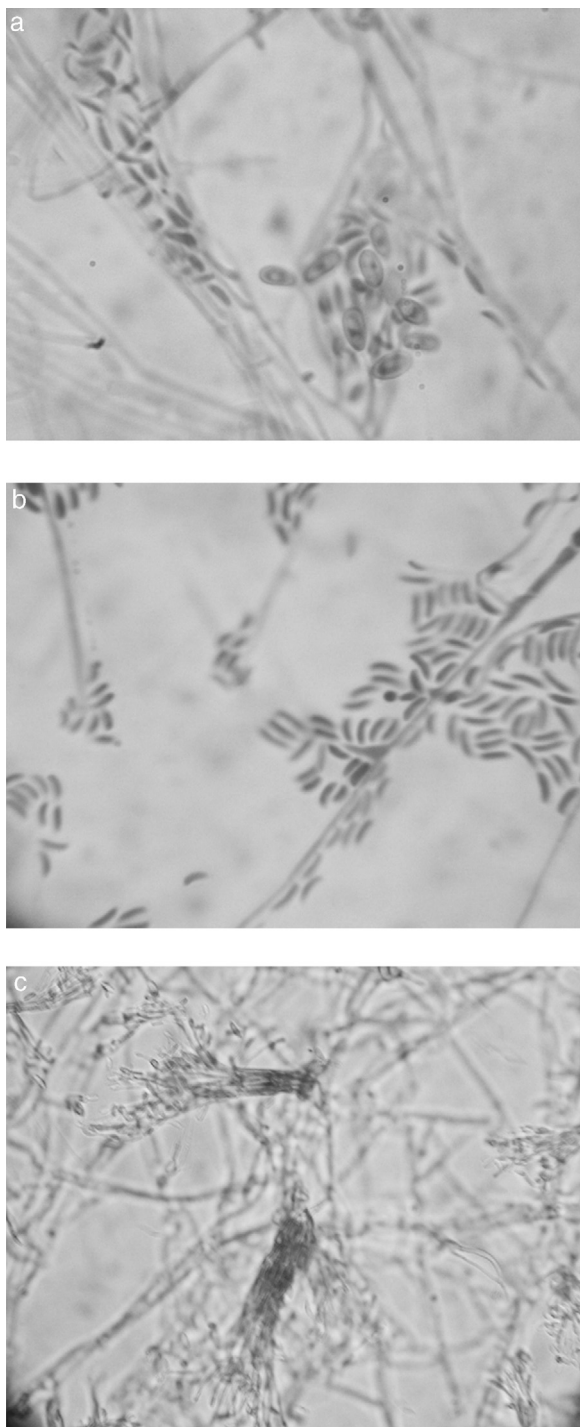


Fig. 3 – Microscopic morphology of *Graphium basitruncatum* from a 10-day old, 28°C potato dextrose agar slide culture demonstrating distinctive microscopic features included hyphae in prominent fascicles, “sausage shaped” or curved (allantoid), hyaline conidia with truncate bases (2.5–5.0 mm long by 1.5–2.5 mm wide) borne from single annellated conidiogenous cells (A and B) (1000×) or similarly in dark, prominent synnemata (C) (200×), and larger, brown, oval conidia (4–6.5 mm long and 3–4 mm wide) (A) (1000×).

KT828733.1) and 99% was obtained with *Graphium penicillioides* (Accession No. KJ780752.1), *Graphium jumulu* (Accession No. NR.137980) and *Graphium carbonarium* (Accession No. KM245114). The query coverage was 99% with an E-value of 0.0 as compared to the sequences above.

The fungal species was also identified by matrix-assisted laser desorption/ionization time-of-flight mass spectrometry (MALDI-TOF MS). The isolate was tested with a simple “short extraction” protocol.^{8,9} The analysis on the MALDI BioTyper system with the BioTyper 3.0 SR software (Bruker Daltonics GmbH, Bremen, Germany) resulted in *G. penicillioides* with score <1.7.

Discussion

In the present report, the fungal infection was localized in the subcutaneous tissue without evidence of other lesions suggesting microbiological investigation. This single finding was in line with his good general condition and the results obtained by CT scans. It is unknown how our patient acquired the infection. He regularly used to prune trees in his birth-place, province of Misiones (Argentina). However, there was no sign of a recent wound by thorn or splinter and he did not remember any injury. The fact that *G. basitruncatum* was isolated twice from samples collected at different times confirmed its role as the etiological agent of this disease.

We must point out that the patient showed neither adherence to treatment nor medical controls. Only once, voriconazole could be dosed, and adequate serum levels were achieved (3885 ng/mL). At surgery, the lesion was completely excised and after a year there was no evidence of disease.

Graphium species belong to the Ascomycota, which are found in soil and plants. Many species included in the genus *Graphium* are known as plant pathogens. The anamorph genus *Graphium* Corda (1837) was originally described by Corda¹⁰ based on a specimen collected in Prague on *Populus nigra* var *italica* (black poplar). Ellis¹¹ listed the fungus as occurring in *Populus* wood in Europe and North America. Sutton and Laut¹² and Sutton¹³ described specimens identified as *G. penicillioides* as a common secondary colonizer of bark beetle tunnels in *Ulmus* trees killed by Dutch elm disease in Manitoba and Saskatchewan, Canada. Recently, *Graphium* was isolated from ambrosia beetle *Megaplatypus mutatus* in our country, a drill of wood that attacks numerous species of native and exotic trees, a plague of poplars in Argentina.¹⁴ However, the biology and distribution of *G. basitruncatum* are poorly known. The fungus has been isolated twice from soil, including its original location in the Solomon Islands, and Japan (JCM 8083). Described originally as *Stilbum basitruncatum* by Matsushima,¹⁵ the species was later regarded as a synonym of *G. penicillioides* by Sutton.¹³

The morphology of the fungus was in line with that of *Graphium* species reported previously.⁶ In addition, DNA sequence analysis of the ITS region identified the fungi as *G. basitruncatum*.¹⁶

Our isolate had an acceptable percent identity, and the query coverage with *G. basitruncatum* (Accession No. KT828733) isolate by Ceriani-Nakamurakare et al.¹⁴ also displayed 99% sequence identity with a strain deposited under

the aggregate name of *G. penicillioides*. However, in 2000, Okada et al. re-evaluated *Graphium*-like anamorphs that had long been considered *G. penicillioides* and determined that by ITS sequencing *G. penicillioides* was a species aggregate consisting of at least four species, one of which is *G. basitruncatum*.¹⁶ It is often difficult to identify such rare fungal pathogens by conventional methods. Hence, definitive identification is possible using DNA sequencing methods. This case report highlights the importance of comparing phenotypic features with molecular results to reach an accurate identification.

Several studies have reported the performance of MALDI-TOF MS for the identification of clinically relevant fungal species. The use of MALDI-TOF MS in diagnostic mycology is limited so far, especially for the identification of molds, mainly due to the poor fungal coverage of the commercial databases and the requirement of extended sample preparation for molds to achieve good-quality mass spectra.¹⁷ The Biotyper software compares each sample mass spectrum to the reference mass spectra in the database, calculates an arbitrary unit score value between 0 and 3 reflecting the similarity between sample and reference spectrum, and displays the top 10 matching database records. Scores of 2.0 were accepted for species assignment, and scores of 1.7 but 2.0 were accepted for identification at the genus level. Scores below 1.7 were considered unreliable.¹⁸ However, mass spectra of dematiaceous molds had fewer peaks, and spectrum quality was often not sufficient to create reference entries, suggesting that sample preparation for these fungi is more difficult. In addition, fungal pigments may have inhibited the acquisition of MALDI TOF mass spectra.¹⁹ As previously specified, the fungal isolated was identified at genus level by MALDI TOF with a cutoff value was between 1.6 and 1.5¹⁸ such as *G. penicillioides*, the only *Graphium* species in the database investigated. In addition, *G. penicillioides* is composed of at least four species, one of which is *G. basitruncatum*.¹⁴

There have been scarce human cases and one dog case of infection with *Graphium* species reported elsewhere.³⁻⁵ Kumar et al.⁴ reported a case of *G. basitruncatum* fungemia in a patient with acute leukemia, the only example of a clinical strain in the clade with monomorphic *Graphium* species showing association with bark beetle communities. El Feghaly et al.³ reported a case of *Graphium basitruncatum* fungemia in a two-year-old child with dyskeratosis congenita who underwent stem cell transplantation two months prior to infection.

G. basitruncatum had not been previously reported as a human pathogen in our country. Thus, this is the first documented case of human infection in Argentina caused by this pathogen.

Conflicts of interest

The authors declare no conflicts of interest.

Acknowledgments

This research was supported by research grants from University of Buenos Aires UBACyT 20020150100158BA. We are grateful to Mr. Santiago Pola for his excellent technical assistance.

REFERENCES

- Guarro J, Kantarcioglu AS, Horr r R, et al. *Scedosporium apiospermum*: changing clinical spectrum of a therapy-refractory opportunist. *Med Mycol.* 2006;44:295-327.
- Jacobs K, Kirisitis T, Wingfield MJ. Taxonomic re-evaluation of three related species of *Graphium*, based on morphology, ecology and phylogeny. *Mycologia.* 2003;95:714-27.
- El Feghaly RE, Sutton DA, Thompson EH, et al. *Graphium basitruncatum* fungemia in an immunosuppressed child post stem-cell transplantation. *Med Mycol Case Rep.* 2012;1:35-8.
- Kumar D, Sigler L, Gibas CFC, et al. *Graphium basitruncatum* fungemia in a patient with acute leukemia. *J Clin Microbiol.* 2007;45:1644-7.
- K ufer I, Weber A. *Graphium fructicola* as a cause for a systemic mycosis in a dog. *Mykosen.* 1977;20:39-46.
- de Hoog GS, Guarro J, Gene J, Figueras MJ. Atlas of clinical fungi. 2nd ed. Utrecht, The Netherlands: Centraalbureau voor Schimmcultures; 2000.
- White TJ, Bruns S, Lee S, Taylor J. Amplification and direct sequencing of fungal ribosomal RNA genes for phylogenetics. In: Innis MA, Gelfand DH, Sninsky JJ, White TJ, editors. PCR protocols: a guide to methods and applications. San Diego: Academic Press; 1990. p. 315-22.
- Theel E, Schmitt B, Hall L, et al. Formic acid-based direct, on-plate testing of yeast and *Corynebacterium* species by Bruker Biotyper matrix-assisted laser desorption ionization-time of flight mass spectrometry. *J Clin Microbiol.* 2012;50:3093-5.
- Relloso MS, Nievas J, Fares Taiea S, et al. Evaluaci n de la espectrometr a de masas: MALDI-TOF MS para la identificaci n r pida y confiable de levaduras. *Rev Argent Microbiol.* 2015;47:103-7.
- Corda AC, Published by Icones fungorum hucusque cognitorum. 1. Prague, Czech Republic: The Author; 1837.
- Ellis MB. Dematiaceous hyphomycetes. Kew, Surrey, UK: Commonwealth Mycological Institute; 1971.
- Sutton BC, Laut JG. *Graphium penicillioides* on American elm in Manitoba and Saskatchewan. *Bi-Month Res Notes Can Forest Servo.* 1970;26:25-6.
- Sutton BC. Hyphomycetes from Manitoba and Saskatchewan. *Mycol Pap.* 1973;132:1-143.
- Ceriani-Nakamurakare E, Slodowicz M, Gonzalez-Audino P, Dolinko A, Carmar n C. Mycobiota associated with the ambrosia beetle *Megaplatypus mutatus*: threat to poplar plantations. *Forestry.* 2016;89:191-200.
- Matsushima T, editor. Microfungi of the Solomon Islands and Papua-New Guinea. Kobe, Japan: Matsushima T; 1971. p. 15-20.
- Okada G, Jacobs K, Kiristis T, et al. Epitypification of *Graphium penicillioides* Corda, with comments on the phylogeny and taxonomy of graphium-like synnematosus fungi. *Stud Mycol.* 2000;45:169-88.
- Bader O. MALDI-TOF-MS-based species identification and typing approaches in medical mycology. *Proteomics.* 2013;13:788-99.
- Schulthess B, Brodner K, Bloemberg GV, Zbinden R, B ttger EC, Hombach M. Identification of Gram-positive cocci by use of matrix-assisted laser desorption-time of flight mass spectrometry: comparison of different preparation methods and implementation of a practical algorithm for routine diagnostics. *J Clin Microbiol.* 2013;51:1834-40.
- Buskirk AD, Hettick JM, Chipinda I, et al. Fungal pigments inhibit the matrix assisted laser desorption/ionization time-of-flight mass spectrometry analysis of darkly pigmented fungi. *Anal Biochem.* 2011;411:122-8.