



Sociedade
Brasileira de
Infectologia

The Brazilian Journal of INFECTIOUS DISEASES

www.elsevier.com/locate/bjid



Case report

Co-infection of SARS-CoV-2 and dengue virus: a clinical challenge



Naira Bicudo ^{a,*}, Eliana Bicudo^a, Julia Duarte Costa^b,
Julliana Alline Leite Porto Castro^a, Gustavo Barcelos Barra ^c

^a HOME Hospital, Department of Infectious Diseases, Brasília, DF, Brazil

^b HOME Hospital, Department of Internal Medicine, Brasília, DF, Brazil

^c Sabin Medicina Diagnóstica, Brasília, DF, Brazil

ARTICLE INFO

Article history:

Received 15 May 2020

Accepted 19 July 2020

Available online 26 August 2020

Keywords:

Dengue

COVID-19

SARS-CoV-2

Co-infection

ABSTRACT

Many regions of the world where dengue epidemics are seasonal are also facing the COVID-19 pandemic. This is a medical concern because both diseases are difficult to distinguish since they have similar clinical symptoms and laboratory findings, and because they have different clinical management. So far, co-infection of SARS-CoV-2 and dengue virus (DENV) has not been studied. Herein we report the first case of a patient with co-infection of COVID-19 and dengue. Both infections were simultaneously laboratory confirmed by positive RT-qPCR for SARS-CoV-2 and RT-qPCR for DENV, NS1, IgM and IgG antibody tests for dengue. The patient had a favorable clinical improvement, without severe symptoms. This case emphasize that, in pandemic era, having a diagnostic of one infection does not rule out the possibility of having another infection concomitantly. In addition, underscores the importance of an accurate and timely diagnosis to prevent the spread of COVID-19.

© 2020 Sociedade Brasileira de Infectologia. Published by Elsevier España, S.L.U. This is an open access article under the CC BY-NC-ND license (<http://creativecommons.org/licenses/by-nc-nd/4.0/>).

Introduction

SARS-CoV-2, the novel coronavirus that causes Coronavirus Disease 2019 (COVID-19), was firstly detected in Brazil on February 25, 2020. Since then, 202,918 cases had been confirmed as of May 14, 2020.¹ In the same period, the country was also facing a dengue virus (DENV) epidemic. According to the Brazilian Ministry of Health, the incidence of dengue cases showed an upward trend, resulting in 676,928 cases until now.²

Brazil's Federal District, located in the Central-West region of the country, has a high incidence of DENV in 2020 so far (841.9 cases/100,000 inhabitants)² and SARS-CoV-2 is co-circulating leading to a unique and distinct health scenario for the population (Fig. 1). Co-infection of SARS-CoV-2 and DENV have not been studied neither described in detail until now. Here, we describe the first case where both viruses infected the same person simultaneously.

Case report

A previously healthy 56-year-old woman, with no travel history, resident in an urban area in Brasília city, Federal District,

* Corresponding author.

E-mail address: nairabicudo@gmail.com (N. Bicudo).

<https://doi.org/10.1016/j.bjid.2020.07.008>

1413-8670/© 2020 Sociedade Brasileira de Infectologia. Published by Elsevier España, S.L.U. This is an open access article under the CC BY-NC-ND license (<http://creativecommons.org/licenses/by-nc-nd/4.0/>).

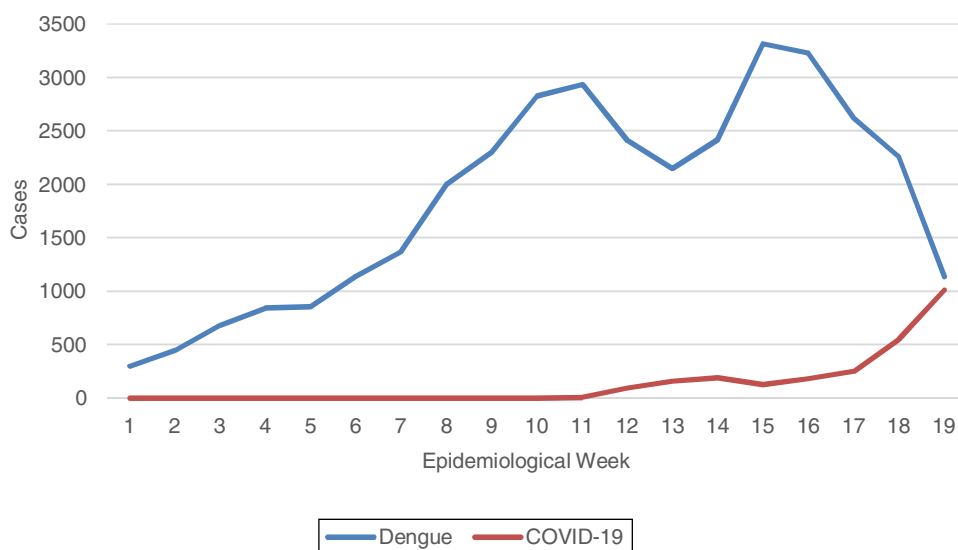


Fig. 1 – Number of dengue and COVID-19 cases per epidemiological week, in Federal District, Brazil, 2020.^{1,3}

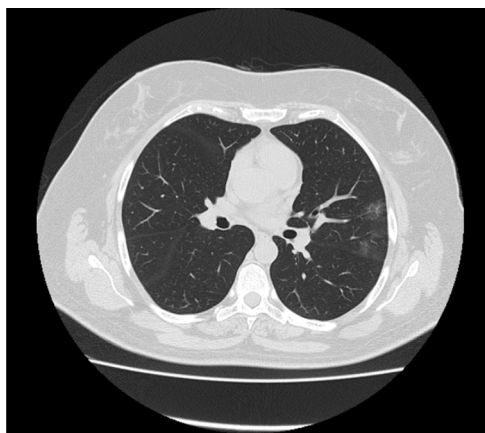

Fig. 2 – Chest computed tomography (CT) image in first day of hospitalization. The image demonstrates two ground glass opacities in peripheral area of left upper lobe. The patient had few bilateral, peripheral ground glass opacities.

Brazil, was admitted to a local hospital on April 14, 2020. The patient complained of sore throat, anosmia and ageusia for the past 12 days, and frontal headache, fever, dry cough, mild dyspnea without need for supplementary oxygen and SpO₂ 94% on room air for five days. IgM and IgG antibody tests for DENV (SERION ELISA classic Dengue Virus IgM and IgG, Serion Inc., Brazil) were initially negative, whereas real-time reverse transcription – polymerase chain reaction (RT-qPCR) for SARS-CoV-2 (in-house laboratory developed test targeting N1 and E genes⁴ performed on a nasopharyngeal specimen) was positive. Blood samples showed leukopenia (2260/mm³), lymphopenia (497/mm³), thrombocytopenia (143,000/mm³), and elevated D-dimer (3986 ng/mL), C-Reactive Protein-CRP (16 mg/L), serum alanine aminotransferase (ALT 60 U/L), aspartate aminotransferase (AST 40 U/L), and ferritin (559 ng/mL). Chest computed tomography (CT) images demonstrated few bilateral, peripheral ground glass opacities (Fig. 2). The patient

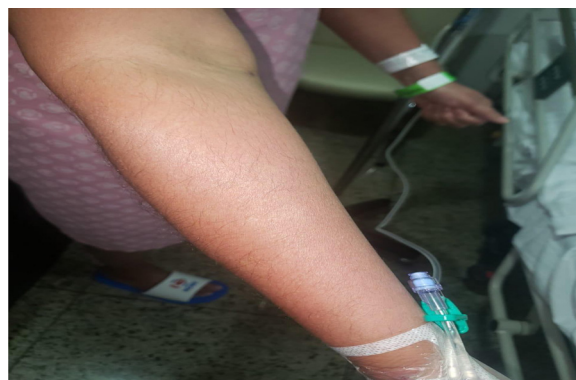

Fig. 3 – Dengue diffuse itchy erythematous-papular rash, mainly located on the limbs and trunk regions, onset on third day of hospitalization.

started therapy with chloroquine, azithromycin and anticoagulation.

Three days after hospitalization, the patient developed a diffuse itchy erythematous-papular rash, mainly located in the limbs and trunk regions (Fig. 3), gastrointestinal symptoms such as diarrhea and nausea, worsening of leukopenia (1820/mm³), new onset of atypical lymphocytes (9%), thrombocytopenia (92.000/mm³) and progressive elevation of aminotransferases (ALT 546 U/L, AST 433 U/L). A new laboratory investigation for dengue and COVID-19 was performed turning out positive for NS1 (SD BioLine Dengue NS1 Ag from Alere Inv., USA), DENV RT-qPCR (in-house laboratory developed test targeting UTR sequence common to all four dengue virus genotype⁵), and IgM and IgG antibody tests for dengue. SARS-CoV-2 RT-qPCR was again positive. Furthermore, dengue virus was confirmed as serotype DENV-1 (CDC DENV 1-4 genotyping protocol⁶). All medications were discontinued and the patient had progressive clinical improvement, without complications, and was discharged on day 6 of hospitalization. Once at home, she stayed isolated until two

consecutive negative tests for SARS-CoV-2 at day 26 of onset of symptoms.

Discussion

This was the first case report of a human co-infection of SARS-CoV-2 and DENV, in which both viruses were detected by RT-qPCR at the same time. We believe that the patient was first infected by SARS-CoV-2, presenting a mild disease, and one week later, during the illness of COVID-19, she was infected by DENV. Despite the co-infection, the patient did not have severe respiratory disease nor severe dengue. Recently, two patients diagnosed with COVID-19 by SARS-CoV-2 RT-PCR had positive serological antibody tests for dengue but negative DENV RT-PCR were described in Singapore, suggesting false-positive serological test results for dengue or cross-reaction.⁷

Dengue and COVID-19 could be difficult to distinguish because they have similar clinical symptoms and laboratory findings, such as fever, headache, myalgia and fatigue, making differential diagnosis challenging.^{8,9} Although infrequent, COVID-19 cases can present skin rash¹⁰ and low platelet count, meaning that one disease can be initially misdiagnosed as the other. Moreover, a positive dengue serology may appear on a false-positive test, also in co-infection with SARS-CoV-2 and DENV. The incorrect or delayed diagnosis can have serious consequences, because each disease has different clinical management, such as venous hydration, use of anticoagulants, corticosteroids, and early mechanical ventilation.¹¹

Conclusion

This report confirms that, in pandemic era, diagnosing one infection does not rule out the possibility of having another infection concomitantly. In addition, it underscores the importance of an accurate and timely diagnosis, with a complete laboratory investigation for both dengue and COVID-19, in territories where there is a possibility of dengue infection, since each infection has different clinical management. Beyond that, we alert for this public health concern, especially highlighting the need in obtaining the correct contact and droplet precautions in health services and communities, helping reducing human-to-human transmission, prevent outbreaks and delay the spread of COVID-19 pandemic.

Conflicts of interest

The authors declare no conflicts of interest.

Acknowledgments

We thank Clara Wandenkolck Silva Aragão for the language help, Ticiane Henriques Santa Rita and Pedro Góes Mesquita for the laboratory contributions.

REFERENCES

1. Brazilian Ministry of Health, Available at: <https://covid.saude.gov.br/>. [Accessed 14 May 2020] PAINEL COVID-19; 2020.
2. Brazilian Ministry of Health, 2020. Boletim Epidemiológico nº19. Monitoramento dos casos de arboviroses urbanas transmitidas pelo *Aedes Aegypti* (dengue, chikungunya e zika), Semanas Epidemiológicas 1 a 18, 2020. Volume 51. Abril 2020. Ministério da Saúde. Available at: <https://portal.arquivos.saude.gov.br/images/pdf/2020/May/08/Boletim-epidemiologico-SVS-19.pdf>. [Accessed 14 May 2020].
3. Brazilian Ministry of Health, Available at: <http://sinan.saude.gov.br/>. [Accessed 14 May 2020] Sistema de Informação de Agravos de Notificação – SINAN; 2020.
4. Barra GB, Santa Rita TH, Mesquita PG, Jácomo RH, Nery LFA. Analytical sensibility and specificity of two RT-qPCR protocols for SARS-CoV-2 detection performed in an automated workflow. *MedRxiv*. 2020.
5. Drosten C, Götting S, Schilling S, et al. Rapid detection and quantification of RNA of Ebola and Marburg viruses, Lassa virus, Crimean-Congo hemorrhagic fever virus, Rift Valley fever virus, dengue virus, and yellow fever virus by Real-Time Reverse Transcription-PCR. *J Clin Microbiol*. 2002;40:2323–30, <http://dx.doi.org/10.1128/jcm.40.7.2323-2330.2002>.
6. Santiago GA, Vergne E, Quiles Y, Cosme J, Vazquez J, Medina JF, et al. Analytical and clinical performance of the CDC real time RT-PCR assay for detection and typing of dengue virus. *PLoS Negl Trop Dis*. 2013;7:e2311.
7. Yan G, Lee CK, Lam LT, Yan B, Chua YX, Lim AY, et al. Covert COVID-19 and false-positive dengue serology in Singapore. *Lancet Infect Dis*. 2020:10–016.
8. World Health Organization. Report of the WHO-China Joint Mission on Coronavirus Disease 2019 (COVID-19). 16-24 February 2020. Available at: <https://www.who.int/docs/default-source/coronaviruse/who-china-joint-mission-on-covid-19-final-report.pdf>. [Accessed 6 May 2020].
9. Simmons CP, Farrar JJ, VinChau N, Bridget W. Dengue. *N Engl J Med*. 2012;366:1423–32.
10. Joob B, Wiwanitkit V. Covid-19 can present with a rash and be mistaken for dengue. *J Am Acad Dermatol*. 2020;82:e177.
11. World Health Organization. Clinical management of severe acute respiratory infection (SARI) when COVID-19 disease is suspected: Interim guidance. 13 March 2020. (WHO/2019-nCoV/clinical/2020.4).