



# The Brazilian Journal of INFECTIOUS DISEASES

[www.elsevier.com/locate/bjid](http://www.elsevier.com/locate/bjid)



## Clinical image

# Intraventricular mass in a patient with AIDS

Alexandra Sousa\*, Vítor Araújo, Maria Júlia Maciel

Cardiology Department, Centro Hospitalar São João, Porto, Portugal

### ARTICLE INFO

#### Article history:

Received 16 June 2012

Accepted 10 July 2012

Available online 10 January 2013

Cardiovascular involvement associated with human immunodeficiency virus (HIV) includes cardiomyopathy, coronary artery disease, pericardial effusion, pulmonary hypertension and the adverse effects of highly active antiretroviral therapy (HAART).<sup>1,2</sup> HIV-related cardiomyopathy may appear as myocarditis, dilated cardiomyopathy, or isolated left or right ventricular dysfunction.<sup>1,2</sup> Although initially somewhat prevalent, the incidence of HIV-related cardiomyopathy has been clearly declining since introduction of HAART.<sup>1,3</sup>

We present a 41-year-old man admitted in the Intensive Care Unit, because of severe pneumonia and respiratory insufficiency. He was diagnosed with AIDS 10 years ago and was under HAART (zidovudine, lamivudine, efavirenz) for eight years. He had no opportunistic infections, and at the time of admission, he presented a CD4 cell count of 490, and non-detectable viral load. He had no previous known cardiovascular diseases or symptoms. In face of progressive hemodynamic instability, an echocardiogram was performed, demonstrating a manifestly dilated left ventricle (71 mm), with severe systolic dysfunction (only basal segments of

infero-lateral and antero-lateral walls showed some contractility with a left ventricular ejection fraction of 10%), moderate biatrial and mild right ventricular dilatation (Supplementary Material, *Videos S1 and S2*). A heterogeneous intraventricular mass (31 mm × 35 mm) was visualized in left ventricular apex (*Fig. 1A and B; Videos S3 and S4*). Doppler revealed moderate to severe mitral regurgitation and severe tricuspid regurgitation (systolic pulmonary artery pressure 50 mmHg). These findings were consistent with HIV-related dilated cardiomyopathy with an apical thrombus. Anticoagulation with low molecular weight heparin and heart failure directed therapy were initiated. Despite prompt intervention, the patient experienced refractory cardiogenic and septic shock, and died the day after the admission.

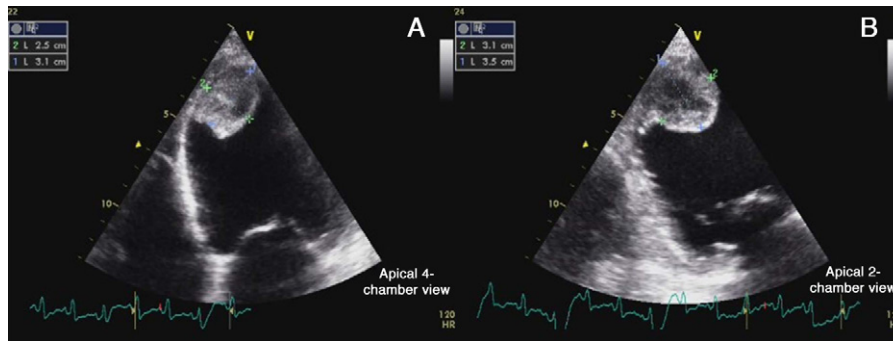
This case emphasizes the possibility of significant silent cardiac involvement, associated with HIV infection, even in the era of HAART. In addition, the diagnosis of HIV-related cardiomyopathy should be considered in AIDS patients with unexplained hemodynamic compromise, even in the absence of previous cardiovascular history or symptoms.

\* Corresponding author at: Alameda Professor Hernâni Monteiro 4200-319, Serviço de Cardiologia, Porto, Portugal. Tel.: +351 933324462; fax: +351 225025766.

E-mail addresses: [xanasousa81@gmail.com](mailto:xanasousa81@gmail.com) (A. Sousa), [vitoraraujo08@gmail.com](mailto:vitoraraujo08@gmail.com) (V. Araújo), [julia.maciел@hsjoao.min-saude.pt](mailto:julia.maciел@hsjoao.min-saude.pt) (M.J. Maciel).

1413-8670/\$ – see front matter © 2013 Elsevier Editora Ltda. All rights reserved.

<http://dx.doi.org/10.1016/j.bjid.2012.07.021>



**Fig. 1 – (A) Apical thrombus in a dilated left ventricle (apical 4-chambers view). (B) Apical thrombus in a dilated left ventricle (apical 2-chambers view).**

---

### Conflict of interest

The authors have no conflicts of interest to declare.

---

### Appendix A. Supplementary data

Supplementary data associated with this article can be found, in the online version, at doi:10.1016/j.bjid.2012.07.021.

---

### REFERENCES

1. Barbaro G, Silva E. Cardiovascular complications in the acquired immunodeficiency syndrome. *Rev Assoc Med Bras.* 2009;55:621-30.
2. Patanè S, Marte F, Sturiale M, et al. Myocarditis and cardiomyopathy HIV associated. *Int J Cardiol.* 2011;146:e56-7.
3. Barbaro G. Heart and HAART: two sides of the coin for HIV-associated cardiology issues. *World J Cardiol.* 2010;2:53-7.