



The Brazilian Journal of INFECTIOUS DISEASES

www.elsevier.com/locate/bjid



Clinical image

AIDS and disseminated tuberculosis after Immune Reconstitution Inflammatory Syndrome



Gonul Sengoz^a, Ahmet Sengoz^b, Filiz Pehlivanoglu^{a,*}

^a Infectious Diseases and Clinical Microbiology, Haseki Training and Research Hospital, Istanbul, Turkey

^b Neurosurgery Clinic, Yenibosna Safa Hospital, Istanbul, Turkey

ARTICLE INFO

Article history:

Received 14 January 2014

Accepted 21 January 2014

Available online 22 March 2014

A 29-year-old male patient was admitted at the hospital with complaints of diarrhea and weight loss that had started two months ago. In his physical examination and laboratory tests, HIV positivity was detected (CD4 cell count 175 mL^{-1} , HIV RNA 9,800,000 copies/mL). At the end of the first month of antiretroviral therapy he was admitted to the hospital again with deterioration in his general medical condition, respiratory distress and loss of consciousness. Massive pleural effusion in the right hemithorax, and diffuse bilateral micronodular infiltration in both lungs were detected by thoracic computerized tomographic (CT) examination (Fig. 1). A lesion (tuberculoma) was observed in the cranial magnetic resonance imaging (MRI) (Fig. 2). There were hypodense nodular lesions in the liver and spleen, and mesenchymal multiple lymphadenopathy (LAP) in the abdominal CT (Fig. 3). *Mycobacterium tuberculosis* grew on the 35th day after pleural fluid culture in Löwenstein Jensen culture media. Treatment with antituberculosis agents and 60 mg prednisolone was started. Bilateral distal motor and sensory neuropathy developed during follow-up. Multiple nodular lesions (tuberculomas) were detected in the spine in spinal MRI (Fig. 4).¹ The patient was discharged on the second month of treatment with partial recovery.

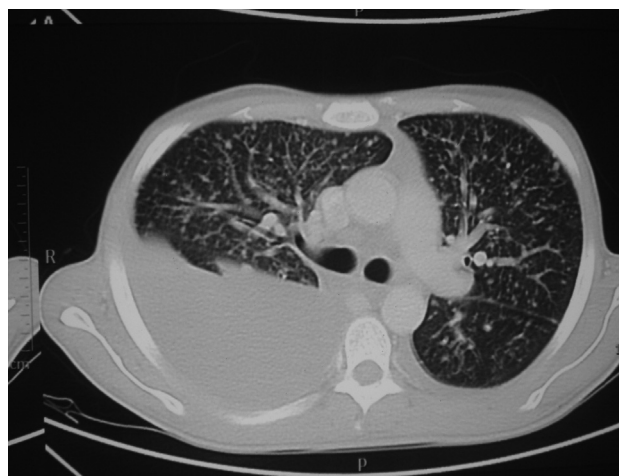

Fig. 1 – Massive pleural effusion in the right hemithorax, diffuse bilateral micronodular infiltration in both lungs, and hilar lymphadenopathy in thoracic CT.

* Corresponding author at: Enfeksiyon Hastalıkları ve Klinik Mikrobiyoloji Kliniği, Haseki Eğitim ve Araştırma Hastanesi, Adnan Adıvar Cad. Fatih, İstanbul, Turkey.

E-mail addresses: drfiliz@gmail.com, drfilizyildirim@yahoo.com (F. Pehlivanoglu).

1413-8670/\$ – see front matter © 2014 Elsevier Editora Ltda. All rights reserved.

<http://dx.doi.org/10.1016/j.bjid.2014.01.004>

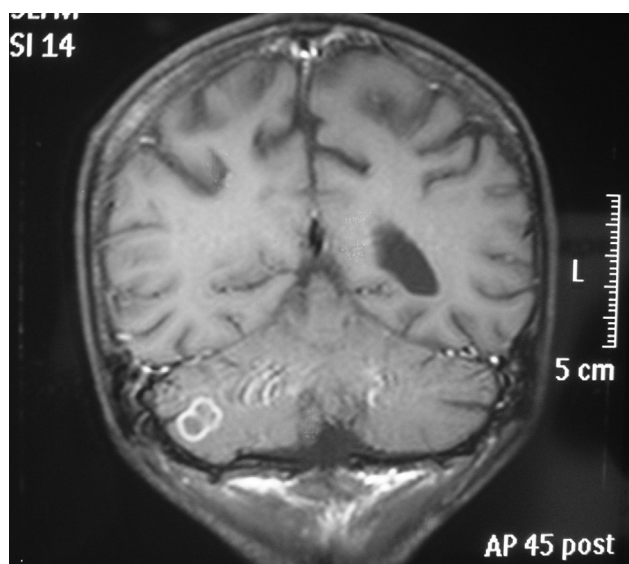


Fig. 2 – Lesion on the right cerebellar hemisphere of approximately 1 cm, which was hypointense in T1 and hyperintense in T2 weighted images in cranial MRI.

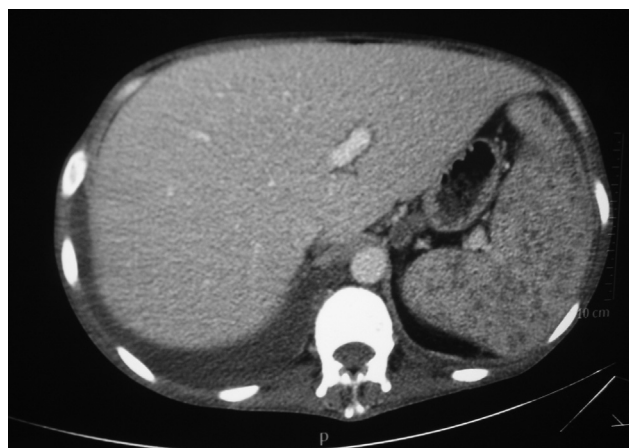

Fig. 3 – Hypodense nodular lesions in the liver and spleen, and mesenchymal multiple lymphadenopathy in the abdominal CT.

Initiation of antiretroviral therapy (ART) in HIV-infected patients leads to restoration of the immune functions. On the other hand, dysregulated immune response after initiation of ART leads to the phenomenon of Immune Reconstitution

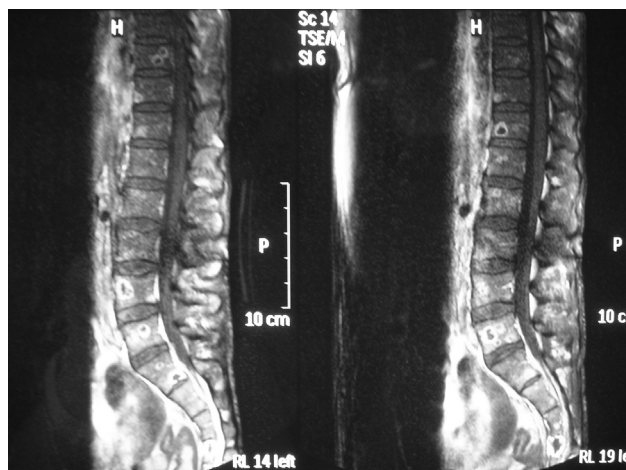

Fig. 4 – Multiple nodular lesions (tuberculomas) in the vertebral corpus in spinal MRI.

Inflammatory Syndrome (IRIS). IRIS is paradoxical worsening of an existing infection or appearance of a new infection soon after initiation of ART.^{2,3}

Conflicts of interest

The authors declare no conflicts of interest.

REFERENCES

1. Viskovic K, Begovac J. Tuberculosis-Associated Immune Reconstitution Inflammatory Syndrome (TB-IRIS) in HIV-infected patients: report of two cases and the literature overview. *Case Rep Infect Dis.* 2013;2013, 7 pp. [Article ID 323208].
2. Bonnet M, Baudin E, Jani IV, et al. Incidence of paradoxical tuberculosis-associated immune reconstitution inflammatory syndrome and impact on patient outcome. *PLoS ONE.* 2013;8:e84585, <http://dx.doi.org/10.1371/journal.pone.0084585>.
3. Breton G, Bourgarit A, Pavy S, et al. Treatment for tuberculosis-associated immune reconstitution inflammatory syndrome in 34 HIV-infected patients. *Int J Tuberc Lung Dis.* 2012;16:1365–70.