



# The Brazilian Journal of INFECTIOUS DISEASES

[www.elsevier.com/locate/bjid](http://www.elsevier.com/locate/bjid)



## Case report

# Histoplasmosis diagnosed after arthroscopy of the knee: case report



Lorenzo Falster, Maurício B. Marin, João Luiz Ellera Gomes\*

Hospital Moinhos de Vento, Porto Alegre, RS, Brazil

### ARTICLE INFO

#### Article history:

Received 17 March 2015

Accepted 15 May 2015

Available online 25 June 2015

#### Keywords:

Histoplasmosis

Knee

Arthritis

Fungal

### ABSTRACT

Fungal arthritis is a rare complication of arthroscopic surgeries, but its possibility should always be considered due its deleterious effects on any joint. Infection caused by the fungus *Histoplasma capsulatum* is the most common cause of respiratory tract infections by fungi, meanwhile histoplasmosis arthritis is more rare than all other fungal infections. However, their atypical forms of arthritis and the importance of early diagnosis and treatment cannot be over-emphasized. Herein we report a case of knee monoarthritis in an immunocompetent patient with histoplasmosis arthritis following an arthroscopic meniscetomy, diagnosed by synovial biopsy and culture performed during a second arthroscopic procedure. The joint was debrided in this second intervention and the patient received itraconazole initially and fluconazole latter on. The arthritis subsided after 10 months of treatment.

© 2015 Elsevier Editora Ltda. All rights reserved.

## Introduction

The most common fungal respiratory tract infection is caused by *Histoplasma capsulatum*. This infection rarely causes arthritis, especially in immunocompetent patients. Although a rare condition, it must be considered in those cases of arthritis that are unresponsive to usual therapies. For this reason, we are reporting a case of knee monoarthritis in an immunocompetent patient caused by *H. capsulatum* following an arthroscopic meniscetomy. The subsequent diagnostic procedure, monitoring, and treatment offered to this patient are herein presented.

## Case report

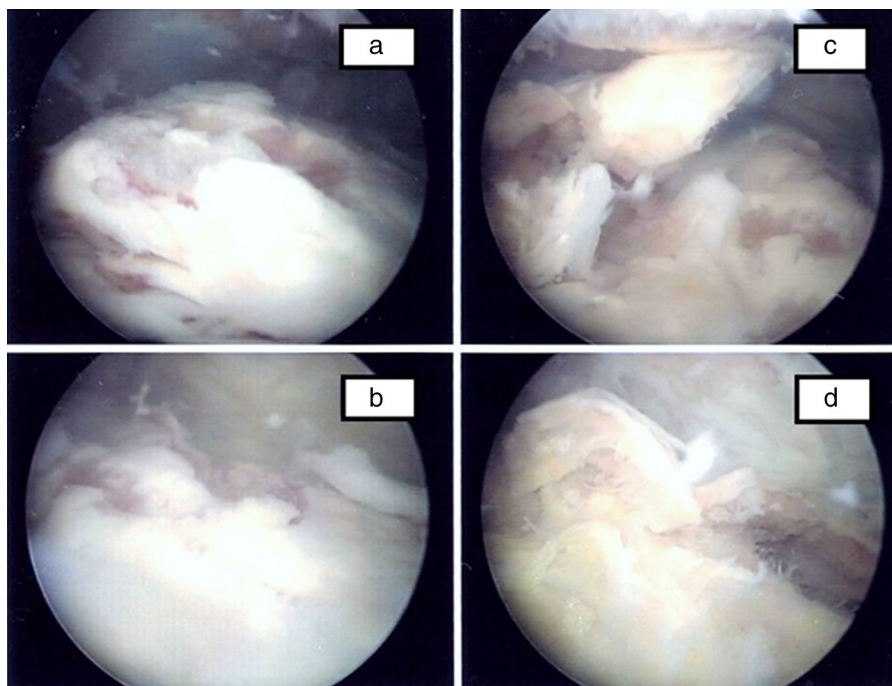
L. F., 67, female, white, residing in Porto Alegre, immunocompetent, with a history of chronic pain and swelling in his right knee, after knee arthroscopy in August 2009, in another hospital. She came to our institution in December 2010 with swelling, heat and pain in the knee, after being treated with physical therapy and nonsteroidal anti-inflammatory drugs (NSAIDs) without improvement during the previous months. A second right knee arthroscopy was then indicated in March 2011, which showed a fungal plate covering the synovial membrane, especially in the suprapatellar

\* Corresponding author at: Rua Des. Moreno Loureiro Lima, 195/901, 90450-130, Porto Alegre, RS, Brazil.

E-mail address: [joelgo.voy@terra.com.br](mailto:joelgo.voy@terra.com.br) (J.L.E. Gomes).

<http://dx.doi.org/10.1016/j.bjid.2015.05.003>

1413-8670/© 2015 Elsevier Editora Ltda. All rights reserved.



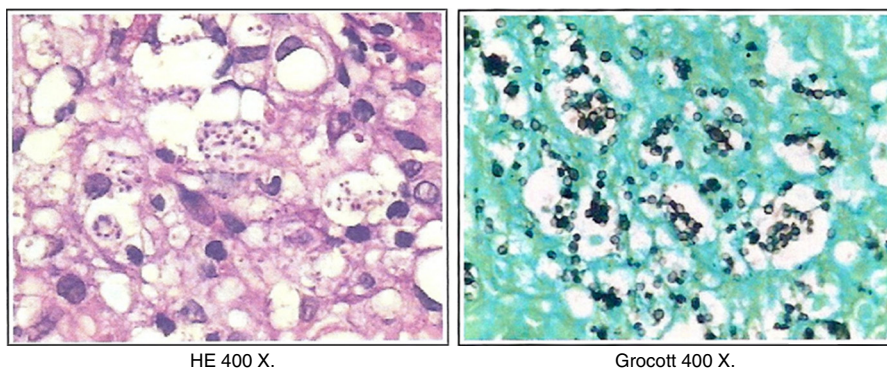
**Fig. 1 – (a and b) Fungal plate covering suprapatellar synovial membrane; (c and d) Normal synovial membrane zone plate covered with fungi.**

area (Fig. 1). The lesion was biopsied and sent for culture and histology. Results showed chronic granulomatous synovitis with extensive necrosis and presence of numerous fungal structures compatible with *H. capsulatum*; search for AFB was negative (Fig. 2). Antifungal treatment was initiated and serological control was monthly performed. Due to past clinical problems, the use of amphotericin was not recommended and thus the patient was treated with oral itraconazole until July 2011. After the second arthroscopy showing evidence of persistent fungal plate, the antifungal therapy was switched to fluconazole from October through December 2011, when itraconazole was restarted. In December another knee biopsy was performed that yielded a negative culture for fungal infection.

## Discussion

Histoplasmosis is an infection caused by the fungus *H. capsulatum*, the most common cause of fungal respiratory tract infections.<sup>1</sup> Among the fungal joint infections, those caused by *H. capsulatum* ranks 10th in order of frequency.<sup>2</sup> It may present as an asymptomatic infection, but can also be part of a disseminated disease.

Classic histoplasmosis is a self-limited febrile illness with pulmonary symptoms. Acute pulmonary histoplasmosis occurs in previously healthy subjects, whereas chronic pulmonary histoplasmosis manifests itself in the presence of emphysematous air spaces and disseminated disease and usually occurs in patients with altered cellular immunity.<sup>2,3</sup>



**Fig. 2 – Presence of numerous fungal structures compatible with *Histoplasma capsulatum*.**

*H. capsulatum* rarely invades bone or synovial membranes.<sup>2</sup> There are some cases in the literature of *Histoplasma* infection with joint involvement, and the first case of joint involvement was reported in 1942 in a patient with knee arthritis.<sup>4</sup> In the herein described case, it was not possible to confirm if the arthritis was in deed caused by contaminated skin or instruments in the first arthroscopic procedure. It might as well have been the result of temporary immune compromise caused by the surgical procedure in an already infected but asymptomatic individual.

The synovial fluid culture is the gold standard of diagnosis and may show positivity in up to 92%, but this fungus takes approximately six weeks to grow *in vitro*.<sup>1</sup> Histopathological examination of the synovial membrane detect *H. capsulatum* mainly in PAS and Grocott staining. Inflammatory tests such as ESR and CRP may also help in the diagnosis. The leucocyte count may show leukocytosis and radiographs may show osteolysis. DNA tests are highly specific and can assist in the identification of the fungus in more expedite way. The diagnosis can also be made by serology, biopsy, enzyme immunoassay test and intradermal reaction to histoplasmin.<sup>1</sup>

Generally, there is no need to treat acute infections. However, the chronic forms must be treated. The drugs of choice are amphotericin B (conventional or lipid formulation) and itraconazole.<sup>1</sup>

To date, this is the only report to show intra-articular images of colonies of *Histoplasma* spp.

---

## Funding

The authors have no financial disclosures relevant to this article.

---

## Conflicts of interest

The authors declare no conflicts of interest.

---

## Informed consent

Informed consent was obtained from all individual participants included in the study.

---

## REFERENCES

1. Vaz JL, Gola TF, Macedo FR, Lima MB. Histoplasmoze com manifestações articulares – relato de caso. *Cad Bras Med.* 2008;XXI:1–81.
2. Jones PG, Rolston K, Hopfer RL. Septic arthritis due to *Histoplasma capsulatum* in a leukaemic patient. *Ann Rheum Dis.* 1985;44:128–9.
3. Unis G, Oliveira FM, Severo LC. Histoplasmoze disseminada no Rio Grande do Sul. *Rev Soc Bras Med Trop.* 2004;37:463–8.
4. Key JA, Large AM. Histoplasmosis of the knee. *J Bone Joint Surg Am.* 1942;24:281–90.