



The Brazilian Journal of INFECTIOUS DISEASES

www.elsevier.com/locate/bjid



Clinical image

Scrotal swelling in a farmworker with paracoccidioidomycosis



Daniella Braz Parente, Guilherme Felix Louza, Leonardo Hoehl Carneiro, Gláucia Zanetti, Edson Marchiori*

Departamento de Radiologia. Universidade Federal do Rio de Janeiro, Rua Prof. Rodolfo Paulo Rocco, n° 255 – Cidade Universitária – Ilha do Fundão – CEP: 219.419-13. Rio de Janeiro, RJ Brazil

ARTICLE INFO

Article history:

Received 3 January 2018

Accepted 25 February 2018

Available online 16 March 2018

A 42-year-old black male, Brazilian farmworker presented with pain and progressive swelling of the scrotum for three years. He also had lower-limb edema, enlarged lymph nodes of the right groin, neck, and sternal furcula. A cervical lymph-node biopsy showed non-specific chronic inflammation. Serologies, including HIV, were negative. The nodule in the right groin increased in volume and gave rise to fistulization and purulent discharge. A chest X-ray was normal. Physical examination revealed a very enlarged scrotum with thickening of the skin and purulent discharge (Fig. 1). Computed tomography (Fig. 2A) and pelvic magnetic resonance imaging (Fig. 2B) showed a very enlarged scrotum with extensive subcutaneous thickening, and inguinal lymphadenopathy with multiple fistulous tracts in the skin. The left testicle had a reduced size, without testicular expansive lesions, and there was also bilateral hydrocele. Lymphoscintigraphy revealed an obstructive process in the inguinal region suggesting lymphatic involvement. The biopsy specimen of the right inguinal skin showed the “ship’s wheel” appearance of yeast forms budding from the central parent yeast on silver stain, consistent with paracoccidioidomycosis (PCM) (Fig. 3). Serology for *Paracoccidioides*

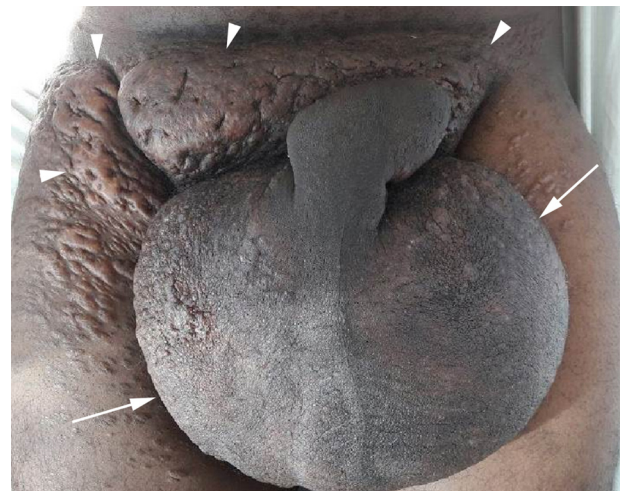

Fig. 1 – Enlarged scrotum (arrows) and diffuse skin thickening (arrowheads).

brasiliensis, based on double radial immunodiffusion test, was reagent (1:64). The patient was treated for 21 days with liposomal amphotericin B, followed by one-year treatment with

* Corresponding author.

E-mail address: edmarchiori@gmail.com (E. Marchiori).

<https://doi.org/10.1016/j.bjid.2018.02.007>

1413-8670/© 2018 Sociedade Brasileira de Infectologia. Published by Elsevier Editora Ltda. This is an open access article under the CC BY-NC-ND license (<http://creativecommons.org/licenses/by-nc-nd/4.0/>).

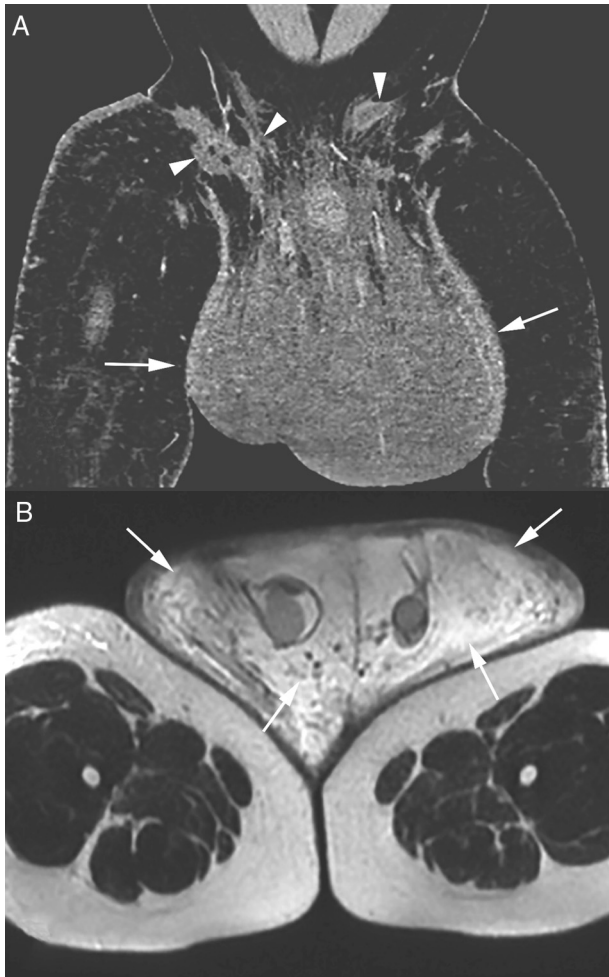


Fig. 2 – Post-contrast coronal computed tomography of the pelvis (A) showing isodense scrotal enlargement (arrows) with multiple fistulous tracts (arrowheads) in the right inguinal region. T2-weighted magnetic resonance image of the pelvis (B) showing hyperintense scrotal enlargement due to significant subcutaneous edema (arrows).

oral trimethoprim/sulfamethoxazole (TMP/SMX). The patient remains on treatment. Later, a scrotoplasty was also performed.

Clinical features of involvement of the genital tract in PCM are very rare and occur in the disseminated chronic form. Urogenital involvement is thought to result from hematogenic dissemination, usually described in late-stage disease and associated with lesions in other organs, along with pulmonary PCM.¹⁻⁴ The main affected sites are the epididymis, prostate, testicle, penis, and scrotal pouch. Testicular, epididymal, and prostatic lesions are usually misdiagnosed as neoplasms. Lesions on the external genitalia appear as ulcers or vegetations, and sexually transmitted diseases are important

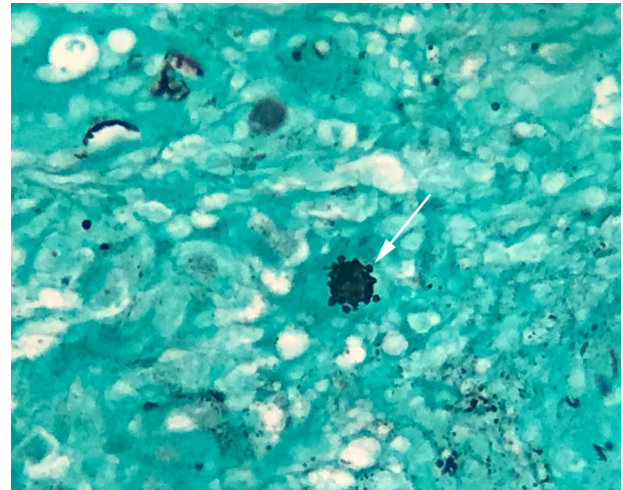


Fig. 3 – Histopathology of the right inguinal cutaneous biopsy: silver stain reveals yeast forms budding from the central parent yeast (“ship’s wheel” appearance; arrow).

components of the differential diagnosis.^{2,3} In conclusion, in endemic areas, the differential diagnosis of a systemic disease with lymphadenopathy and scrotal involvement should include PCM.

Funding

None declared.

Conflicts of interest

The authors declare no conflicts of interest.

REFERENCES

1. Tomimori-Yamashita J, Tagliolatto S, Porro AM, Ogawa MM, Michalany NS, Camargo ZP. Paracoccidioidomycosis: an uncommon localization in the scrotum. *Mycoses*. 1997;40:415-8.
2. Marques SA, Tangoda LK, Camargo RM, Stolf HO, Marques ME. Paracoccidioidomycosis of external genitalia: report of six new cases and review of the literature. *An Bras Dermatol*. 2012;87:235-40.
3. Severo LC, Kauer CL, Oliveira FD, Rigatti RA, Hartmann AA, Londero AT. Paracoccidioidomycosis of the male genital tract. Report of eleven cases and a review of Brazilian literature. *Rev Inst Med Trop Sao Paulo*. 2000;42:38-40.
4. Shikanai-Yasuda MA, Mendes RP, Colombo AL, et al. Brazilian guidelines for the clinical management of paracoccidioidomycosis. *Rev Soc Bras Med Trop*. 2017;50:715-40.