



# The Brazilian Journal of INFECTIOUS DISEASES

[www.elsevier.com/locate/bjid](http://www.elsevier.com/locate/bjid)



## Case report

# Leprosy case series in the emergency room: A warning sign for a challenging diagnosis

Fred Bernardes-Filho, MD, PhD <sup>a,b,c</sup>, Filipe Rocha Lima, Msc <sup>a,c</sup>,  
Glauber Voltan, MD <sup>a,c</sup>, Natália Aparecida de Paula, PhD <sup>a,c</sup>,  
Marco Andrey Cipriani Frade, MD, PhD <sup>a,c,\*</sup>

<sup>a</sup> Dermatology Division, Department of Medical Clinics, Ribeirão Preto Medical School, University of São Paulo, Ribeirão Preto, SP, Brazil

<sup>b</sup> Emergency Department, Hospital Imaculada Conceição da Sociedade Portuguesa de Beneficência, Ribeirão Preto, SP, Brazil

<sup>c</sup> Center of National Reference in Sanitary Dermatology focusing on Leprosy of Ribeirão Preto Clinical Hospital, Ribeirão Preto, SP, Brazil

## ARTICLE INFO

### Article history:

Received 23 June 2021

Accepted 20 September 2021

Available online 12 October 2021

### Keywords:

Leprosy

Emergency medicine

Peripheral nerves

Neuritis

## ABSTRACT

Leprosy can be considered a dissimulated disease, mainly when presented as atypical cases leading to mistaken diagnosis at the emergency setting. Herein we report six patients referred to the emergency room with hypotheses of acute myocardial infarction and arterial and venous thrombosis, although with chronic neurological symptoms; the seventh patient was referred with a wrong suspicion of infected skin ulcer. Positive findings included hypo-anesthetic skin lesions and thickened nerves; 100% were negative for IgM anti-phenolic glycolipid-I, while 71.4%, 100% and 42.8% were positive for IgA, IgM and IgG Mce1A. RLEP-PCR was positive in all patients. Ultrasound of peripheral nerves showed asymmetric and focal multiple mononeuropathy for all patients. Unfortunately, in many patients leprosy is often misdiagnosed as other medical conditions for long periods thus delaying initiation of specific treatment. This paper is intended to increase physicians' awareness to recognize leprosy cases presented as both classical and unusual forms, including in emergency department.

© 2021 Sociedade Brasileira de Infectologia. Published by Elsevier España, S.L.U. This is an open access article under the CC BY-NC-ND license (<http://creativecommons.org/licenses/by-nc-nd/4.0/>)

## Introduction

Leprosy diagnosis is still a challenge worldwide mainly because of the multifaceted clinical presentation. Leprosy expertise is declining among physicians, even in endemic areas, and focusing almost exclusively on cutaneous signs results in a non-timely diagnosis.<sup>1</sup> In contrast, the

\* Corresponding author.

E-mail addresses: [f9filho@gmail.com](mailto:f9filho@gmail.com) (F. Bernardes-Filho), [rfilipelima@gmail.com](mailto:rfilipelima@gmail.com) (F.R. Lima), [gvoltan@usp.br](mailto:gvoltan@usp.br) (G. Voltan), [npbiomed@yahoo.com.br](mailto:npbiomed@yahoo.com.br) (N.A. de Paula), [mandrey@fmrp.usp.br](mailto:mandrey@fmrp.usp.br) (M.A.C. Frade).

<https://doi.org/10.1016/j.bjid.2021.101634>

1413-8670/© 2021 Sociedade Brasileira de Infectologia. Published by Elsevier España, S.L.U. This is an open access article under the CC BY-NC-ND license (<http://creativecommons.org/licenses/by-nc-nd/4.0/>)

neurological symptoms that worsen over time (tingling, electric-shock pain, foot-drop, loss of sensation, muscle cramp) can emulate many clinical conditions,<sup>1</sup> therefore presenting as an atypical case at the emergency room (ER). Usually in leprosy, only acute reactions are treated as emergency;<sup>2</sup> however, among many patients cared at the emergency department, certainly there are patients with undiagnosed leprosy.

Diagnosis of leprosy, essentially clinical, is based upon detection of at least one of the following signs/symptoms: a) lesion(s) and/or area(s) of the skin with changes in thermal and/or pain and/or tactile sensitivity; b) thickening of peripheral nerve(s), associated with sensory and/or motor and/or autonomic changes; and/or c) presence of *M. leprae*, confirmed by smear microscopy or skin biopsy,<sup>3</sup> that can be confirmed by RLEP-PCR.<sup>4,5</sup>

As a complement to the clinical evaluation, there are quantitative assessments of anti-glycolipid-I (anti-PGL-I) and IgA, IgM and IgG antibodies against the anti-mammalian cell entry 1A (anti-Mce1A) protein by indirect ELISA.<sup>4,6</sup>

Considering that neural involvement is present in all clinical forms of leprosy, as damage to the nerve trunks and/or cutaneous nerve endings,<sup>5,7</sup> the evaluation of these nerves by ultrasound is helpful due to the possibility of examining a larger territory of the nerve that may be inaccessible to clinical examination, as well as better locating and defining the thickening point and/or peripheral nerve alteration.<sup>8</sup>

The objective of this report is to draw attention to mistaken referrals of atypical clinical leprosy cases with chronic neurological symptoms to the ER, underscoring the need to improve the teaching of leprosy for all health professionals, mainly in medical schools.

## Case series

This is a cross-sectional study carried out at a tertiary referral hospital in Ribeirão Preto, inner São Paulo, Brazil. The emergency department (ED) where this study was carried out, there are approximately 650 visits monthly, all of them referred from secondary health care units following medical evaluation. The sampling frame of the study includes patients who accessed care at the ED from April 2020 through April 2021.

Herein, we report a case series of leprosy patients diagnosed at the ER, aged 34 to 75 years; clinical features and complementary exams are detailed in Table 1 to 4. Of the referred patients, three were suspected of having acute coronary syndrome, as they complained of tingling in the left upper limb without chest pain, electrocardiograms with sinus rhythm without ischemic cardiac changes and normal-range cardiac markers. Two other patients were suspected of acute arterial occlusion, and another patient of deep vein thrombosis, as they all complained of unilateral leg pain and two of them had foot-drop. Venous and arterial ultrasounds were normal. The sixth patient was referred with a suspicion of an infected skin ulcer.

Positive dermatoneurological findings on examination included hypo-anesthetic skin lesions (Figs. 1–3), thickened nerves and altered hands (42.8%) and feet (100%) tactile

sensitivity. All cases were multibacillary and had some grade disability (GD), with 42.9% of G2D.

Considering serological results, 100% (7/7) were negative for IgM anti-PGL-I, 71.4% (5/7), 100% (7/7) and 42.8% (3/7) were positive for IgA, IgM and IgG anti Mce1A protein of *Mycobacterium leprae* antibodies, respectively (Fig. 4). *Mycobacterium leprae* DNA RLEP-PCR was positive in 100% (7/7) patients. Ultrasound of peripheral nerves showed asymmetric and focal multiple mononeuropathy in all patients, four with intraneural Doppler signal (Fig. 5).

All patients started multidrug therapy (MDT/WHO). Two of them also used prednisone 1 mg/kg/day with slow reduction of neural inflammation. All patients showed significant improvement in dermatological signs and neurological symptoms under specific antimicrobial treatment.

For leprosy surveillance, 15 intra-domiciliary contacts from four leprosy patients were also evaluated, and three (20%) new leprosy patients were diagnosed, all from the same family.

## Discussion

The decline in leprosy prevalence and the commitment to leprosy elimination as a public health problem in many countries have been accompanied by a decline in disease expertise.<sup>9</sup> Leprosy can mimic many common dermatological and neurological conditions,<sup>4,5</sup> leading to delays in diagnosis. However, even in the presence of anesthetic lesions with thickened nerves, hallmarks signs, many physicians seem to lack the skills to diagnose leprosy, even the classic forms. In routine, almost exclusively neuritis is considered an emergency in leprosy, an exclusive sign to justify emergency care because of acute neural damage and sensory and/or motor disability. Surprisingly, all our patients had a history of chronic neural pain, longer than three months, but only four of them showed neuritis on ultrasound (positive intraneural Doppler signal). Additionally, all patients had altered feet tactile sensitivity test, also defining the pattern of asymmetrical and focal multiple mononeuropathy in leprosy diagnosis, and also for the clinical-therapeutic follow-up.

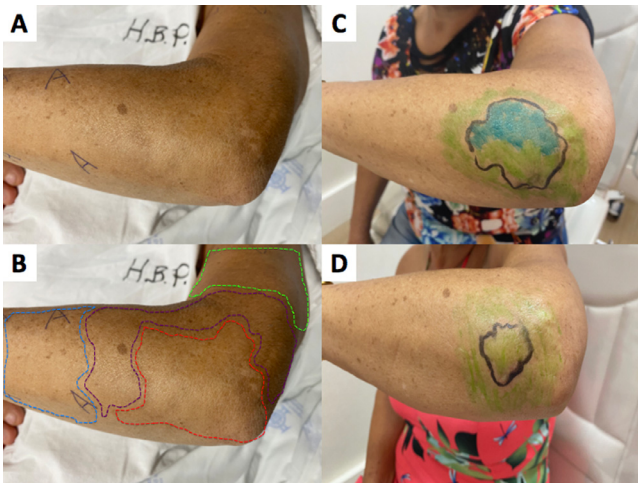
Serological techniques and PCR are used as complementary tests, but unfortunately they are only restricted to referral and research centers. PGL-I-serological positivity may indicate continuous exposure to the bacillus in the community, but negative results do not exclude the diagnosis of leprosy. In addition to clinical findings, we also used serological tests with a new biomarker (Anti-Mce1A) that indicates active or previous disease, and/or for screening of household contacts. The anti-Mce1A antibodies (IgA, IgM and IgG) showed significantly better diagnostic performance than anti-PGL-I, as already described, with sensitivity and specificity ranging from 74.2-100% and 89.1-100%, respectively,<sup>6</sup> while anti-PGL-I showed lower seropositivity range of 23-78% among leprosy patients.<sup>6</sup>

As published before by Frade et al.,<sup>8</sup> we analyzed the cross-sectional areas (CSA) in median nerves (carpal tunnel and distal forearm), ulnar nerves (cubital tunnel and distal arm), common fibular nerves (head of fibula and distal thigh) and tibial nerves (posterior to the ankles). Nerve asymmetry was

**Table 1 – Patient demographics, presenting symptoms, clinical and peripheral nerves ultrasound characterization.**

Patient No.	Emergency room			Clinical characterization		Ultrasound of peripheral nerves			
	Age, y/ Sex	Reason for attendance / symptom duration	Diagnosis of referral	Skin	Nerves	No. of points asymmetric by thickening (>2 mm <sup>2</sup> CSA R/L difference)	No. of focality intranerve points detected (>2 mm <sup>2</sup> difference)	No. of qualitative morphologically altered points	Intra / perineural Doppler signal
1	70/M	Tingling in the LUL / 2 years	ACS	Large anesthetic area on the left leg and foot; localized irregular patches of circumscribed hair loss on left lower limb	Enlargement of the left common fibular, left superficial fibular and right posterior tibial nerves; electric shock-like pain on the right superficial fibular and right posterior tibial nerves	5	2	5	Negative
2	64/F	Tingling in the LUL / 5 months	ACS	Anesthetic hypochromatic macule on the left elbow and forearm; localized irregular patches of circumscribed hair loss on lower limbs; incomplete endogenous histamine test	Enlargement and electric shock-like pain on the common fibular and left ulnar nerves	4	5	4	Positive
3	34/M	Tingling in the LUL / 8 months	ACS	Hypochromatic, anhydrotic and hypo-anesthetic macule in the left frontal region, left distal madarosis	Enlargement and electric shock-like pain on the right common fibular and left ulnar nerves	3	3	4	Negative
4	38/F	Left leg pain / 3 months	DVT	Hypochromatic, anesthetic macule with incomplete endogenous histamine test on left knee	Enlargement and electric shock-like pain on the left common fibular and posterior tibial nerves	3	4	5	Positive
5	64/F	Left leg pain / 2 years	AAO	Left dropped foot, hypochromatic anesthetic macules with incomplete endogenous histamine test on the right knee, anesthetic xerotic plaque on the left foot	Enlargement and electric shock-like pain on the left common fibular	3	6	6	Positive
6	63/M	Left leg pain / 6 years	AAO	Left dropped foot; hypochromatic and hypoaesthetic macules with incomplete endogenous histamine test on the knees and elbows	Enlargement of ulnars, common fibulars and posterior tibials nerves	6	3	4	Positive
7	75/M	Infected ulcer / 10 years	Venous ulcer	Bilateral ulnar claw, bilateral trophic plantar ulcers, amyotrophy, lobule infiltration and bone resorption	Enlargement of common fibulars and posterior tibials nerves	4	3	5	Negative

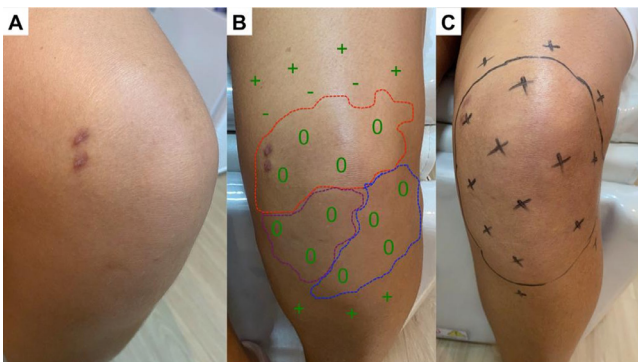
**Legend:** AAO acute arterial occlusion; ACS acute coronary syndrom; CSA cross-sectional area; DVT deep vein thrombosis; LUL left upper limb.



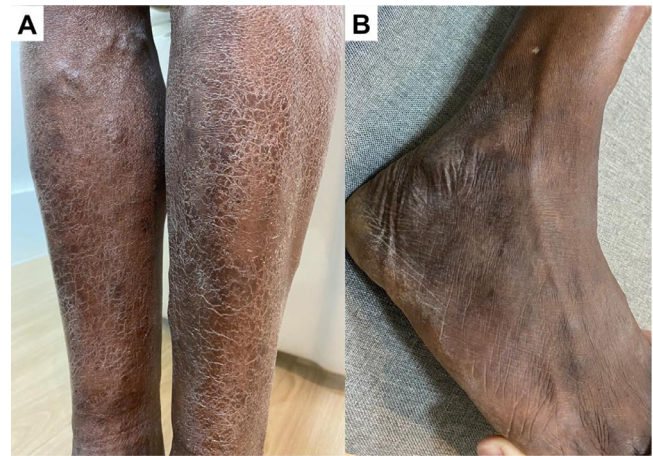
**Fig. 1 – (A) Hypochromatic, hypo-anesthetic macule on the left upper limb; (B) Areas with loss of tactile sensitivity [green dashed area = 0.07 gram-force (normal threshold of tactile sensitivity); blue dashed area = 0.2 g-f; purple dashed area = 2.0 g-f; red dashed area = 4.0 g-f]; (C-D) improvement of tactile sensitivity after five months of multibacillary multi-drug therapy.**

calculated by the difference between the biggest and the smallest CSA in the same nerve point. Nerve focality was calculated by the difference between two points (proximal and distal CSA) in the same nerve. Qualitative morphological alterations were defined by loss of fascicular nerve pattern, heterogeneous fascicular distention, signs of perineural fibrosis. The intra-nerve Doppler positive sign is indicative of active neuritis.

Ultrasonography is a technique that allows good quantitative and qualitative representation of peripheral, superficial



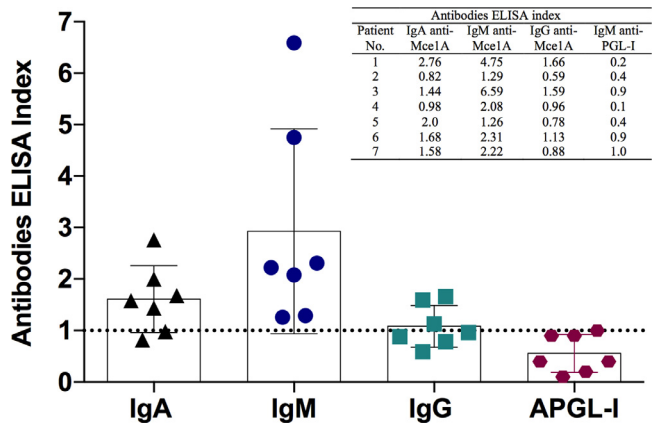
**Fig. 2 – (A) Hypochromatic, hypo-anesthetic macule on the left knee; (B) Areas with loss of tactile sensitivity [anesthetic (0), hypoesthetic (-) and normoesthetic (+) points to green monofilament (0.07 g-f, normal threshold of tactile sensitivity); blue dashed area = 0.2 g-f; purple dashed area = 2.0 g-f; red dashed area = 4.0 g-f]; (C) improvement of tactile sensitivity after six months of multibacillary multidrug therapy.**



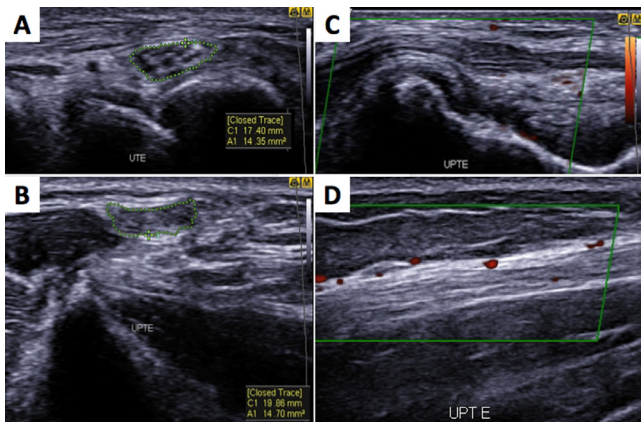
**Fig. 3 – (A) Multiple ichthyosis in islets in the lower limbs; (B) linear thickening of right superficial fibular nerve.**

and deep nerves by measuring cross sectional areas and provides information about echotextural changes and fascicular patterns in neuropathies, which allow the detection of asymmetry and focality of peripheral nerve thickening.<sup>8,10</sup> Ultrasound evaluation was in line with the multibacillary classification of the patients, since 100% showed nerve thickening, even in those presenting only hypochromatic macular lesions, as clinical signs.

In the daily routine of health services, the unavailability of complementary molecular biology and serologic tests to detect the different clinical forms of leprosy, the reaction states and the identification of subclinical infection are challenges to control the magnitude of the disease, leading to misdiagnosis at the ER.



**Fig. 4 – Leprosy serology: comparison of antibodies levels by indirect enzyme-linked immunosorbent assay (ELISA) against IgM anti-PGL-I (APGL-I) and IgA, IgM and IgG anti-Mce1A antigens of *M. leprae*. The respective index was calculated by dividing the optical density of each sample by the cut-off, and indexes above 1.0 were considered positive.**



**Fig. 5 – Ultrasonography showing asymmetric neuropathy at the left ulnar nerve with thickened transverse sectional areas in the cubital tunnel (A-UTE) and in the distal region of the arm (B-UPTE) with hyperechoic perineurs and evident fascicular distention (C), in addition to blood flow in the epineurial and intraneurial region (D) as a sign of active neuritis.**

Attention to the possibility of leprosy diagnosis at emergency services should be paid not only in countries considered endemic, but in all countries where the medical expertise on leprosy is far from ideal. This case series exemplifies the need to strengthen the teaching of leprosy health professionals both in graduate courses and residency programs of the various specialties, as well as the importance to continuously promote leprosy education among health workers. All clinicians must be alert to neurological symptoms, mainly the neural pain, besides dermatological signs of leprosy, allowing for an early diagnosis thus avoiding many cases of irreversible nerve damage and interrupt the chain of disease transmission

### Financial support

This work was supported by the Center of National Reference in Sanitary Dermatology focusing on Leprosy of Ribeirão Preto Clinical Hospital, Ribeirão Preto, São Paulo, Brazil; the Brazilian Health Ministry (MS/FAEPAFMRP-USP: 749145/ 2010 and 767202/2011); Fiocruz Ribeirão Preto - TED 163/2019 - Processo: N° 25380.102201/2019-62/ Projeto Fiotec: PRES-009-FIO-20. The funders had no role in study design, data collection and analysis, decision to publish, or preparation of the manuscript.

### Author contributions

All authors meet the criteria for authorship, including acceptance of responsibility for its scientific content. All authors have contributed to prepare and they approved the final manuscript

### Conflicts of interest

The authors have no conflicts of interest to declare.

### REFERENCES

- Bernardes Filho F, Paula NA, Leite MN, et al. Evidence of hidden leprosy in a supposedly low endemic area of Brazil. *Mem Inst Oswaldo Cruz.* 2017;112:822–8.
- Hoffner RJ, Esekogwu V, Mallon WK. Leprosy in the emergency department. *Acad Emerg Med.* 2000;7(4):372–6.
- Brasil. Ministério da Saúde. Secretaria de Vigilância em Saúde. Departamento de Vigilância das Doenças Transmissíveis. Diretrizes para vigilância, atenção e eliminação da Hanseníase como problema de saúde pública: manual técnico-operacional [recurso eletrônico] /Ministério da Saúde, Secretaria de Vigilância em Saúde, Departamento de Vigilância das Doenças Transmissíveis. Brasília: Ministério da Saúde; 2016.
- Bernardes Filho F, Santana JM, Silva CML, et al. Leprosy in a prison population: a new active search strategy and a prospective clinical analysis. *PLoS Negl Trop Dis.* 2020;14(12):e0008917. Dec 10;.
- Bernardes Filho F, Silva CML, Voltan G, et al. Active search strategies, clinicoimmunobiological determinants and training for implementation research confirm hidden endemic leprosy in inner São Paulo, Brazil. *PLoS Negl Trop Dis.* 2021;15(6):e0009495.
- Lima FR, Takenami I, Cavalcanti MAL, et al. ELISA-based assay of immunoglobulin G antibodies against mammalian cell entry 1A (Mce1A) protein: a novel diagnostic approach for leprosy. *Mem Inst Oswaldo Cruz.* 2017;112(12):844–9.
- Nascimento OJ. Leprosy neuropathy: clinical presentations. *Arq Neuropsiquiatr.* 2013;71(9B):661–6.
- Frade MA, Nogueira-Barbosa MH, Lugão HB, Furini RB, Marques Júnior W, Foss NT. New sonographic measures of peripheral nerves: a tool for the diagnosis of peripheral nerve involvement in leprosy. *Mem Inst Oswaldo Cruz.* 2013;108(3):257–62.
- Salgado CG, Barreto JG, da Silva MB, et al. What do we actually know about leprosy worldwide? *Lancet Infect Dis.* 2016;2016(16):778.
- Lugão HB, Frade MA, Marques Junior W, Foss NT, Nogueira-Barbosa MH. Ultrasonography of leprosy neuropathy: a longitudinal prospective study. *PLoS Negl Trop Dis.* 2016;10(11):e0005111.