



# The Brazilian Journal of INFECTIOUS DISEASES

www.elsevier.com/locate/bjid



## Case report

# Recurrent pulmonary mucormycosis after lobectomy in a non-smoking patient without predisposing risk factors

Lu Zhang<sup>a</sup>, Xinlun Tian<sup>b,\*</sup>, Peng Wang<sup>c</sup>, Hong Zhang<sup>b</sup>, Ruie Feng<sup>d</sup>

<sup>a</sup> Department of Medicine, Peking Union Medical College Hospital, Chinese Academy of Medical Sciences, Beijing, China

<sup>b</sup> Department of Respiratory Medicine, Peking Union Medical College Hospital, Chinese Academy of Medical Sciences, Beijing, China

<sup>c</sup> Department of Medical Laboratory, Peking Union Medical College Hospital, Chinese Academy of Medical Sciences, Beijing, China

<sup>d</sup> Department of Pathology, Peking Union Medical College Hospital, Chinese Academy of Medical Sciences, Beijing, China

## ARTICLE INFO

### Article history:

Received 1 April 2012

Accepted 11 July 2012

Available online 8 November 2012

### Keywords:

Pulmonary mucormycosis

Predisposing risk factor

## ABSTRACT

Pulmonary mucormycosis is a very rare clinical condition in patients without underlying risk factors. A limited number of cases have been reported in predominantly elderly patients; history of smoking appears to be a common feature. A case of non-smoking male who developed pulmonary mucormycosis with the longest reported follow-up is presented. In addition, this is also the first reported case with disease recurrence after lobectomy (two years) in an immunocompetent host. Treatment with an additional lobectomy and amphotericin B was successful in this patient.

© 2012 Elsevier Editora Ltda. All rights reserved.

## Introduction

Mucormycosis (also termed as zygomycosis) is an opportunistic infection caused by fungi from the order of Mucorales, which are quite common in the environment. Clinical infections caused by such fungi usually occur in the presence of predisposing risk factors, such as diabetes mellitus, hematologic malignancies, hematopoietic stem cell transplantation, deferoxamine therapy, HIV infection, iron overload, trauma or burns, and use of corticosteroids or immunosuppressive drugs.<sup>1,2</sup> Mucormycosis in patients without underlying conditions is rare, and when it occurs, it is likely to be a superficial infection.<sup>2</sup> Pulmonary mucormycosis in such patients is exceedingly rare. To the best of the authors' knowledge, only ten cases have been previously reported<sup>3–12</sup> in the literature,

and most were elderly male smokers. Herein is reported a case of a non-smoking young male who was 12 years old at the onset of the disease. With the longest follow-up known in literature, this is also the first reported case of an immunocompetent patient who suffered from disease recurrence after surgical treatment. Meanwhile, this is also the first such case reported in China, the most populous country in the world.

## Case presentation

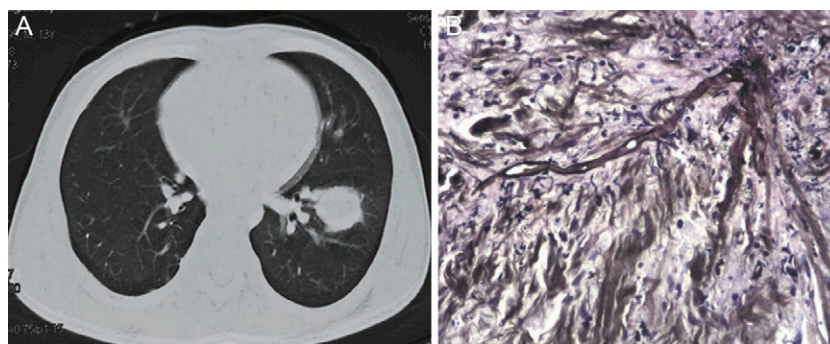
In August, 2008, a 14-year-old boy was referred to this hospital with a two-month history of fever, cough, purulent sputum, and nasal discharge. Two years earlier, he had undergone a lobectomy of right inferior lobe at a local hospital due to fever and pulmonary mass in the right lung, with a post-operative

\* Corresponding author at: Department of Respiratory Medicine, Peking Union Medical College Hospital, Chinese Academy of Medical Sciences, Beijing, 100730, China.

E-mail address: pumchtianxinlun@gmail.com (X. Tian).

1413-8670/\$ – see front matter © 2012 Elsevier Editora Ltda. All rights reserved.

<http://dx.doi.org/10.1016/j.bjid.2012.10.005>



**Fig. 1 – (A) Chest CT scan showed a mass in lower lobe of the left lung. (B) Broad, irregularly branched and non-septate hyphae with positive methenamine silver stain observed in lung tissue (magnification,  $\times 40$ ).**

pathological diagnosis of 'inflammatory pseudotumor'. After the surgery, he was doing well until two months before this admission. He was an otherwise healthy boy with no history of diabetes mellitus, hematologic malignancies, burns or trauma, intravenous drug use, malnutrition or diarrhea, renal failure, or use of corticosteroids or immunosuppressive drugs or deferoxamine. He lived in a small village in the Shandong province of China, with both parents working as corn farmers. The boy sometimes helped with farming as well. He was a non-smoker and had never consumed alcohol.

On examination, the patient was febrile with a temperature of  $38^{\circ}\text{C}$  and normotensive. Purulent nasal discharges associated with sinus pain were noted. Breath sounds were low in both lower lungs with crackles heard on the left side. Laboratory investigation showed the following results (normal reference range in parenthesis): hemoglobin 12.1 (11.0-16.0) g/dL; white blood cell count,  $9.5 \times 10^9$  ( $4.0$ - $10.0 \times 10^9$ ) cells/L; raised erythrocyte sedimentation rate of 53 ( $< 20$ ) mm/h and elevated C-reactive protein level of 91.4 ( $< 3$ ) mg/L; serum urea, 3.5 (2.5-6.5) mmol/L; creatinine, 64 (60-110)  $\mu\text{mol/L}$ ; sodium, 136 (135-145) mmol/L; and potassium 4.0 (3.5-5.5) mmol/L. Liver function tests were normal: total proteins, 71 (60-85) g/L, alanine transaminase (ALT), 11 (10-40) IU/L; aspartate transaminase (AST), 21 (8-40) IU/L; albumin, 40 (35-55) g/L; and alkaline phosphatase (ALP) 60 (44-147) IU/L. Serum protein electrophoresis showed elevated gammaglobulins. A 75 g oral glucose tolerance test was normal. HIV serology was negative. Results of serum iron studies were all within normal range: serum iron concentration, 84 (60-150) microg/dL; plasma total iron binding capacity, 288 (200-400) microg/dL; transferrin saturation, 29 (25-35)%; serum ferritin concentration, 46 (14-336) ng/mL. Sputum cultures were negative for bacteria or fungi. Sinus computed tomography (CT) scan revealed a dense and non-homogeneous mass and sinusitis in the left maxilla, and chest CT showed a mass with a diameter of 3 cm in the left inferior lobe (Fig. 1A). Endoscopic evaluation of the left maxillary sinus showed tissue necrosis and the pathology of the specimen was 'chronic inflammation'. A careful scrutiny of the chest CT confirmed that there was no lesion in the left lung at the initial presentation of the disease, and a review of the lung specimen taken from the right inferior lobe two years before showed an unknown branched pathogen with positive methenamine silver stain. Further, transthoracic lung biopsy exhibited inflammatory changes and some

broad, non-septate hyphae with positive methenamine silver stain, suggestive of pulmonary mucormycosis. A left inferior lobectomy was performed with thoracoscopy. Histopathological examination of the resected lung tissue showed broad, irregularly branched and non-septate hyphae (Fig. 1B). *Rhizopus oryzae* were identified in tissue specimen culture. A diagnosis of mucormycosis involving the left lung and sinuses was therefore confirmed. Surgical debridement of the sinuses was undertaken, and amphotericin B therapy was initiated. The patient was defervescent after the treatment, and the erythrocyte sedimentation rate and C-reactive protein level returned to normal. The boy was doing well during the follow-up and was healthy on his last follow-up visit in September, 2011.

## Discussion

Mucormycosis is an opportunistic infection that is very rare in patients without predisposing risk factors. Superficial infections (such as cutaneous/subcutaneous infections) are the most representative clinical manifestation.<sup>2</sup> Deep organ involvement is not common in immunocompetent individuals, while pulmonary mucormycosis is so rare that, to the authors' knowledge, only ten other cases of pulmonary mucormycosis (excluding mucormycosis involving only the mediastinum without either lung) in patients without underlying disease have been reported in the English language literature<sup>3-12</sup> since 1950 (Table 1). The present case not only adds a further illustration of this rare medical condition, but is also of interest for several reasons.

First, although the previously reported cases all included patients without obvious underlying diseases, several potential risk factors might have still existed in some of them; such as mild diabetes, broad-spectrum antibiotic treatment after a fracture, etc.<sup>4,5</sup> Moreover, almost all patients were chronic smokers (five out of six after excluding those without a clear history of smoking, and a two month old infant);<sup>7</sup> and smoking, which may enhance the virulence of fungi<sup>13</sup> and compromise the protective barriers<sup>14</sup> in airways, has been demonstrated to be a risk factor in fungal infection other than mucormycosis.<sup>15</sup> Furthermore, patients from most of the previous reports were of older age (mean age, 53 years; excluding the infant), which often leads to a greater chance of having

**Table 1 – Reports of pulmonary mucormycosis in patients without underlying diseases.**

No.	Authors	Gender	Age (years)	Smoking	Farming	Involvement	Manifestation	Treatment	Follow-up after disease onset	Prognosis
1	Murphy JD et al. <sup>3</sup>	Male	40	Unknown	Yes	RML	Nodule	Surgery	3 months	Alive
2	Blankenberg HW et al. <sup>4</sup>	Female	23	Yes	Unknown	RML, RLL	Abscess with cavitation	Surgery	14 months	Alive
3	Record NB et al. <sup>5</sup>	Male	66	Yes	Unknown	LUL	Abscess with cavitation	Surgery + drug	4 months	Deceased
4	Matsushima T et al. <sup>6</sup>	Male	52	Yes	Yes	RUL	Nodule	Surgery	19 months	Alive
5	Ferrinho P Del GM <sup>7</sup>	Male	2 months	—	—		Pneumonia	no	4 days	Deceased
6	Lake FR et al. <sup>8</sup>	Male	45	Unknown	Unknown	LUL	Abscess with cavitation	Surgery + drug	24 months	Alive
7	Majid AA et al. <sup>9</sup>	Male	66	Yes	Yes	LUL	Nodule	Surgery	8 months	Alive
8	Kutsuzawa T et al. <sup>10</sup>	Male	61	Unknown	Yes	RML, RLL, LUL	Multiple nodules	Drug	32 months	Alive
9	Sharma A, et al. <sup>11</sup>	Male	50	Yes	Yes	Multiple lobes	Multiple nodules	Drug	18 months	Alive
10	Yokoi S et al. <sup>12</sup>	Male	72	No	Yes	RLL	Nodule	Surgery	36 months	Alive
11	Present case	Male	12	No	Yes	RLL, LLL	Nodule	Surgery + drug	5 years	Alive

RML, right middle lobe; RLL, right lower lobe; LUL, left upper lobe; RUL, right lower lobe; RLL, right lower lobe; LLL, left lower lobe.

underlying conditions. One of the patients, for example, was a 72-year-old male<sup>12</sup> with a history of malaria and right clavicle and maxillary fracture. The present patient, at a much younger age and with no history of smoking, may provide more convincing evidence that a patient without any known risk factors can be a victim of mucormycosis. This might be due to the devastating nature of these filamentous fungi, capable of secreting several toxins or proteases,<sup>16</sup> which may directly destroy endothelial cells in mucosal membranes and cause subsequent deep organ infection.

Second, although surgery alone has been proved successful in patients with pulmonary mucormycosis confined to one or two lobes,<sup>3,4,6,9,12</sup> the present case showed that recurrent infection might be a problem in post-operative patients without continued treatment with anti-fungal drugs. To the best of the authors' knowledge, this is the only reported case of an immunocompetent patient suffering from recurrent pulmonary mucormycosis after lobectomy surgery. This might be due to two possible reasons: first, the longer follow-up of the patient (five years after symptom onset and two years after recurrence of infection) compared to other cases (mean follow-up of 16 months). There is a possibility that the patients with surgical therapy alone might have increased risk of recurrent mucormycosis if the follow-up period were extended. The other potential reason might have been the concomitant sinonasal involvement in this patient, as the sinus could serve as a fungi 'reservoir' after pulmonary lobectomy that leads to further recurrence. Therefore, the findings from the present case suggest that surgery and antifungal therapy might be of equal importance even for patients without underlying conditions, and the sinonasal involvement could serve as a potential risk factor for disease recurrence. Moreover, as the importance of combination therapy consisting of surgery and antifungal chemotherapy has been long recognized because it could

improve patients' survival,<sup>1</sup> this case also indicates that combination therapy might prevent disease recurrence.

With a careful review of all the reported cases and the present case, it was found that almost all patients farmed at some time in their life, with the only exceptions being the infant and those without reported occupational history. This finding possibly reflects the fact that fungi in the order of Mucorales often exist in decaying vegetation and in soils. Thus, farming could be a predisposing risk factor and taking a careful history might help.

Last but not the least, although cases of mucormycosis without obvious risk factors have been reported in many other countries,<sup>2</sup> no such cases have been reported in China, the country with the largest population.<sup>2</sup> Considering that the language barrier could be a contributing factor, no such cases were found in the Chinese language database CNKI (China National Knowledge Infrastructure, the largest academic database in China). This might be due to the under-recognition of this disease in the immunocompetent population in China, and in the present case, for example, the local hospital missed the diagnosis. The authors thus hope that this present case report can raise vigilance for the disease in China.

## Conclusion

Pulmonary mucormycosis in the absence of underlying disease is a very rare clinical condition. The reported case of a young male without history of smoking suggests that a patient without any known risk factors could have pulmonary mucormycosis. Surgical resection alone might be insufficient for eradication of pulmonary mucormycosis, even for localized lesions, and recurrence of disease could ensue after surgery. Antifungal therapy has proved to be beneficial for

patient outcome. Farming might serve as a risk factor, and taking a careful history is warranted in suspicious cases.

---

### Conflict of interest

All authors declare to have no conflict of interest.

---

### Acknowledgements

The authors thank Dr. Yi Xiao, Dr. Hongbing Zhang, and Dr. Dingxin Qin for the support of the study and revision of the manuscript.

---

### REFERENCES

- Roden MM, Zaoutis TE, Buchanan WL, et al. Epidemiology and outcome of zygomycosis: a review of 929 reported cases. *Clin Infect Dis*. 2005;41:634-53.
- Mignogna MD, Fortuna G, Leuci S, et al. Mucormycosis in immunocompetent patients: a case-series of patients with maxillary sinus involvement and a critical review of the literature. *Int J Infect Dis*. 2011;15:e533-40.
- Murphy JD, Bornstein S. Mucormycosis of the lung. *Ann Intern Med*. 1950;33:442-53.
- Blankenberg HW, Verhoeff D. Mucormycosis of the lung. A case without significant predisposing factor. *Am Rev Tuberc*. 1959;79:357-61.
- Record NB, Ginder DR. Pulmonary phycomycosis without obvious predisposing factors. *J Am Med Assoc*. 1976;235:1256-7.
- Matsushima T, Soejima R, Nakashima T. Solitary pulmonary nodule caused by phycomycosis in a patient without obvious predisposing factors. *Thorax*. 1980;35:877-8.
- Ferrinho P, Del GM. Pulmonary phycomycosis without obvious predisposing factors. *S Afr Med J*. 1985;68:893.
- Lake FR, McAleer R, Tribe AE. Pulmonary mucormycosis without underlying systemic disease. *Med J Aust*. 1988;149:323-6.
- Majid AA, Yii NW. Granulomatous pulmonary zygomycosis in a patient without underlying illness. *Chest*. 1991;100:560-1.
- Kutsuzawa T, Matsuura Y, Sakuma H, Narimatsu H, Ohta Y, Yamabayashi H. Multiple pulmonary nodules caused by zygomycosis in a patient without predisposing factors. *Jpn J Med*. 1991;30:435-7.
- Sharma A, Gupta V, Singh RS, Kakkar N, Singh S, Bamberg P. Angioinvasive pulmonary mucormycosis presenting as multiple bilateral pulmonary nodules in a patient without obvious predisposing factors. *Singapore Med J*. 2008;49:e269-71.
- Yokoi S, Iizasa T, Yoshida S, et al. Case report. Localized pulmonary zygomycosis without pre-existing immunocompromised status. *Mycoses*. 1999;42:675-7.
- MacDougall L, Fyfe M, Romney M, Starr M, Galanis E. Risk factors for *Cryptococcus gattii* infection, British Columbia, Canada. *Emerg Infect Dis*. 2011;17:193-9.
- Arcavi L, Benowitz NL. Cigarette smoking and infection. *Arch Intern Med*. 2004;164:2206-16.
- Baboni FB, Barp D, Izidoro AC, Samaranayake LP, Rosa EA. Enhancement of *Candida albicans* virulence after exposition to cigarette mainstream smoke. *Mycopathologia*. 2009;168:227-35.
- Kontoyiannis DP, Lewis RE. Invasive zygomycosis: update on pathogenesis, clinical manifestations, and management. *Infect Dis Clin North Am*. 2006;20:581-607.