

Atypical case of Mediterranean spotted fever

Dear Editor,

The authors present a case of atypical severe (malignant) Mediterranean spotted fever, with a brief review on the subject. Although not previously described in Brazil, the possibility of imported cases, especially from Portuguese tourists, is real. This case report highlights the severe form of the disease and the possibility of atypical presentation with confounding differential diagnosis. A brief review of classical presentation is also done. The authors believe it is a valid paper and a good contribution to your Journal of Infectious Diseases. The content of the manuscript represents the views of the coauthors, and neither the corresponding author nor the coauthors have submitted duplicate or overlapping manuscripts elsewhere.

Best regards,

João Figueira-Coelho

[Braz J Infect Dis 2010;14(3):213-216]©Elsevier Editora Ltda.

Authors

João Figueira-Coelho,
MD¹

Teresa Martins, MD²

João Machado, MD²

Fernando Maltez, MD²

¹Department of Internal
Medicine I - Hospital Curry
Cabrál, Lisbon, Portugal.

²Department of Infectious
Diseases - Hospital Curry
Cabrál, Lisbon, Portugal.

INTRODUCTION

Mediterranean spotted fever is an endemic zoonosis in the Mediterranean area (Southern Europe and Northern Africa) caused by *Rickettsia conorii*, an intracellular gram-negative bacteria. The main vector for the disease is the dog tick *Rhipicephalus sanguineus*, which occurs mainly in the summer months, with 87% of cases between July and September.^{1,2} Due to the affinity to endothelial cells, *Rickettsia conorii* infection causes a small to medium vessel vasculitis, leading to disease clinical manifestations.³ After an average incubation period of 6 days, fever and flu-like symptoms are followed, usually within 3 to 5 days, by a maculopapular rash with tendency to generalization, involving palms and plants.^{4,5} An inoculation scar (“*tache noire*”) is usually identified but Portuguese data report a 12-61% possibility of not finding it.^{1,6,7,8} Treatment relies mainly on doxycycline 200 mg/day, with macrolides josamycine, clarithromycin and azithromycin, and the fluoroquinolone ciprofloxacin as possible alternatives;³ the duration of treatment should be guided by clinical response, being usually safe to conclude it 24 h after fever ending. Although the early reports revealed a low mortality rate of 1-3%,⁹ since the first description of severe cases of the disease

made by Raoult *et al.* in 1982,¹⁰ its reported frequency has increased in many countries. We present the case of a 48-year-old women with an atypical severe form of the disease.

CASE REPORT

A 48-year-old caucasian women came to the Emergency Room with a ten-day history of fever (38.5-39.5° C), fronto-occipital headaches and polyarthralgia, associated with odinophagia, nausea, vomiting, generalized abdominal pain, adinamia and asthenia. Four days before the beginning of these symptoms she had been harvesting grapes at her hometown in the Portuguese region of Ribatejo, and she reported to have been bitten by a tick in the right inguinal region. She denied any other recent travelling, ingestion of unpasteurized milk/milk-derivative or non-drinkable water, and direct contact with animals. The patient had a past history of rheumatoid arthritis, currently medicated with salazopirine and etoricoxib, and a depressive disorder with trazodone, bromazepam and propranolol. On clinical observation, the patient was pale, blood pressure 103/65 mmHg, heart rate 100 bpm, febrile (38.5° C), normal cardiac and pulmonary auscultation, painful abdomen on

Submitted on: 02/25/2010

Approved on: 03/02/2010

Correspondence to:

João Figueira-Coelho, MD
Rua Domingos Sequeira,
Emp. Amorosa Place
Ed. 2, Bloco B, 6° A
2675-338
Odivelas – Portugal
Phone: +351-933260906
E-mail: jffcoelho@
gmail.com

Table 1. Chronological evolution of laboratory tests

	Day 1	Day 2	Day 5	Day 11	Day 26 (day 8 post discharge)
Leukocytes (4-10 x 10 ⁹ /L)	3.9	12.1	6.8	5.5	9.3
Neutrophils (37-72%)	88.2	78.5	50.7	60.8	65.6
Hemoglobin (12-16 g/dL)	11.8	10.9	10.3	9.1	10.9
Platelets (150-400 x 10 ⁹ /L)	56	23	91	503	353
aPTT* (26-36 sec)	40.9	40.6	26.9	-	-
CRP* (< 1 mg/dL)	26.1	27.2	9.81	5.6	1
Urea (15-45 mg/dL)	49.1	47.8	-	10	19
Creatinine (0.7-1.2 mg/dL)	2.4	1.8	1.2	0.7	0.9
Na ⁺ (137-145 mEq/L)	131	143	150	134	137
AST* (14-36 U/L)	165	297	219	33	30
ALT* (9-52 U/L)	107	153	151	42	27
AP* (38-126 U/L)	-	205	310	272	131
GGT* (12-43 U/L)	-	9-2	106	112	45
TB* (0.2-1.3 mg/dL)	-	2.7	1.4	0.6	0.3
DB* (0-0.3 mg/dL)	-	2.3	1.2	0.4	-
LDH* (313-618 U/L)	1209	1336	1156	697	417
CK* (30-135 U/L)	46	103	117	-	-
Glycemia (65-105 mg/dL)	118	94	85	-	-
Urynlalysis	Leucocytes 75 Erythrocytes 2+	Erythrocytes 2+	Erythrocytes 1+	-	-

* aPTT - activated thromboplastin time; AST - aspartate aminotransferase; ALT - alanine aminotransferase; AP - alkaline phosphatase; CRP - C - Reactive Protein, GGT - gama glutamyl transferase; TB - total bilirubin; DB - direct bilirubin; LDH - lactate dehydrogenase; CK - creatinine kinase.

the epigastric region without hepatomegaly or splenomegaly, no lymphadenopathy, no edemas, no articular inflammatory signs, and a normal neurologic examination, including absence of meningitis signs. On the right inguinal region, an evanescent 3 cm purple macula was identified.

Laboratory work-up results were as seen on Table 1. Chest X-ray showed an interstitial infiltrate and enlargement of the cardiac area. The diagnosis of Mediterranean spotted fever was, thus, assumed and the patient was admitted in the Infectious Diseases Department and began doxycycline 100 mg 12/12h PO. On day 2, the patient presented mental confusion and disorientation, high fever (39° C), tachypnea, hemodynamic instability (blood pressure 86/40 mmHg, heart rate 114 bpm), conjunctival injection. Due to urinary retention, the patient was undergone to catheterization, revealing a yellowish and fetid vaginal discharge. The presence of meningitis signs led to a lumbar puncture, which revealed no pleocytosis and a normal protein count. A discrete macular erythematous rash, progressing to a petechial aspect, was visible on trunk and arms, without involvement of palms and plants, and an atypical minimal papular lesion was identified on the left shoulder. A laboratory evaluation revealed leukocytosis with neutrofilia, and aggravation of liver enzymes (Table 1). Arterial blood gas revealed respiratory alkalemia (pH 7.64, pCO₂ 21, pO₂ 79, HCO₃⁻ 19.2). Chest X-ray showed bilateral pleural effusion, mainly on the right side, without adenomegaly or pulmonary parenquimal lesions (supported on CT scan). Head CT-scan, abdominal and renal ultrasound and echocardiogram were normal. With the hypothesis of sepsis of unknown origin, possibly a staphylococcal toxic syndrome (although the patient denied the use of vaginal tampons or presence of an intra-

uterine contraceptive device), ceftriaxone 2 gm IV q24 and vancomycin 1 gm IV q12 were added to doxycycline. Blood cultures were negative as well as the vaginal exsudate culture. PCR for *Chlamydia trachomatis* and *Neisseria gonorrhoeae* was negative. Serologic evaluation was negative for HIV 1 and 2. Biopsy of the papular lesion revealed a dense inflammatory infiltrate, composed by histiocytes, lymphocytes and neutrophils, with diffuse and perivascular distribution, without the typical vasculitic signs present in a "tache noire" (Figure 1). Identification of the species was not possible due to technical difficulties in the processing of skin tissue samples. The clinical course of the patient was positive, despite a difficult effervescence period (Figure 2), and discharge was possible on day 18, fully recovered. The levels of erythrocyte glucose-6-phosphate-dehydrogenase (G6PD) were normal - 369 U/10¹² erythrocytes (normal reference range = 146-376 U/10¹² erythrocytes).

The serology for *Rickettsia conorii* was positive, with IgM > 256 and IgG > 1024.

Figure 1: Biopsy of the inoculation scar.

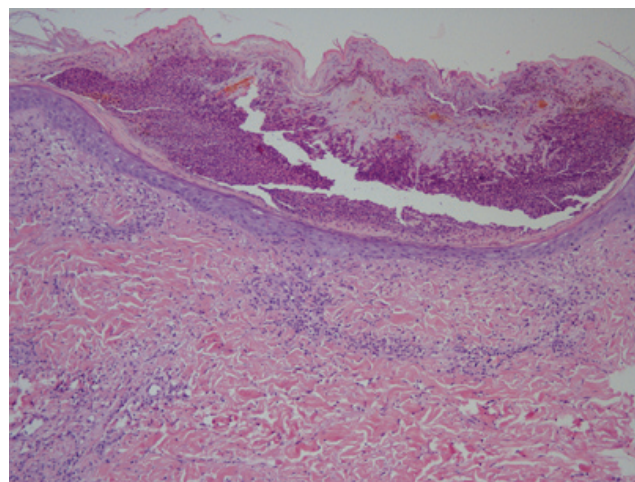
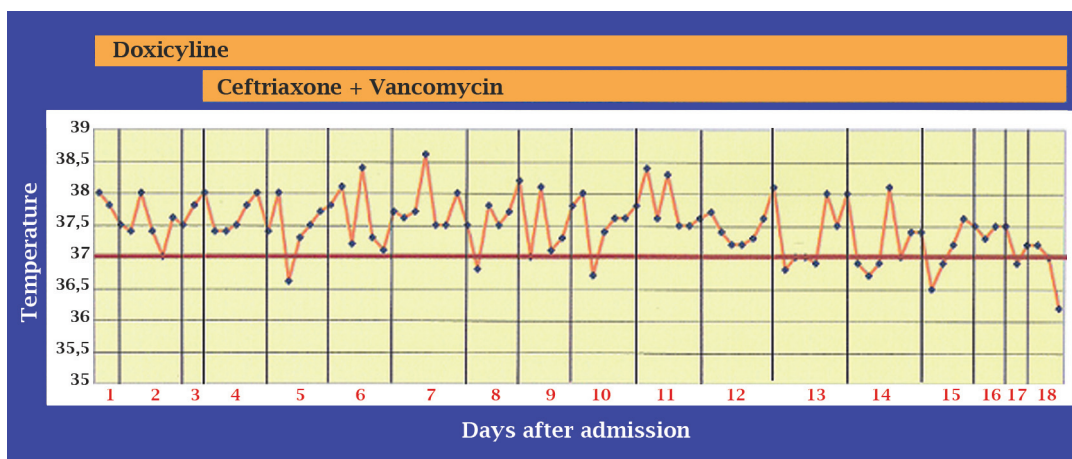


Figure 2: Temperature graphic.



DISCUSSION

Mediterranean spotted fever was first described by Conor and Bruch in Tunisia in 1910.¹¹ In Portugal, the first description of this exanthematic disease was made by Delfim Pinheiro in 1923,⁶ but it was the work of Ricardo Jorge, reviewing several cases in 1930, that brought this disease into attention, naming it “*febre escaro-nodular*”.¹² In 1982, Raoult *et al.* described the first severe cases (malignant form) of this apparent benign disease. This form results from a diffuse vasculitic process, involving several organs – kidney, lung, liver, pancreas, heart, spleen, skin, brain – eventually leading to multiorgan failure. Identified risk factors are: advanced age, immunosuppression, diabetes, cardiac insufficiency, chronic alcoholism, respiratory insufficiency, G6PD deficiency, delay in treatment and inadequate antibiotic therapy.³ The incidence of severe cases varies according to time. In Salamanca, Spain, the disease was more severe in 1983, with an incidence of complications of 19%, in contrast to 3.7% in 1981 and 4.3% in 1982.¹³ Severity also seems to vary according to geographical region. In Beja, a southern district of Portugal, during 1997, the mortality of hospitalized cases with Mediterranean spotted fever was 32.3%, while in Bragança, a northern district, the mortality rate was almost nil, despite having the highest incidence of cases in that country.¹⁴ Of further interest is the fact that, in Portugal, cases caused by the strain “Israeli tick typhus” were also first described in 1997. A study by de Sousa *et al.*, published in 2008, with 140 patients admitted in 13 Portuguese hospitals from 1994 to 2006 with documented identification of the rickettsial strain causing the infection, revealed that this strain appears to be more virulent than the other strain described in the country: the Malish strain.⁷ In the same study, case fatalities were statistically more frequently associated with symptoms of abdominal pain, nausea, vomiting, diarrhea, prostration, altered mental status, evidence of tachypnea, hepatomegaly and a petechial rash, laboratory findings of leukocytosis (> 11300 cells/mm³, partial thromboplastin time > 35 s, glucose level > 110 mg/dL, urea level > 50 mg/dL, creatinine level > 1.2 mg/dL, sodium < 145 mEq/L, total bilirubin level > 1.2 mg/dL, and elevated levels of gama-glutamyl transferase, alkaline phosphatase and creatine kinase. Alcoholism was the only classical co-morbidity associated with increased fatality rate.

Our patient had an atypical presentation in several aspects: the late occurrence of the rash without involvement of palms and plants, the doubtful presence of two inoculation scars, the absence of classic vasculitic findings in the histological examination of the inoculation scar, the extended decline of fever (18 days of treatment). The presence of abdominal pain, nausea, vomiting, prostration, altered

mental status, tachypnea, a petechial rash, elevated partial thromboplastin time, hyponatremia, elevated glucose, urea, creatinine, total bilirubin, gama-glutamyl transferase, and alkaline phosphatase levels predicted a fatal outcome. Although identification was not possible, the “Israeli tick typhus” strain might have been the responsible strain. Apart from the delay in beginning antibiotic treatment, the patient had no identifiable classic risk factor, which probably explains the successful outcome.

CONCLUSION

Severe cases of Mediterranean spotted fever can present with atypical signs. The eventual patient instability can lead to the consideration of a different diagnosis, usually of infectious origin, until the confirmation is done by serology.

REFERENCES

1. Maltez F, Machado J, Morgado A, Proença R. Febre escaro-nodular: casuística de 10 anos (1977-1986). *Estudo Clínico e Epidemiológico de 247 casos*. *O Médico* 1989; 20:459-64.
2. Tavares L, Botas J, Antunes F, Araújo FC. A febre escaro-nodular em Portugal. I – Análise estatístico-epidemiológica nos últimos 30 anos (1955-1984). *O Médico* 1985; 20:838-40.
3. Rovey C, Raoult D. Mediterranean Spotted Fever. *Infect Dis Clin N Am* 2008; 22:515-30.
4. Colomba C, Saporito L, Polara VF *et al.* Mediterranean spotted fever: clinical and laboratory characteristics of 415 Sicilian children. *BMC Infect Dis* 2006; 6:60.
5. Anton E, Font B, Munoz T *et al.* Clinical and laboratory characteristics of 144 patients with Mediterranean spotted fever. *Eur J Clin Microbiol Infect Dis* 2003; 22:126-8.
6. Carmo G, Caixeiro IS, Uva AS, Paiva JED. Febre escaro-nodular: actualização teórica e análise retrospectiva de 231 casos. *Rev Port Doenças Infecciosas* 1981; 4:13-25.
7. Sousa R, França A, Dória Nóbrega S *et al.* Host- and microbe-related risk factors for and pathophysiology of Fatal *Rickettsia conorii* Infection in Portuguese Patients. *J Infect Dis* 2008; 198(4):576-85.
8. Oliveira J, Côrte-Real R. Rickettsioses em Portugal. *Acta Med Port* 1999; 12:313-21.
9. Rovey C, Brouqui P, Raoult D. Questions on mediterranean spotted fever a century after its discovery. *Emerg Infect Dis* 2008; 14:1360-7.
10. Raoult D, Kohler JL, Gallais H *et al.* Fatal rickettsiosis. *Nouv Presse Med* 1982; 11:607.
11. Conor A, Bruch A. Une fièvre éruptive observée en Tunisie. *Bull Soc Pathol Exot Filiales* 1910; 8:8492-6.
12. Jorge R. La Fièvre exanthématique (Fièvre escharo-nodulaire) et son apparition au Portugal. *Jornal Lisboa Médica* 1930; 8:433-54.
13. Ruiz Beltran R, Herrero-Herrero JI, Martín-Sánchez AM. Formas graves de fiebre exantemática mediterránea. Análisis prospectivo de 71 enfermos. *Ann Med Interna* 1985; 2:365-8.
14. Sousa R, Dória Nóbrega S, Bacellar F, Torgal J. Sobre a realidade da febre escaro-nodular em Portugal. *Acta Med Port* 2003; 16:429-36.