



ELSEVIER

The Brazilian Journal of INFECTIOUS DISEASES

www.elsevier.com/locate/bjid


Letter to the Editor

Lymphocytic myocarditis at autopsy in patients with dengue fever

Dear Editor,

Cardiac involvement in dengue that is clinically relevant is rare, and seldom fatal.^{1,2} Dengue myocarditis is the presumed cause for cardiac symptoms, but is rarely diagnosed during life.³ In cases of sudden death due to myocarditis, however, the etiology is often unknown because of the difficulty in identifying infectious agents.⁴ There are only a few case reports of myocarditis in dengue, seldom with histologic documentation.³

All records from a state-wide autopsy and medical examiner system were retrospectively reviewed from 2010 through 2011. Cardiac findings were recorded and cardiomegaly was detected if the heart weight was >95% of the confidence interval for body height and weight. The presence of myocardial inflammation with necrosis was assessed microscopically. Myocarditis was defined as the presence of an inflammatory infiltrate with myocyte necrosis. Extent of myocarditis was evaluated semi-quantitatively. Statistical evaluation was done by JMP software (Cory, NC). Groups were compared by t test for continuous variables and by chi-squared for non-continuous variables.

There were a total of 44 post-mortem confirmed cases of dengue fever. There was histologically confirmed myocarditis in 8 cases (17%). Microscopically, focal myocarditis was present in 4 cases (less than 10% of inflammatory infiltrates, mainly lymphocytes with focal necrosis), with moderate extension in 2 cases (more than 10% of the examined tissue) more than 3 foci of inflammation with conspicuous necrosis, more than 10% of the examined tissue), and was diffuse in 2 cases

(virtually all fields involved by inflammation, with mixed infiltrates of lymphocytes, neutrophils and eosinophils). In the latter cases the infiltrates were mainly interstitial, but in some areas showed perivascular rich areas with one case showing prominent eosinophils. One case was associated with acute fibrinous pericarditis with hemorrhagic pericardial effusion (see Fig. 1).

The histologic appearance of myocarditis has been described in a few case reports in patients with serologic or molecular confirmation of the dengue. Cavalcanti et al. reported 2 cases of fatal myocarditis (10%) and 5 cases of myocarditis in patients that cleared the disease (1.9%). Obeyesekere and Hermon⁵ described 10 cases of dengue myocarditis and interestingly found that, while most patients had full recovery, at least 3 developed dilated cardiomyopathy later in life, a well known phenomenon in other types of myocarditis. These findings are in agreement with the current study, and may imply a rate of myocardial involvement in dengue higher than commonly reported.

The fact that dengue myocarditis presented suddenly in 4 of 6 confirmed cases raises an important issue in any endemic area. Sudden cardiac death due to myocarditis may be of public health importance and should be monitored accordingly. There is an urgent need to evaluate the cardiac function in all patients with acute dengue fever who may benefit from pharmacological therapy targeting cardiac function and may prevent cardiac death. It would also be interesting to correlate the serotype with the presence of inflammation in the myocardium and evaluate cardiac tropism of these types in a larger cohort.

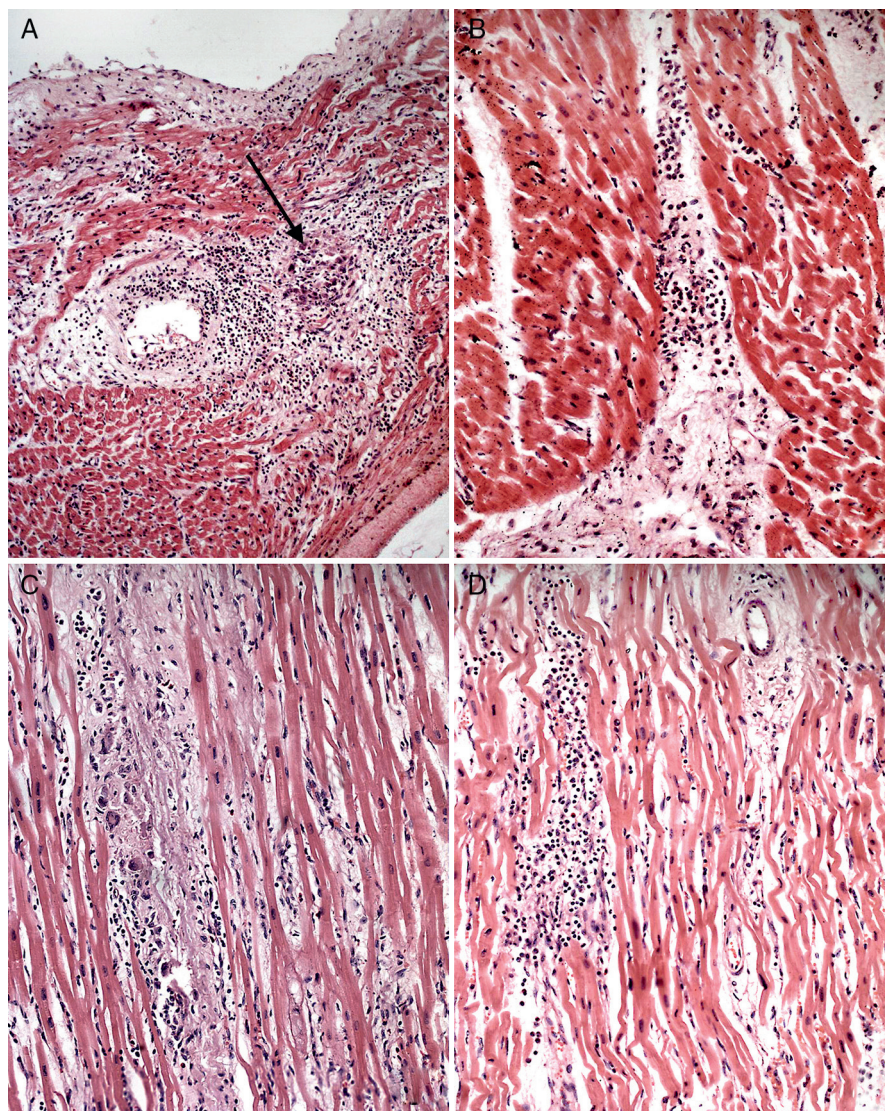


Fig. 1 - (A) Chronic inflammatory infiltrates with lymphocytic and eosinophilic predominance. There is an area of myocyte necrosis and mild interstitial scarring (arrow), (B) diffuse myocardial inflammatory infiltrates, mainly lymphocytes and scattered giant cells, (C) perivascular inflammation with associated endocardial fibrosis. There is myocyte necrosis and endothelial hyperplasia and (D) focal lymphocytic myocarditis. This focus and other foci were the only relevant findings in this case, raising the question of focal myocarditis as the cause of sudden death.

Conflict of interest

The authors declare no conflicts of interest.

REFERENCES

1. Cavalcanti LP, Vilar D, Souza-Santos R, Teixeira MG. Change in age pattern of persons with dengue, northeastern Brazil. *Emerg Infect Dis.* 2010;17:132-4.
2. Salgado DM, Panqueba CA, Castro D, R Vega M, Rodriguez JA. Myocarditis in children affected by dengue hemorrhagic fever in a teaching hospital in Colombia. *Rev Salud Publica (Bogota).* 2009;11:591-600.
3. Weerakoon KG, Kularatne SA, Edussuriya DH, et al. Histopathological diagnosis of myocarditis in a dengue outbreak in Sri Lanka, 2009. *BMC Res Notes.* 2011;4:268.
4. Tavora F, Gonzalez-Cuyar LF, Dalal JS, et al. Fatal parvoviral myocarditis: a case report and review of literature. *Diagn Pathol.* 2008;3:21.
5. Obeyesekere I, Hermon Y. Myocarditis and cardiomyopathy after arbovirus infections (dengue and chikungunya fever). *Br Heart J.* 1972;34:821-7.

Alba Fabiola Torres^a, Deborah Nunes Braga^{b,c},
Felipe Muniz^b, Cindy Mendonça^b, Denise Nunes Oliveira^c,
Emilia Tome de Souza^{b,c}, Allen Burke^d,
Fabio Tavora^{a,b,*}

^a Argos Laboratory, Fortaleza, CE, Brazil

^b Department of Pathology, Universidade Federal do Ceará (UFCE), Fortaleza, CE, Brazil

^c Coroner Office Dr. Rocha Furtado, State Health Secretariat of Ceara, Fortaleza, CE, Brazil

^d University of Maryland, Baltimore, MD, USA

* Corresponding author at: Department of Pathology, Universidade Federal do Ceará, Fortaleza, CE, Brazil.

E-mail address: ftavora@gmail.com (F. Tavora).

Received 20 February 2013

Accepted 27 March 2013

Available online 3 August 2013

1413-8670/\$ – see front matter

© 2013 Elsevier Editora Ltda. All rights reserved.

<http://dx.doi.org/10.1016/j.bjid.2013.03.009>