

PCR identification of *Mycobacterium tuberculosis* complex in a clinical sample from a patient with symptoms of tuberculous spondylodiscitis

M.A. Ribeiro¹,
A.S. Barouni^{3,4},
C.J. Augusto³,
M.V.S. Augusto²,
M.T.P. Lopes⁴
and C.E. Salas⁴

¹Hospital Maria Amélia Lins, ²Hospital Eduardo de Menezes, Fundação Hospitalar de Minas Gerais, Belo Horizonte, MG, Brasil
³Fundação Ezequiel Dias, Laboratório Central de Saúde Pública de Minas Gerais, Belo Horizonte, MG, Brasil
⁴Departamento de Bioquímica e Imunologia, Instituto de Ciências Biológicas, Universidade Federal de Minas Gerais, Belo Horizonte, MG, Brasil

Abstract

A 42-year-old male complaining of thoracic spine pain was admitted to the hospital for evaluation. An X-ray and computer tomography of the thoracic spine showed spondylodiscitis of the L3 lumbar and L2-L3 intervertebral disk. The tuberculin skin test (PPD) was strongly positive. A radioscopy-guided fine needle aspirate of the affected area was cultured but did not reveal the cause of the disease. Two biopsy attempts failed to reveal the cause of the disease by culturing or by acid-fast-resistant staining (Ziehl Neelsen) of the specimens. A third biopsy also failed to detect the infectious agent by using microbiological procedures, but revealed the presence of a 245-bp amplicon characteristic of the *Mycobacterium tuberculosis* complex after PCR of the sample. The result demonstrates the efficacy of PCR for the identification of *M. tuberculosis* in situations in which conventional diagnosis by culturing techniques or direct microscopy is unable to detect the microorganism. Following this result the patient was treated with the antituberculous cocktail composed by rifampicin, pirazinamide and isoniazid during a six-month period. At the end of the treatment the dorsalgia symptoms had disappeared.

Key words

- Spondylodiscitis
- Tuberculosis
- Polymerase chain reaction
- *Mycobacterium tuberculosis* complex

Correspondence

C.E. Salas
Departamento de Bioquímica
e Imunologia
ICB, UFMG,
Av. Antônio Carlos, 6627
31270-901 Belo Horizonte, MG
Brasil
Fax: +55-31-3499-2646
E-mail: cesbufmg@mono.icb.ufmg.br

Received March 13, 2006
Accepted August 29, 2006

Spondylodiscitis is a rare inflammatory disorder of the intervertebral discs and the adjacent vertebral bodies. In 25 to 33% of cases, spondylodiscitis is associated with an epidural abscess (1,2). Spondylodiscitis may occur spontaneously or as a result of spinal surgery. Patients with diabetes mellitus, lung or systemic infection, drug abuse, chronic renal failure, alcoholism, malignancy, and those undergoing dialysis, transplantations,

or whose immune system is depressed are more frequently affected. Microbial agents that most frequently cause spondylodiscitis are *Staphylococcus*, *Brucella*, *Salmonella*, and *Mycobacterium tuberculosis*, but many other microorganisms have also been shown to be associated with this condition (3,4).

Tuberculosis (TB) is endemic in most developing countries. However, a resurgence of TB has also been reported in the past

decades in developed countries, not only affecting the lungs, but also extrapulmonary sites, e.g., the vertebral column.

The oldest record of vertebral TB dates back to the pre-dynastic Egyptian era, 5400 BC (5). Vertebral TB is most often found in the lower thoracic and upper lumbar regions. Its early detection is of major importance since TB kills more than any other infectious disease (6). Nonpulmonary osteoarticular TB represents about 10% of all cases, the spine being the most frequent target (7). Diagnosis of nonpulmonary TB is often difficult; clinical findings are usually not-specific and radiological features may mimic those of other bacterial, fungal, inflammatory, and neoplastic diseases.

Although a presumptive diagnosis of vertebral TB can be made based on patient history and/or clinical and radiological information, the final diagnosis depends on bacterial identification by culture or acid-fast staining.

However, recognition and understanding of the radiological findings may help with the diagnosis. Two distinct patterns of vertebral TB may be observed: the classic finding of spondylodiscitis, characterized by destruction of two or more contiguous vertebral opposed end plates and disk infection. The second pattern, increasing in frequency, is an atypical form of spondylitis without disk involvement. A positive culture or histopathologic analysis of computed tomography-guided needle aspiration or biopsy specimens is required in the absence of pulmonary manifestations of TB for a definitive diagnosis and adequate treatment. A persistent and even invasive diagnostic work-up is needed for the proper and prompt management of these patients. Even then, percutaneous approaches to obtain material from the area with the infection have a sensitivity of 72%, though specificity reaches 94% (8). Direct examination of smears for acid-fast bacilli is the most rapid method for the detection of mycobacteria, but it lacks speci-

ficity and requires a relatively large number of microorganisms in the specimen to be analyzed. The alternative culturing procedure is time consuming and requires about one month to identify the presence of bacilli.

On the basis of our experience identifying *M. tuberculosis* (9), we successfully applied the polymerase chain reaction (PCR) to characterize the bacteria in this clinical situation.

A 42-year-old male was admitted to the hospital on October 29th, 2004, with symptoms of acute dorsalgia and irradiation to the lower limbs. The patient reported weight loss and absence of fever episodes or other complaints. His past medical history was negative for TB but the patient admitted being an injectable drug user between 1980 and 1990. Clinical examination confirmed the lumbar pain during palpation and the absence of evident neurological alterations.

The X-ray of the lumbar spine showed partial destruction of L2-L3 and narrowing of the disc interspace (Figure 1). Computer tomography of the lumbar spine confirmed the damage to L2-L3 compromising the vertebral body (Figure 1). The tuberculin skin test (PPD) was strongly positive (15 mm) and serum was negative for HIV.

The secretion obtained on November 26, 2004 from a percutaneous biopsy at L2-L3 did not show granulomas, necrosis or neoplastic cells nor did it yield bacteria following culture assay. The acid-fast stain test was also negative.

A second open biopsy performed three weeks later produced a similar negative result. A third percutaneous biopsy obtained on January 14, 2005 from the right latero-posterior body of L3 and the L2-L3 junction resulted in the absence of bacterial colonies after culturing in Lowenstein Jensen medium (Difco, Le Port de Claix, France) and a negative reaction following Ziehl-Neelsen staining. However, PCR applied directly to the specimen using IS6110 primers produced a 245-bp amplicon (10) featured by the *M. tuberculosis* complex

(Figure 2). The sample was amplified in a 25- μ L reaction mixture containing 50 mM KCl, 10 mM Tris-HCl, pH 8.3, 1.5 MgCl₂, 0.01% gelatin, 0.2 mM each dNTP (Invitrogen Life Technologies, Carlsbad, CA), 1.5 U Taq polymerase (Amersham Bioscience, Buckinghamshire, UK), and 30 pmol of each primer INS1-INS2 (Invitrogen). The reaction was subjected to amplification using the following program: 5 min initial denaturation at 95°C, followed by 35 cycles (each cycle was 95°C for 1 min; 68°C for 1 min; 72°C for 1 min) and 10 min extension at 72°C in an MJ thermocycler. Five microliters of PCR was electrophoresed on a 6% PAGE in buffer containing 82 mM Tris-HCl, pH 7.5, 89 mM borate and 2 mM EDTA for 1 h at 150 V at room temperature and stained with silver nitrate. Control experiments without DNA added to the reaction mix did not show amplification. Following this result, antibiotic therapy was initiated with isoniazid, rifampin and pyrazinamide for 2 months followed by isoniazid and rifampin for 4 months. After 6 months, the patient showed a marked improvement of symptoms.

The failure of microbiology to detect and identify the infectious agent after successive attempts to inoculate samples removed from the infected area is noteworthy. A similar situation was recently described by Rafailidis et al. (11) for a case of multidrug-resistant tuberculous spondylodiscitis. Although prior studies (12,13) have shown that PCR is an efficient tool to confirm a diagnosis of tuberculous spondylodiscitis, we are not aware of any report describing the failure to detect the

infectious agent by the traditional microbiological or acid-fast procedures, leaving PCR as the only alternative. We conclude that PCR remains a valuable option for rapid identification of the *M. tuberculosis* complex when other microbiological procedures fail and the clinical symptoms suggest the presence of the microorganism.

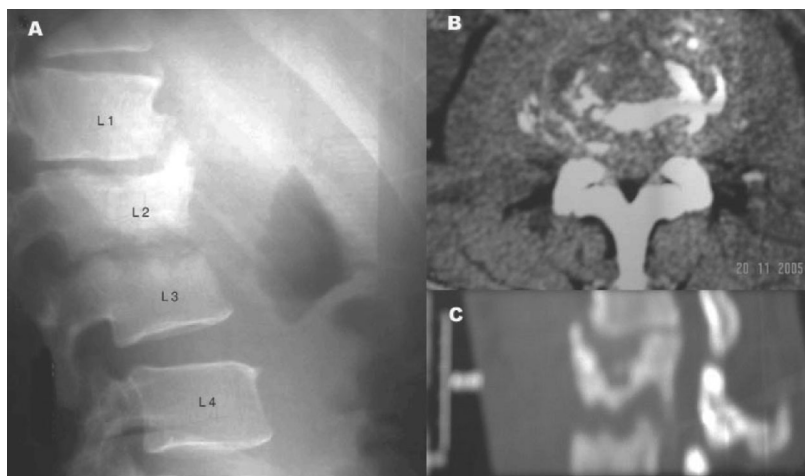
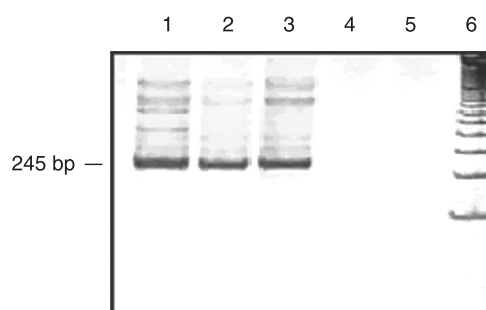


Figure 1. A, Lumbar X-ray destruction of adjacent vertebral bodies (L2-L3) and the intervening disk. B and C, Computed tomography showing disruption of vertebral bodies (L2-L3).

Figure 2. Detection of *Mycobacterium tuberculosis* complex in clinical samples by PCR amplification with IS6110 primers. The amplicons were analyzed by 6% PAGE and silver stained. Lane 1, Secretion aspirate; lane 2, bone fragment; lane 3, *M. tuberculosis* H37Rv-positive control; lane 4, negative control for sample DNA extraction; lane 5, PCR minus DNA (negative control); lane 6, 100-bp DNA standard.



References

1. Kapeller P, Fazekas F, Krametter D, Koch M, Roob G, Schmidt R, et al. Pyogenic infectious spondylitis: clinical, laboratory and MRI features. *Eur Neurol* 1997; 38: 94-98.
2. Maiuri F, Iaconetta G, Gallicchio B, Manto A, Briganti F. Spondylodiscitis. Clinical and magnetic resonance diagnosis. *Spine* 1997; 22: 1741-1746.
3. Mackenzie AR, Laing RB, Smith CC, Kaar GF, Smith FW. Spinal epidural abscess: the importance of early diagnosis and treatment. *J Neurol Neurosurg Psychiatry* 1998; 65: 209-212.
4. Weber U, Morf MH, Gubler JG, Altwegg M, Maibach RC. Spondylodiscitis as the first manifestation of Whipple's disease - a removal worker with chronic low back pain. *Clin Rheumatol* 2003; 22: 443-446.
5. Crubezy E, Ludes B, Poveda JD, Clayton J, Crouau-Roy B, Montagnon D. Identification of *Mycobacterium* DNA in an Egyptian Pott's disease of 5,400 years old. *C R Acad Sci III* 1998; 321: 941-951.

6. WHO (World Health Organization). *Tuberculosis, a global emergency*. Geneva: WHO report on the TB epidemic; 1994.
7. Stuart D. Local osteo-articular tuberculosis complicating closed fractures: report of two cases. *J Bone Joint Surg Br* 1976; 58: 248-249.
8. Fouquet B, Goupille P, Gobert F, Cotty P, Roulot B, Valat JP. Infectious discitis diagnostic contribution of laboratory tests and percutaneous discovertebral biopsy. *Rev Rhum Engl Ed* 1996; 63: 24-29.
9. Barouni AS, Augusto C, Queiroz MV, Lopes MT, Zanini MS, Salas CE. BCG lymphadenopathy detected in a BCG-vaccinated infant. *Braz J Med Biol Res* 2004; 37: 697-700.
10. van Embden JD, Cave MD, Crawford JT, Dale JW, Eisenach KD, Gicquel B, et al. Strain identification of *Mycobacterium tuberculosis* by DNA fingerprinting: recommendations for a standardized methodology. *J Clin Microbiol* 1993; 31: 406-409.
11. Rafailidis PI, Avramopoulos I, Sapkas G, Falagas ME. Multidrug-resistant tuberculous spondylodiscitis: need for aggressive management and drug susceptibility testing of *Mycobacterium tuberculosis* isolates. *J Infect* 2006; 52: e35-e37.
12. Cabral MML, Azevedo BCCA, Montenegro LML, Montenegro RA, Lima AS, Schindle HC. Espondilite tuberculosa em adolescente. *J Bras Pneumol* 2005; 31: 261-264.
13. Wang JY, Lee LN, Chou CS, Huang CY, Wang SK, Lai HC, et al. Performance assessment of a nested-PCR assay (the RAPID BAP-MTB) and the BD ProbeTec ET system for detection of *Mycobacterium tuberculosis* in clinical specimens. *J Clin Microbiol* 2004; 42: 4599-4603.