

Trachoma among the Yanomami Indians

J.S. Paula¹,
N.H. Medina² and
A.A.V. Cruz¹

¹Departamento de Oftalmologia, Otorrinolaringologia e Cirurgia de Cabeça e Pescoço, Faculdade de Medicina de Ribeirão Preto, Universidade de São Paulo, Ribeirão Preto, SP, Brasil

²Serviço Sanitário de Oftalmologia, Centro de Vigilância Epidemiológica, Secretaria da Saúde do Estado de São Paulo, São Paulo, SP, Brasil

Abstract

The Yanomami are one of the last primitive groups of Indians living in Brazil. They have almost no contact with other cultures. The epidemiology of eye disease among Yanomami is virtually unknown. For the first time, a trachoma survey was conducted among Yanomami Indians in the State of Amazonas near the Venezuelan border of the Brazilian rain forest. Ophthalmic examination was carried out on a total of 613 individuals (338 males and 275 females) from eight Yanomami villages along the Marauá River located in the upper Rio Negro Basin. Age was classified into three categories (children, adults, and elderly) and trachoma was classified into five grades: follicular, inflammatory intense, cicatricial, trichiasis, and corneal opacity. Trachoma was endemic in all villages visited. Overall, 30.3% of the subjects had trachoma. Females were significantly more affected (37.4%) than males (23.9%). The inflammatory trachoma rate reached 24.9% in children and the cicatricial form increased with age, reaching 13.9% among adults and 35.21% among the elderly. Trichiasis or corneal opacities were not detected and treatment of the entire population was initiated with 1 g azithromycin. The detection of endemic trachoma among the Yanomami is relevant for the understanding of the epidemiology of this disease in the Brazilian rain forest and underscores the necessity for a program of trachoma control in this region.

Key words

- Trachoma
- Yanomami
- Epidemiology

Correspondence

A.A.V. Cruz
Departamento de Oftalmologia,
Otorrinolaringologia e Cirurgia
de Cabeça e Pescoço
Hospital das Clínicas, FMRP, USP
Av. Bandeirantes, 3900
14049-900 Ribeirão Preto, SP
Brasil
E-mail: aaveacruz@fmrp.usp.br

Research supported by SECOYA,
a non-governmental organization
devoted to Yanomami health.
Publication supported by FAPESP.

Received March 27, 2002

Accepted July 26, 2002

Introduction

The Yanomami are hunter-farmer Indians that live within the South American tropical forest as aboriginals, with autonomous culture and economy. They are divided into four different groups according to linguistic divisions (Yanomam, Yanomami, Yanam and Sanima) (1) and occupy a vast territory in one of the most remote regions of the Ama-

zon rain forest along the borders between Brazil and Venezuela. In Brazil, these Amerindians comprise about 9,400 individuals scattered throughout an area of 9.4 million hectares (2).

The Yanomami remained isolated for millennia. Sporadic contacts with European explorers occurred two centuries ago, but a sustained interaction with outsiders only took place during the 1960's when missionaries

started working in their territory (3). During the seventies, the Brazilian military government launched the so-called National Integration Plan, which included the construction of a road along the northern borders of Brazil. This fact plus the discovery of gold in the eighties attracted 30,000-40,000 non-Indians to the Yanomami territory, with profound consequences for the local indigenous population (1).

The continuous social and cultural process of Yanomami assimilation has led to a progressive reduction in the quality and quantity of food consumption, to water contamination and poorer sanitation of the Indian communities (4). Even though there are scattered reports of gripe, pneumonia, malaria, tuberculosis, acute conjunctivitis, trauma, dermatological and urinary diseases (5), the whole spectrum of health problems among the Yanomami has not been fully assessed.

In this article we report for the first time that a leading cause of blindness in the world, trachoma, is threatening the eye conditions

of the Brazilian Yanomami located along the Marauíá River in the north of the Amazonas State of Brazil.

Material and Methods

Study area and population

In August 2000, a cross-sectional trachoma survey was carried out among Yanomami Indians inhabiting the rain forest along the Marauíá River on the left bank of the Rio Negro in the State of Amazonas, Brazil. This research was organized by the non-governmental organization SECOYA, which provides medical assistance to the Marauíá River Yanomami. The study area is delimited by longitudes 61° and 66° and latitudes 00° and 04° (Figure 1). It is heavily forested, with temperature ranging from 22° to 30°C. These Yanomami live along the border between Venezuela and Brazil in semi-permanent villages that are separated by a half- to five-day walk from each other. Eight villages were visited. Table 1 shows their names, estimated population and number of subjects examined.

Study design

Due to the lack of any previous information about the disease in this population, the use of a sampling methodology was not feasible. During each visit the examiner tried to assess the entire population. The discrepancy between the number of people who were supposed to live in each community and the number of subjects examined is explained by the high mobility of the population, which often travels for hunting or social purposes.

All examinations were performed under natural light with 2.5X magnifiers according to the classification system recommended by the World Health Organization (WHO), which classifies trachoma into five grades: trachomatous inflammation-follicular or TF

Figure 1. Location of the Yanomami villages along the Marauíá River.

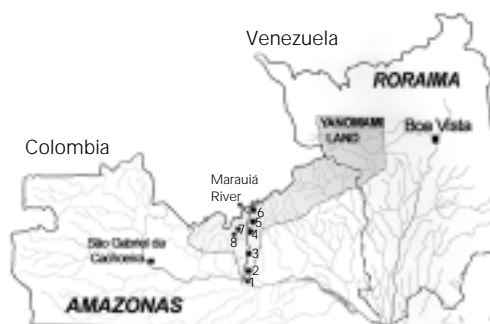

Table 1. Distribution of Yanomami Indians as a function of village, estimated and examined population.

Village	Estimated population	Number examined	Percentage (%)
Ixima	141	109	77.3
Pukima	130	107	82.3
Raita	54	30	55.6
Kona	122	82	67.2
Xamata	137	48	35.0
Pohoroa	336	168	50.0
Irapajé	63	49	77.8
Bixo-Mirim	20	20	100.0
Total	1003	613	61.1

(presence of five or more follicles - 0.5 mm or greater in diameter - in the central upper tarsal conjunctiva), trachomatous inflammation-intense or TI (pronounced inflammatory thickening of the upper tarsal conjunctiva that obscures more than half of the normal deep tarsal vessels), trachomatous scarring (cicatricial) or TS (easily visible scarring in the upper tarsal conjunctiva), trachomatous trichiasis or TT (at least one eyelash rubs on the eyeball, or evidence of eyelash removal), and corneal opacity or CO (easily visible corneal opacity over the pupil) (6). Since age was not determined in any of the eight villages, this variable was classified into three levels: children, adults and elderly. Ocular discharge was evaluated and classified as serous, mucoid, purulent or absent. Facial cleanness was categorized as good (clean) or poor (dirty).

Results

Trachoma was found in all communities visited. Overall, 30.3% (186/613) of the subjects had trachoma (Figure 2). Figure 3A and 3B show typical cases of TF and TS. Females were significantly more affected (37.4%) than males (23.9%) ($\chi^2 = 12.5$, $P = 0.0004$) (Figure 4). The inflammatory trachoma (TF + TI) rate reached 24.9% among children. TS increased with age, reaching 13.9% among adults and 35.2% among the elderly (Figure 5). TT and CO were not detected in any age group.

Ocular discharge was observed in a few individuals, of whom 1.1% had serous secretion and 8.0% mucoid secretion. No purulent discharge was found. Overall, 89.8% of the subjects were classified as having clean faces.

Discussion

The epidemiology of eye diseases among the Yanomami is virtually unknown and it was thought that they were at risk of only

acquiring onchocerciasis (7). Recent reports of hyperendemic trachoma in some Amazon areas close to Yanomami territory attracted our attention to this population. The data we have collected show that our suspicions were correct and the Marauíá River Yanomami indeed have a high rate of trachoma infection, about 30%, comparable to other endemic regions in the Amazon State (8).

Probably because of their close contact with children, women were significantly more

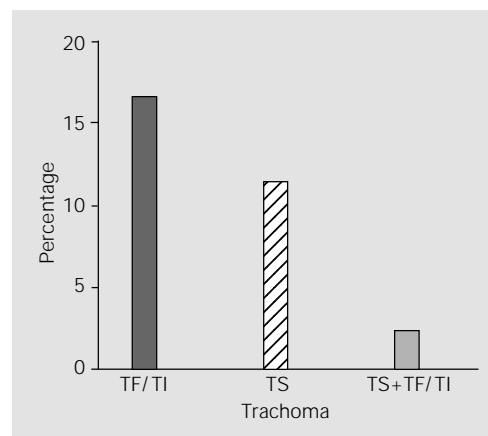


Figure 2. Trachoma among Yanomami Indians living along the Marauíá River. TF/TI = trachomatous inflammation-follicular/trachomatous inflammation-intense; TS = trachomatous scarring.

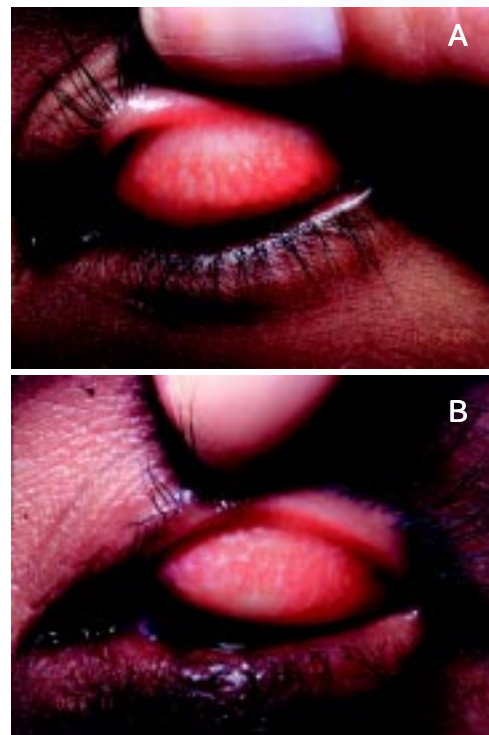


Figure 3. Trachoma in Yanomami Indians. A, Follicular trachoma in a child. B, Cicatricial trachoma in an adult.

affected than men, a classical finding that has been already reported for other endemic regions (9). The high rate of TS among the elderly (35.21%) indicates that the disease hit the community a long time ago and the high prevalence of TF + TI among children (24.9%) indicates a continuous state of infection. Finally, the coexistence of active and cicatricial forms in 4.5% of the adults and 1.4% of the elderly indicates that reinfection is occurring naturally in the community.

The spatial organization of the Yanomami society facilitates the spread of acute forms and thus explains the perpetuation of the infection within the community. In fact, Yanomami live in villages of 20-400 inhabitants occupying a single ring-like communal shelter with no walls or internal partitions, called “shabono”. This type of living condition is an ideal situation for the circula-

tion of *Chlamydia trachomatis*. However, despite the high prevalence of the disease, no cases of TT or CO were found, leading us to conclude that trachoma is not provoking blindness among the Marauíá Rivers Yanomami.

We think that the relative mildness of some characteristics of this endemic disease can be explained by Yanomami sociocultural habits. Poor facial cleanness is rare and the vast majority of the examined subjects (89.8%) were classified as having clean faces. Their hygiene habits include frequent baths in the nearby rivers and, in addition, missionary and non-governmental organizations are upgrading their level of hygiene. In some villages they are brushing their teeth.

The detection of a high frequency of trachoma among them is relevant to the understanding of the epidemiology of this disease in the Brazilian rain forest and also underscores the necessity for an aggressive trachoma control program in this region. The Yanomami territory borders the so-called upper Rio Negro area, a huge territory occupied since ancient times by Maku, Tukano and Arawak Indians. These Indians (especially Tukanos and Arawaks) have a long history of contact with the white society which dates back to the seventeenth century when Portuguese troops moved up into the Rio Negro. As we have already reported, trachoma is endemic in the whole area of the upper Rio Negro and its prevalence reaches high levels in some Maku communities (8). Since some Yanomami from the Marauíá River often travel to the capital of the upper Rio Negro district (São Gabriel da Cachoeira city), it seems reasonable to suppose that trachoma entered the Yanomami territory through their interaction with other Indians from the upper Rio Negro. This hypothesis is supported by the fact that in São Gabriel the Yanomami eventually stay in a housing facility provided by local authorities, called the “Indian house”. In this place all Indians live together in the same space.

Figure 4. Distribution of trachoma in Yanomami Indians of the Marauíá River according to sex.

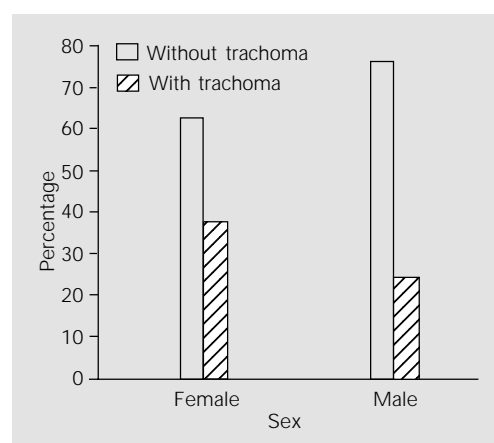
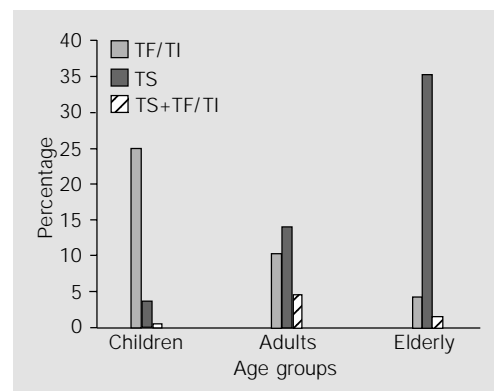


Figure 5. Distribution of forms of trachoma in Yanomami Indians of the Marauíá River according to age. TF/TI = trachomatous inflammation-follicular/trachomatous inflammation-intense; TS = trachomatous scarring.



In order to control trachoma among the Yanomami, we tried to adapt the so-called SAFE strategy, as suggested by the WHO, to the local and cultural conditions. The SAFE strategy is based on surgery for any case of trichiasis/entropion (S), antibiotics (A), facial hygiene (F), and environmental changes (E) (10). For the Yanomami, surgery and improvement of facial cleanness were not necessary and environmental changes were not feasible. So, we decided to treat the whole population with a single dose of 1 g

azithromycin. This campaign was carried out by the SECOYA personnel but the results of this mass treatment have not yet been assessed.

We think that the social conditions of Yanomami Indians must be followed carefully. The relationship between poor social conditions and worsening of trachoma is well known. We believe that if the social conditions of Yanomami Indians deteriorate, blindness from trachoma will ensue. This is an endangered population.

References

1. Albert B & Gomez GG (1997). Saúde Yanomami: Um Manual Etnolingüístico. 1st edn. Museu Paraense Emílio Goeldi, Belém, PA, Brazil.
2. Distrito Sanitário Yanomami, Roraima (1995). População Yanomami por Pólo-Base e Comunidades. Report of DSY/RR - Fundação Nacional de Saúde, Boa Vista, RR, Brazil.
3. Smole WJ (1976). The Yanoama Indians: A Cultural Geography. Vol. 2. The Texas Pan American Series. 1st edn. University of Texas Press, Austin, TX, USA, 7-17.
4. Perez Mato S (1998). Anemia and malaria in a Yanomami Amerindian population from the southern Venezuelan Amazon. *American Journal of Tropical Medicine and Hygiene*, 59: 998-1001.
5. Francisco DA & Oliveira CE (1996). VII Relatório de Atividades de Saúde na Área Yanomami. Report of Comissão Pró-Yanomami, Fundação Nacional de Saúde, Roraima, Brazil (unpublished document).
6. Thylefors B, Dawson CR, Jones BR, West SK & Taylor HR (1987). A simplified system for the assessment of trachoma and its complications. *Bulletin of the World Health Organization*, 65: 477-483.
7. Vivas-Martinez S, Basanez MG, Botto C, Rojas S, Garcia M, Pacheco M & Curtis CF (2000). Amazonian onchocerciasis: parasitological profiles by host-age, sex and endemicity in southern Venezuela. *Parasitology*, 121 (Pt 5): 513-525.
8. Alves APX, Medina NH & Cruz AAV (2002). Trachoma and ethnic diversity in the Upper Rio Negro Basin of Amazonas State, Brazil. *Ophthalmic Epidemiology*, 9: 29-34.
9. Tielsch JM, West Jr KP, Katz J, Keyvan-Larijani E, Tizazu T, Schwab L, Johnson GJ, Chirambo MC & Taylor HR (1988). The epidemiology of trachoma in southern Malawi. *American Journal of Tropical Medicine and Hygiene*, 38: 393-399.
10. Cook JA (1999). Trachoma and the SAFE strategy. *Community Eye Health*, 12: 51-53.