

Community-based transconjunctival marginal rotation for cicatricial trachoma in Indians from the Upper Rio Negro basin

O.E. Soares¹ and
A.A.V. Cruz²

¹Federação das Organizações dos Índios do Rio Negro, São Gabriel da Cachoeira, AM, Brasil

²Departamento de Oftalmologia, Otorrinolaringologia e Cirurgia de Cabeça e Pescoço, Faculdade de Medicina de Ribeirão Preto, Universidade de São Paulo, Ribeirão Preto, SP, Brasil

Abstract

The objective of the present study was to describe, for the first time in Brazil, the use by a non-ophthalmologist of a community-based marginal rotation procedure by a posterior approach in the indigenous population from the Upper Rio Negro basin. Seventy-three upper eyelids of 46 Indians (11 males and 35 females) with cicatricial upper eyelid entropion and trichiasis were operated in the Indian communities using a marginal rotational procedure by a posterior approach by a non-ophthalmologist physician who had general surgery experience but only an extremely short period (one week) of ophthalmic training. Subjects were reevaluated 6 months after surgery. Results were classified according to the presence and location of residual trichiasis and symptoms were assessed according to a three-level subjective scale (better, worse or no change). Fifty-six eyelids (76.7%) were free from trichiasis, whereas residual trichiasis was observed in 17 eyelids (23.3%) of 10 subjects. In these cases, trichiasis was either lateral or medial to the central portion of the lid. Of these 10 patients, only 4 reported that the surgery did not improve the irritative symptoms. We conclude that marginal rotation by a posterior approach is an effective and simple procedure with few complications, even when performed by non-specialists. Due to its simplicity the posterior approach is an excellent option for community-based upper eyelid entropion surgery.

Key words

- Trachoma
- Community-based surgery
- Marginal rotation
- Trichiasis
- Entropion

Correspondence

A.A.V. Cruz
Departamento de Oftalmologia,
Otorrinolaringologia e Cirurgia de
Cabeça e Pescoço, FMRP, USP
Av. Bandeirantes, 3900
14049-900 Ribeirão Preto, SP
Brasil
E-mail: aavecruz@fmrp.usp.br

Publication supported by FAPESP.

Received May 27, 2003

Accepted January 9, 2004

Introduction

Trachoma continues to be a leading cause of preventable blindness in some regions of developing countries. Since blindness results from corneal damage caused by chronic entropion and trichiasis, eyelid surgery is an essential measure in programs for the elimi-

nation of trachoma (1).

Most patients who need surgery live in endemic regions which are often located in remote rural areas. In order to have access to surgery, these patients need to be operated upon in their communities. The community-based surgery strategy has been strongly supported by the WHO and in 1993 a surgical

procedure manual was published advocating the use of marginal rotation by an anterior approach as the standard procedure to be performed in community-based programs (2).

We report our experience in correcting upper eyelid trichomatous entropion with a marginal rotational procedure by a posterior approach by a non-ophthalmologist physician in two Indian communities in the Upper Rio Negro basin, and discuss the use of this technique as an option for community-based surgeries.

Material and Methods

From October 2000 to September 2002, 73 upper eyelids of 46 Indians (11 males and 35 females) with cicatricial upper eyelid entropion and trichiasis were operated in the communities along the Rivers Tiquié and Papuri. Both rivers belong to the Upper Rio Negro basin, an extremely hot and humid region, located between 70° 20' and 64° 40' W longitude and 1° 45' S and 2° and 15' N latitude in the northwest of the Amazonas State in Brazil. The hygiene level of the communities was poor, with a high insect population. Thirty-nine Indians belonged to the Hüpde (N = 36) and Dãw (N = 3) groups of the Maku language division and only 7 belonged to the Tukano division. Since age is not measured by the Indians of this study, they were classified into three age levels: children (N = 1), adults (N = 25) and elderly subjects (N = 20). Fifteen Indians (32.6%) had corneal opacities.

All surgeries were performed by the same non-ophthalmologist physician (O.E.S.) who had previous experience with general surgery but virtually none with ophthalmic procedures. He had been working with the Maku Indians for three years and was well accepted by them. His only training in eyelid surgery consisted of a period of one week attendance at the Oculoplastic Service at the University Hospital of the Faculty of Medicine of Ribeirão Preto, University of São

Paulo. During this period he performed 6 transconjunctival marginal rotations under supervision.

Surgical technique

The operation is essentially a marginal rotation by a posterior approach. This surgery is an old and effective procedure that has been well described by several surgeons (3-6).

Briefly, the eyelid is infiltrated in the subcutaneous pretarsal area with adequate amounts of local anesthetic. The lid is then everted over a cotton-tipped applicator and held in position with a lid traction suture. Using a number 15 scalpel blade, a curvilinear incision parallel to the lid margin is made 2 to 3 mm from the lid margin through the conjunctiva and tarsal plate, transecting the tarsal plate into a marginal portion and a distal portion. During this incision, care is taken to avoid injuring the overlying orbicularis muscle. As the tarsus is avascular, the only sources of bleeding are the conjunctival vessels. Usually, the amount of bleeding is minimal and easily controlled with compression maneuvers. Next, the two portions of the incised tarsus are carefully freed from the overlying orbicularis muscle with Westcott scissors.

Three mattress (4-0 silk or nylon) sutures were then applied in the following manner. Double-armed or single-armed sutures can be used. In the present study only single-armed sutures were available. The middle suture was inserted at the center of the lid, entering the anterior lamella, just behind the lash line, passing under the marginal tarsal portion and emerging in the defect created by the incision (Figure 1A). The needle was next passed through the distal tarsal portion and passed back under the marginal tarsal segment emerging at the anterior lamella (Figure 1B,C). Two additional sutures were placed in the same way 4 to 5 mm laterally and medially to the central suture in a radial

direction (Figure 1D). As the sutures are tied, the marginal tarsal portion is rotated outwards causing the lashes to evert. The amount of correction is adjusted when tying the knots. A small amount of overcorrection exposing the entire posterior border of the margin is desirable. Due to the local working conditions, the sutures were removed only 30 days after surgery. Compliance with topical medication was assured only for 48 h after surgery.

During the procedures, which typically lasted 10 min per eyelid, the operating field was protected with a mosquito net. An electrocautery was not available and thus never used in the surgeries. Sedation was applied only to the only child operated using ketamine (5 mg/kg, *im*).

All subjects were reevaluated 6 months after surgery. Results were classified according to the presence and location of residual trichiasis. Symptoms were assessed according to a three-level subjective scale (better, worse or no change). Any complication was also recorded. The study was approved by the Ethics Committee of the Federação das Organizações dos Índios do Rio Negro.

Results

The postoperative evaluation revealed that 56 eyelids (76.7%) were free from trichiasis, whereas residual trichiasis was observed in 17 eyelids (23.3%) of 10 patients. In these cases, trichiasis was either lateral or medial to the central portion of the lid. Of these 10 patients, only 4 reported that the surgery did not improve the irritative symptoms. All the remaining 42 patients reported that the symptoms improved after surgery. Figure 2 shows a typical successful marginal rotation achieved with the procedure. Figure 3 displays the dramatic change in the behavior of a subject after surgery with the elimination of the blepharospasm induced by the upper eyelid entropion. Complications such

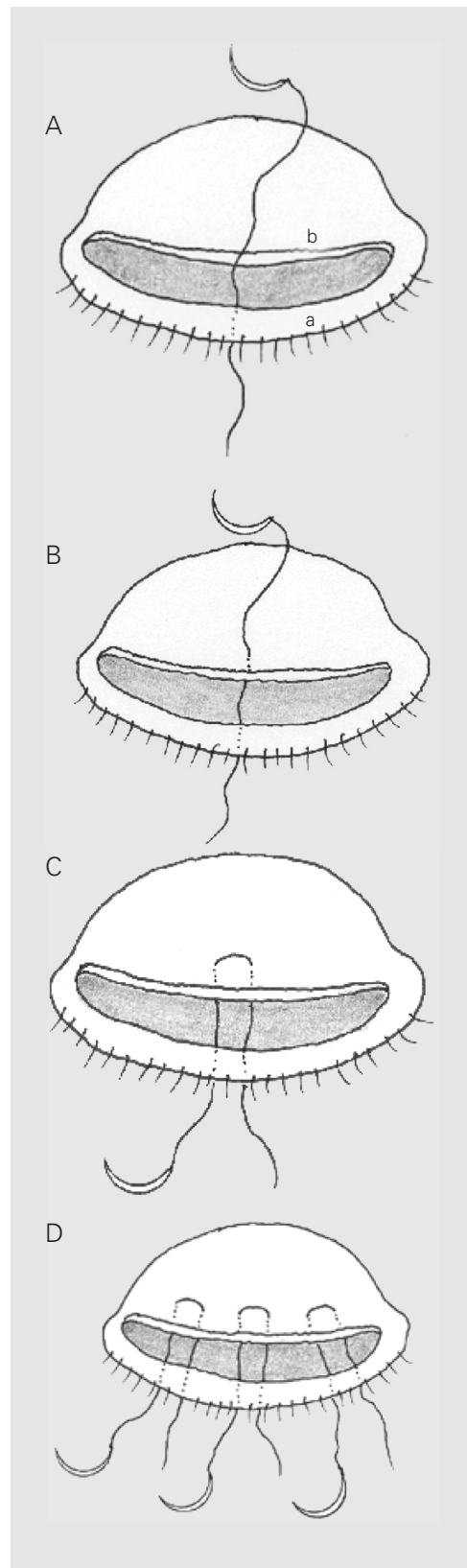


Figure 1. A, Surgeon's view: a curvilinear incision has divided the tarsal plate into two portions: marginal (a) and distal (b). A single-armed suture was inserted at the center of the lid through the anterior lamella, just behind the lash line, passed under the marginal tarsal portion and emerged in the defect created by the incision. B, The needle was next passed through the distal tarsal portion and passed back under the marginal portion emerging at the anterior lamella. C, Additional sutures are passed in the same manner laterally and medially. D, Final result: the distal tarsal portion (dotted line) is now over the marginal portion.

as defective closure or eyelid notching were not observed. One patient developed a bacterial conjunctivitis that was controlled with antibiotic drops.

Discussion

The main histopathologic finding in biopsies of tarsal plates of upper eyelids affected by cicatricial trachoma and trichiasis

is the replacement of the loose stroma of the tarsal conjunctiva with a subepithelial thick and fibrous membrane (7). This membrane is avascular, adherent to the tarsal plate and composed of vertically oriented fibers. The presence of this abnormal cicatricial tissue is the key factor causing the buckling of the tarsal plate and inward rotation of the lid margin towards the globe (entropion). Trachomatous trichiasis is, thus, essentially related to the entropion caused by cicatricial changes of the posterior eyelid lamella.

A wide variety of surgical procedures for outwards rotation of the upper eyelid margin have been described. In the setting of a specialized oculoplastic center, complex operations involving lid splitting, anterior lamella recession and grafting can be used (8-11). However, in community-based surgeries sophisticated procedures are not feasible and the focus must be directed at the simplest surgery capable of rotating the upper eyelid margin.

In order to overcome the rotational forces induced by the cicatricial changes of the posterior lamella, most rotational margin procedures combine a tarsal plate fracture with the use of sutures to reposition the tarsal fragment containing the lid margin away from the globe. These surgeries can be done by an anterior or posterior approach. In both cases, a full-thickness tarsotomy is the essential step.

The anterior approach was described in 1964 by Ballen (12) who applied it to the upper eyelid, but the procedure was originally described by Wies for the lower eyelid. A complete blepharotomy (incision of all layers of the lid: skin, orbicularis, tarsus and conjunctiva) needs to be made. This technique is recommended by the WHO and described in detail in the 1993 WHO manual (2).

The posterior approach is much simpler than the anterior approach because the incision is limited to the conjunctiva and tarsal plate. As the skin and orbicularis muscle are

Figure 2. Successful marginal rotation.

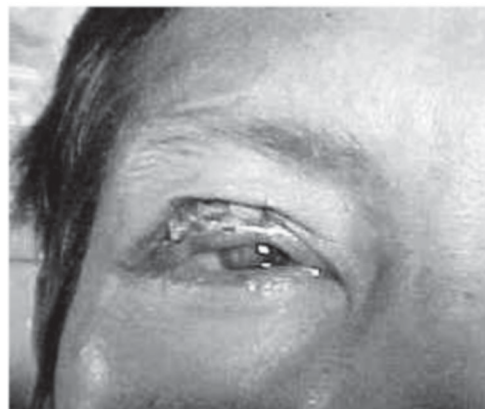
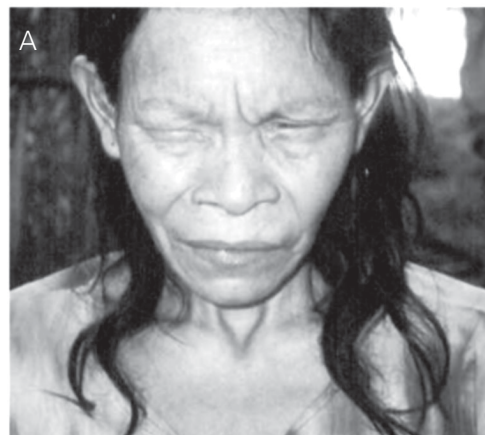
Figure 3. A, Blepharospasm induced by trachomatous entropion. B, Relief of blepharospasm after marginal rotation by a posterior approach.



not disturbed, bleeding is minimal. According to Kersten et al. (5), marginal rotation by a posterior approach has been used since the sixth century and different authors have already attested to the efficacy of this modality of marginal rotation for the treatment of trichomatous entropion and trichiasis (3,4,6).

It is not clear why the anterior approach was recommended by the WHO as the preferred technique to be used in community-based surgeries. First, as pointed out in the 1993 manual, surgery is directed towards the eye and care should be taken to avoid globe injury. Second, when the anterior lamella is opened, the lid may bleed profusely (2). These problems are minimized with the posterior approach. As the incision is placed on an everted lid, the surgery is done away from the globe and bleeding is not an issue because the posterior lamella is relatively avascular. We are aware of only one randomized trial comparing the anterior and posterior approaches for the treatment of trichomatous trichiasis in which it was concluded that both techniques had the same efficacy but fewer complications occurred when rotation was done by the posterior approach (13).

Our experience with tarsotomy by posterior approach was extremely positive. We have used this surgery in the hospital to manage any degree of trichomatous entropion. The results of the present study indicate that even with a minimal amount of training the surgeon was able to alleviate the symptoms of 91.3% of the subjects and 76.7% of the eyelids were free of trichiasis after a 6-month follow-up period.

Two points deserve comment when trichiasis recurrence is taken as a parameter of tarsal rotation effectiveness. The first is the location of the trichiasis. In our case, the recurrent misdirected eyelashes were always lateral or medial to the limbus and thus did not touch the cornea. Normally, this finding indicates that tarsotomy was not done across the entire extension of the tarsal plate. Another possibility is that the tarsal incision

was not parallel to the margin. In order to achieve a uniform degree of margin rotation, the tarsotomy must be performed in a curvilinear fashion, maintaining the same distance from the margin. If the incision is placed more posteriorly, the margin will not rotate properly. Any surgery has its own learning curve, and the presence of segmental trichiasis might suggest that the surgeon still needs some training with the tarsotomy. In any case, secondary surgery can then be performed in the segments (lateral, medial or both) that were not incised.

The second aspect is related to the differentiation between entropion and trichiasis. The WHO grading system is excellent for the epidemiological assessment of trachoma but does not measure the degree of eyelid inward rotation. Trichiasis is not necessarily associated with entropion. A typical example is leprosy, a disease that does not induce cicatricial changes in the eyelid posterior lamella. We have shown that a high percentage of leprosy patients with paralytic lagophthalmos and no conjunctival scarring have trichiasis (14). Trichiasis may also have undetermined causes, appearing as an idiopathic disorder (9,15). Marginal rotation procedures are aimed at rotating the lid margin. It is entirely possible that the surgery achieves its goal by producing a normal margin position even though trichiasis is still present.

Surgical compliance is definitely one of the main problems for the community-based strategy. Acceptance of surgery depends on economic and cultural factors that change from one community to another (16-20). The population operated upon here was composed mainly of Makus, one of the most primitive groups of Indians in the region (21). For the Makus, trachoma is not a real disease. They rather tend to consider their eye problems as a natural consequence of life. Disease is the medical intervention which causes a dramatic change in their body manifested by bleeding, edema and postoperative pain. We believe that the option we have

chosen for the least invasive procedure (tarsotomy by a posterior approach) was of paramount importance for the acceptance of surgery. Only when the community saw that the

first subjects being operated upon had virtually no complaints or complications was surgery well accepted.

References

- Bailey R & Lietman T (2001). The SAFE strategy for elimination of trachoma by 2020: will it work? *Bulletin of the World Health Organization*, 79: 233-236.
- Reacher M, Foster A & Huber J (1993). *Trichiasis Surgery for Trachoma. The Bilamellar Tarsal Rotation Procedure*. World Health Organization and the Edna McConnell Clark Foundation, New York.
- Carre JB (1972). Tratamiento del entropion y de la triquiasis por via conjuntival (técnica personal). *Archivos de la Sociedad Española de Oftalmología*, 32: 683-698.
- Nasr AM (1989). Eyelid complications in trachoma. I. Cicatricial entropion. *Ophthalmic Surgery*, 20: 800-807.
- Kersten RC, Kleiner FP & Kulvin DR (1992). Tarsotomy for the treatment of cicatricial entropion with trichiasis. *Archives of Ophthalmology*, 110: 714-717.
- Halasa AH & Jarudi N (1974). Tarsotomy for the correction of cicatricial entropion. *Annals of Ophthalmology*, 6: 837-840.
- Al-Rajhi AA, Hidayat A, Nasr A & Al-Faran M (1993). The histopathology and the mechanism of entropion in patients with trachoma. *Ophthalmology*, 100: 1293-1296.
- Lyon DB & Dortzbach RK (1994). Entropion, trichiasis, and distichiasis. In: Dortzbach RK (Editor), *Ophthalmic Plastic Surgery: Prevention and Management of Complications*. Raven Press, New York.
- Martin RT, Nunery WR & Tanenbaum M (1995). Entropion, trichiasis, and distichiasis. In: McCord Jr CD, Tanenbaum M & Nunery WR (Editors), *Oculoplastic Surgery*. 3rd edn. Raven Press, New York.
- Kemp EG & Collin JRO (1986). Surgical management of upper lid entropion. *British Journal of Ophthalmology*, 70: 575-579.
- Goldberg RA, Joshi AR, McCann JD & Shorr N (1999). Management of severe cicatricial entropion using shared mucosal grafts. *Archives of Ophthalmology*, 117: 1255-1259.
- Ballen PH (1964). A simple procedure for the relief of trichiasis and entropion of the upper lid. *Archives of Ophthalmology*, 72: 239-240.
- Adamu Y & Alemayehy W (2002). A randomized clinical trial of the success rates of bilamellar tarsal rotation and tarsotomy for upper eyelid trachomatous trichiasis. *Ethiopian Medical Journal*, 40: 107-114.
- Guimaraes FC & Cruz AAV (1998). Eyelid changes in long-standing leprosy. *Ophthalmic Plastic and Reconstructive Surgery*, 14: 239-243.
- Figueiredo ARP & Soares EJC (1992). Trichiasis: diagnosis and management. *Orbit*, 11: 137-146.
- West S, Lynch M, Munoz B, Katala S, Tobin S & Mmbaga BB (1994). Predicting surgical compliance in a cohort of women with trichiasis. *International Ophthalmology*, 18: 105-109.
- Rabiu MM & Abiose A (2001). Magnitude of trachoma and barriers to uptake of lid surgery in a rural community of northern Nigeria. *Ophthalmic Epidemiology*, 8: 181-190.
- Bowman RJ, Faal H, Jatta B, Myatt M, Foster A, Johnson GJ & Bailey RL (2002). Longitudinal study of trachomatous trichiasis in the Gambia: barriers to acceptance of surgery. *Investigative Ophthalmology and Visual Science*, 43: 936-940.
- Oliva MS, Munoz B, Lynch M, Mkocho H & West SK (1997-1998). Evaluation of barriers to surgical compliance in the treatment of trichiasis. *International Ophthalmology*, 21: 235-241.
- Courtright P (1994). Acceptance of surgery for trichiasis among rural Malawian women. *East African Medical Journal*, 71: 803-804.
- Alves APX, Medina NH & Cruz AAV (2002). Trachoma and ethnic diversity in the Upper Rio Negro Basin of Amazonas State, Brazil. *Ophthalmic Epidemiology*, 9: 29-34.