



ORIGINAL ARTICLE

Prevalence of the *Helicobacter pylori* in the tonsils and adenoids[☆]



Tuba Bayindir^a, Yuksel Toplu^a, Baris Otlu^a, Yusuf Yakupogullari^a, Ozge Yildirim^a, Mahmut Tayyar Kalcioğlu^{b,*}

^a Inonu University, Malatya, Turkey

^b Istanbul Medeniyet University, Istanbul, Turkey

Received 31 May 2014; accepted 24 August 2014

Available online 28 March 2015

KEYWORDS

Helicobacter pylori;
Reservoirs;
Adenoids;
Palatine tonsil

Abstract

Introduction: There is an ongoing debate about the existence and effects of *Helicobacter pylori* (Hp) in adenotonsillar tissue.

Objective: A clinical study was conducted to assess the existence of Hp in the adenoid and/or adenotonsillar tissues, which were surgically excised due to chronic adenotonsillitis.

Methods: Phosphoglucosamine mutase gene for the detection of Hp and cytotoxin-associated gene as virulence gene were examined in 84 adenotonsillar tissues obtained from 64 patients and patients' serum by using polymerase chain reaction.

Results: Hp IgG was detected in 57 (89%) patients' serum. A total of seven tissue samples from 64 patients (10.9%) were found positive for Hp DNA, of which five were adenoids and two were tonsil tissues. All polymerase chain reaction positive samples were also positive for the cytotoxin-associated gene, which is a virulence determinant for the organism.

Conclusion: This study suggests that children are exposed to Hp at an early age of their life in this province. Hp may have a role in the pathogenesis of chronic adenotonsillitis, especially in endemic areas.

© 2015 Associação Brasileira de Otorrinolaringologia e Cirurgia Cérvico-Facial. Published by Elsevier Editora Ltda. All rights reserved.

[☆] Please cite this article as: Bayindir T, Toplu Y, Otlu B, Yakupogullari Y, Yildirim O, Kalcioğlu MT. Prevalence of the *Helicobacter pylori* in the tonsils and adenoids. Braz J Otorhinolaryngol. 2015;81:307–11.

* Corresponding author.

E-mail: mtkalcioğlu@hotmail.com (M.T. Kalcioğlu).

PALAVRAS-CHAVE

Helicobacter pylori;
Reservatórios;
Adenoides;
Tonsila palatina

Prevalência do *Helicobacter pylori* em amígdalas e adenóides**Resumo**

Introdução: Há um debate atual sobre os efeitos da *Helicobacter pylori* (Hp) no tecido adenotonsilar.

Objetivo: Conduzimos um estudo clínico para avaliar a existência de Hp nos tecidos adenóideanos e/ou adenotonsilar, os quais foram removidos cirurgicamente em decorrência de adenotonsilite crônica.

Método: No total, 84 amostras de tecido obtidos de 64 pacientes foram analisadas para o gen fosfoglicosamina mutase para a detecção de Hp. Os casos positivos foram a seguir examinados para o gen associado à citotoxina, relacionado a virulência, usando-se o método de Reação de Polimerase em Cadeia (PCR).

Resultados: A IgG de Hp foi detectado em 57 (89%) soros de pacientes. Sete amostras de tecido de sessenta e quatro pacientes (10.9%) resultou positivo para o DNA de Hp, das quais cinco eram adenóides e duas eram tecido tonsilar. No PCR todas as amostras foram também positivas para o gen associado à citotoxina, o qual é um determinante de virulência.

Conclusão: Esse estudo sugere que as crianças são expostas ao Hp nos primeiros anos de vida nessa província e que o Hp pode ter um papel na patogênese da adenotonsilite crônica, principalmente em áreas endêmicas.

© 2015 Associação Brasileira de Otorrinolaringologia e Cirurgia Cérvico-Facial. Publicado por Elsevier Editora Ltda. Todos os direitos reservados.

Introduction

Helicobacter pylori (Hp) is a microaerophilic, Gram-negative spiral microorganism that colonizes the human gastric mucosa. It is the most frequent cause of gastric and duodenal ulcers in humans. The relationship between Hp and some gastrointestinal malignancies has also been demonstrated.¹ Particularly, cytotoxin-associated gene (cagA) positive strains are associated with a significantly increased risk for the development of atrophic gastritis, mucosa-associated lymphoid tissue lymphoma (MALToma), and gastric cancer. Hp is generally acquired during childhood (<10 years) via the fecal-oral, oral-oral, and gastric-oral transmission routes,²⁻⁵ and can remain silent for a lifetime.^{3,6} The transmission route of Hp infection has not been clearly understood.

The Waldeyer ring is the first step in the mucosal defense against invading pathogens through its MALT content. Adenoid and tonsil tissues are part of the Waldeyer ring. These participate in the immune system, especially in children. On the other hand, adenoidectomy and/or tonsillectomy represent the most common surgical procedures in childhood because of chronic infection and/or hypertrophy.⁷

Though the stomach is a natural reservoir for Hp, various tissues such as the gall bladder, gingiva, oral lesions, and the dental plate have been demonstrated to be potential extra-gastric reservoirs of this pathogen.^{8,9} Furthermore, Hp has been found in nasal polyps, nasal mucosa, and saliva.¹⁰ Recent studies have suggested that adenotonsillar tissue could be an extra-gastric reservoir for Hp, but the results have been conflicting.^{5,8,11-15} Detection of the colonization and accumulation of Hp in different regions of the body is particularly important to better understanding the modes of

transmission and progress of infection of this organism. This study aimed to clarify the role of adenotonsillar tissue on Hp infection. Whether adenotonsillar tissue an extra-gastric reservoir for Hp or Hp has a role in the pathogenesis of chronic adenotonsillitis.

Methods**Patients**

This clinical study was performed at the University Otorhinolaryngology and Clinical Microbiology Departments between August of 2011 and August of 2012. Surgically excised adenoid and tonsil tissues and serum samples were collected from children who underwent adenoidectomy and adenotonsillectomy due to chronic adenotonsillitis. A total of 64 children (34 males, 30 females) were included in the study. The mean age of the patients was 5.9 years, ranging between 1 and 17 years. A total of 84 clinical specimens were collected. Sixty-two biopsy specimens were adenoid and 22 were tonsillar tissue. Venous peripheral blood samples (5-6 mL) were collected from all patients.

Inclusion criteria

The surgical indications for adenoidectomy and adenotonsillectomy were as follows: chronic or recurrent tonsil infections (six or more tonsillitis episodes per a year) for tonsillectomy, and adenoid enlargement (especially up to 70% blockage of the choana on endoscopic examination), which causes obstructive symptoms for adenoidectomy.⁷

Exclusion criteria

Patients who had taken antibiotics, proton pump inhibitors, or H₂ receptor antagonists and antacids during a four-week period prior to surgery, as well as patients who had a clinical history of dyspeptic or gastroesophageal symptoms on the systematic questionnaire were excluded from the study. All patients were operated under general anesthesia. Tissues and serum samples were stored at -70°C until laboratory analysis.

Laboratory

Venous peripheral blood samples (5–6 mL) were collected from all patients. Blood samples were then centrifuged at 2500 rpm for 10 min. The serum was separated and stored at -80°C . Serum samples were analyzed for Hp immunoglobulin G (IgG) with a commercial immune assay kit (Dima GmbH – Germany). Briefly, 250–500 μL of patient serum was dropped onto the test cassette and the results were read visually within 10 min, according to the manufacturer's recommendations. This is a rapid serologic test. The test was used to indicate the higher prevalence of Hp exposure in the childhood in this region.

DNA extraction

Adenoid and tonsil tissue specimens were mechanically disrupted using the Tissue Lyser system (Qiagen – Hilden, Germany), and then incubated overnight in tissue lysis buffer. Bacterial DNA was extracted from these samples after completing digestion of tissues using the QIAamp DNA Mini Kit (Qiagen), according to the manufacturer's instructions.

Polymerase chain reaction (PCR) for detection of Hp DNA and *cagA* gene

For detection of Hp and its virulence gene in the clinical specimens, phosphoglucosamine mutase gene (*glmM*) and cytotoxin-associated gene (*cagA*) genes were studied with an in-house PCR method with previously-reported primers.^{16,17} A total 25 μL of amplification mix consisting of 12.5 μL TopTaq DNA PCR Master Mix (QIAGEN – Hilden, Germany), each primers 1 μL (10 pmol/ μL), 8 μL H₂O, and 2.5 μL /each sample extraction product was prepared. Amplification conditions and primer sets are shown in Table 1. PCR products were electrophoresed in 2% agarose gel, then ethidium bromide-stained gel was evaluated in a gel imaging system

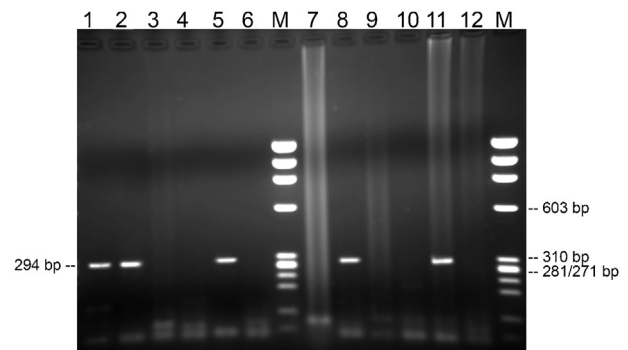


Figure 1 *glmM* (294 bp) is illustrated in the agarose gel (2%). Lanes 1, 2, 5, 8, positive samples; lane 11, positive control; lane 12, negative control; lanes 3, 4, 6, 7, 9, 10, negative samples. Lane M, molecular weight markers (DNA molecular Weight Marker IX, Roche).

(Gel logic 2200 imaging system [1708 \times 1280 pixels; Kodak Company– NY, United States]; Fig. 1).

PCR analysis was performed on randomly selected tonsil and adenoid tissues.

Ethical considerations

This study was preformed after ethical approval from the Human Ethics Committee of the University. Informed consents were signed by parents of the patients before blood sample and tissue collection.

Results

Venous peripheral blood samples (5–6 mL) were collected from all patients. A total of 57 serum samples of 64 patients (89%) were found to be positive for Hp IgG. Mean age was 6.3 years (3–17 years); sex distribution comprised 32 boys and 25 girls.

In the PCR analysis, seven clinical specimens belonging to different patients among the 64 patients (10.9%) were positive for Hp DNA. A representative gel image is shown in Fig. 1. Of these, two were tonsils, and the remaining five were adenoids from different patients. The *cagA* virulence gene was positive in all Hp positive tissues. It was found that 10.9% of the patients were positive for Hp and 90% of these patients were positive for Hp IgG.

Table 1 DNA primers used and the amplification conditions.

Gene	Primer sequence	PCR product (bp)	PCR conditions	References
<i>glmM</i>	5'-AAGCTTTTAGGGGTGTTAGGGGTTT-3' 5'-AAGCTTACTTTCTAACACTAACGC-3'	294	94 $^{\circ}\text{C}$, 1 min; 55 $^{\circ}\text{C}$, 1 min; 72 $^{\circ}\text{C}$, 1 min (35 cycles)	16
<i>cagA</i>	ATAATGCTAAATTAGACAACCTTGAGCGA TTAGAATAATCAACAAACATCACGCCA	298	94 $^{\circ}\text{C}$, 1 min; 60 $^{\circ}\text{C}$, 1 min; 72 $^{\circ}\text{C}$, 1 min (45 cycles)	17

PCR, polymerase chain reaction.

Discussion

Hp infection is widespread throughout the world, and the prevalence of the infection may vary according to patients' socioeconomic status, geographic area, age, and ethnicity. Its prevalence is about 30–40% in developed countries, whereas the rate is up to 90% in developing or underdeveloped countries.^{18–21}

The presence of Hp in the upper aero-digestive tract has been reported in different studies. Minocha et al.⁹ reported a low Hp prevalence in the gastric mucosa of patients with a history of tonsillectomy. It is suspected that Hp colonizes on tonsillar and/or adenoid tissues as an extra-gastric reservoir. Nevertheless, Di Bonoventura did not support this opinion, and claimed that tonsils did not represent a reservoir or sanctuary for Hp.²² However, there are still contradictions in recent investigations. Also, some studies proposed that Hp might have a role in the pathogenesis of chronic adenotonsillitis. The pathogenic process of chronic adenotonsillitis, from single to chronic infections, has not been clearly understood. It has been accepted that tonsillar crypt obstruction due to infection causes differentiation of resident flora to some pathogenic bacteria.^{2,23,24} In the present study, the *cagA* virulence gene was found positive in all patients who were positive for Hp DNA on PCR analysis. These results support that Hp may have a role in the pathogenesis of chronic adenotonsillitis, especially in endemic regions, such as Turkey.

Bacterial culture is a valuable method of diagnosis for Hp infections. But, the fastidious nature of Hp causes a high frequency of false negative results with this methodology. Therefore, various methods have been used for the diagnosis of Hp infection. Particularly, nested PCR is widely preferred when it comes to detecting Hp in clinical practice because of its high sensitivity and specificity.¹⁵ The most accurate methods of diagnosis have been accepted as immunohistochemistry and PCR analysis. There is still no single test that is accepted as the gold standard for Hp detection. The usage of combined tests is still preferred both in pediatric and adult studies.^{1,25} The present study used serology for indicating the higher prevalence of Hp exposure in the local pediatric population and the nested PCR method (more sensitive) to detect Hp in tissue samples.

Bitar et al.¹² tested 25 adenoid specimens using the rapid urease test (RUT), histological evaluation, and nested PCR methods. They reported an 84% positivity rate for Hp in the adenoids with RUT. On histopathological examination, other bacteria were found 68% in RUT-positive tissues, whereas only 16% were Hp-like organisms. Finally, the authors reported all of their samples to be negative for Hp DNA on nested PCR. Therefore, they concluded that nested PCR was the best way to diagnose Hp. Similarly, Toros et al. tested 84 adenoid and tonsil specimens by RUT and histopathological evaluation.¹³ They did not detect Hp in any of the specimens by either RUT or histopathology. Hence, they noted that colonization of Hp in tonsillar and/or adenoid tissue was unlikely.

Vilarinho et al.¹⁴ aimed to determine whether the adenotonsillar tissue might constitute an extra-gastric reservoir for Hp. They used many diagnostic methods, including RUT, immunohistochemistry with a polyclonal anti-Hp antibody, fluorescence in situ hybridization (FISH) with a specific

Hp peptide nucleic acid (PNA) probe, and PCR-DNA ELISA designed for detection of the *vacA* gene of the organism. Anti-Hp antibodies were detected in 39% of patients. Immunohistochemistry was found positive in three tonsil tissues whose serologies were negative. RUT was positive in two adenoid and two tonsil tissues with positive serology. The PNA-FISH and PCR-DNA ELISA tests, which are considered the most specific and sensitive methods for Hp detection, were found to be negative in all tissues. According to the results, the investigators reported that adenotonsillar tissues did not constitute an extra-gastric reservoir for Hp infection in children.

In contrast to the studies above, Abdel-Monem et al.¹¹ found Hp to be positive in adenotonsillar tissue using PCR with the *ureC* gene sequence in 16.6% of patients. A total of 30 surgical specimens (20 tonsils and ten adenoids from 20 patients) were evaluated by RUT, blood serology, and PCR. They reported that RUT was positive in 16 specimens (53.3%) and serology was positive for Hp IgG antibodies in four patients (20%). They concluded that the adenotonsillar tissues could be an extra-gastric reservoir area for Hp infection in children with chronic adenotonsillar diseases.

The *cagA* gene has been shown to be present in 60–70% of Hp strains, and these strains are accepted as virulent.²⁶ The *cagA* protein interacts with cellular proteins, and consequently, may cause morphological damage in the epithelium and failure in the secretion and signal transmission in human cells. Therefore, these strains are much more potent in causing gastric mucosal damage.^{26,27}

In this study, it was found that 10.9% of the children with chronic adenotonsillitis were positive for Hp, and 90% of these patients were positive for Hp IgG. Although it was a valuable diagnostic tool in gastric samples, use of RUT was not preferred, as it gives high rates of false positive results due to the intense accumulation of urease-positive present in the normal bacterial flora of the upper aero-digestive tract. Bacterial culture can be a valuable diagnostic tool, but because of the low growth ability of Hp in materials with a high bacterial load in the flora members, it was not used. The detection of the bacterial DNA and its virulence gene were chosen to investigate the bacteria in adenotonsillar tissue. It was observed that Hp was present in 8% and 9% of adenoids and tonsils, respectively. Regarding the previously published studies, a high rate of Hp in the present clinical specimens was found. This was most likely due to the high frequency of the organism in this population. Additionally, it was observed that all Hp positive samples were also simultaneously positive for the *cagA* gene.

Conclusion

In the light of the study results, it is argued that Hp can colonize the adenoid and tonsillar tissues of children with chronic adenotonsillitis. This pilot study did not classify children separately. Tissues and serum samples were collected from the patients who had undergone adenoidectomy with enlargement and tonsillectomy with chronic or recurrent infections; this represents a limitation of the present study. Further studies are needed to exhibit whether Hp resides in adenotonsillar tissue or has a role in the pathogenesis of chronic adenotonsillitis.

Conflicts of interest

The authors declare no conflicts of interest.

References

1. Lawson AJ. *Helicobacter*. In: Versalovic J, Carroll KC, Funke G, et al., editors. Manual of clinical microbiology. Washington, DC: ASM Press; 2011. p. 900–15.
2. Cirak MY, Ozdek A, Yilmaz D, Bayiz U, Samim E, Turet S. Detection of *Helicobacter pylori* and its CagA gene in tonsil and adenoid tissues by PCR. *Arch Otolaryngol Head Neck Surg*. 2003;129:1225–9.
3. Azevedo NF, Guimaraes N, Figueiredo C, Keevil CW, Vieira MJ. A new model for the transmission of *Helicobacter pylori*: role of environmental reservoirs as gene pools to increase strain diversity. *Crit Rev Microbiol*. 2007;33:157–69.
4. Azevedo NF, Huntington J, Goodman KJ. The epidemiology of *Helicobacter pylori* and public health implications. *Helicobacter*. 2009;14:1–7.
5. Vayisoglu Y, Ozcan C, Polat A, Delialioglu N, Gorur K. Does *Helicobacter pylori* play a role in the development of chronic adenotonsillitis? *Int J Pediatr Otorhinolaryngol*. 2008;72:1497–501.
6. Bujanover Y, Reif S, Yahav J. *Helicobacter pylori* and peptic disease in the pediatric patient. *Pediatr Clin North Am*. 1996;43:213–34.
7. Suurna MV. Management of adenotonsillar disease. In: Lalwani AK, editor. Current diagnosis and treatment in otolaryngology-head and neck surgery. New York: McGraw-Hill; 2012. p. 362–76.
8. Jabbari MY, Rafeey M, Radfar R. Comparative assessment of *Helicobacter pylori* colonization in children tonsillar tissues. *Int J Pediatr Otorhinolaryngol*. 2009;73:1199–2201.
9. Minocha A, Raczkowski CA, Richards RJ. Is a history of tonsillectomy associated with a decreased risk of *Helicobacter pylori* infection? *J Clin Gastroenterol*. 1997;25:580–2.
10. Nguyen AM, Engstrand L, Genta RM, Graham DY, el-Zaatari FA. Detection of *Helicobacter pylori* in dental plaque by reverse transcription-polymerase chain reaction. *J Clin Microbiol*. 1993;31:783–7.
11. Abdel-Monem MH, Magdy EA, Nour YA, Harfoush RA, Ibreak A. Detection of *Helicobacter pylori* in adenotonsillar tissue of children with chronic adenotonsillitis using rapid urease test PCR and blood serology: a prospective study. *Int J Pediatr Otorhinolaryngol*. 2011;75:568–72.
12. Bitar MA, Soweid A, Mahfouz R, Zaatari G, Fuleihan N. Is *Helicobacter pylori* really present in the adenoids of children? *Eur Arch Otorhinolaryngol*. 2005;262:987–92.
13. Toros SZ, Toros AB, Kaya KS, Deveci I, Özel L, Naiboğlu B, et al. A study to detect *Helicobacter pylori* in adenotonsillar tissue. *Ear Nose Throat J*. 2011;90:E32.
14. Vilarinho S, Guimaraes NM, Ferreira RM, Gomes B, Wen X, Vieira MJ, et al. *Helicobacter pylori* colonization of the adenotonsillar tissue: fact or fiction? *Int J Pediatr Otorhinolaryngol*. 2010;74:807–11.
15. Eyigor M, Eyigor H, Gultekin B, Aydin N. Detection of *Helicobacter pylori* in adenotonsillar tissue specimens by rapid urease test and polymerase chain reaction. *Eur Arch Otorhinolaryngol*. 2009;266:1611–3.
16. Lu JJ, Perng CL, Shyu RY, Chen CH, Lou Q, Chong SK, et al. Comparison of five PCR methods for detection of *Helicobacter pylori* DNA in gastric tissues. *J Clin Microbiol*. 1999;37:772–4.
17. Hamlet A, Thoreson AC, Nilsson O, Svennerholm AM, Olbe L. Duodenal *Helicobacter pylori* infection differs in cagA genotype between asymptomatic subjects and patients with duodenal ulcers. *Gastroenterology*. 1999;116:259–68.
18. Khalifa MM, Sharaf RR, Aziz RK. *Helicobacter pylori*: a poor man's gut pathogen? *Gut Pathog*. 2010;2:2–12.
19. Agirdir BV, Bozova S, Derin AT, Turhan M. Chronic otitis media with effusion and *Helicobacter pylori*. *Int J Pediatr Otorhinolaryngol*. 2006;70:829–34.
20. Lukes P, Astl J, Pavlik E, Potuzníková B, Sterzl I, Betka J. *Helicobacter pylori* in tonsillar and adenoid tissue and its possible role in oropharyngeal carcinogenesis. *Folia Biologica*. 2008;54:33–9.
21. Zahedi MJ, Moghadam SD, Mosavi MA, Mirshekari T, Hayatbakhsh M. *Helicobacter pylori* colonization in biopsies of the adenotonsillectomy specimens. *Am J Applied Sci*. 2009;6:2050–3.
22. di Bonaventura G, Neri M, Neri G, Catamo G, Piccolomini R. Do tonsils represent an extragastric reservoir for *Helicobacter pylori* infection. *J Infect*. 2001;42:221–2.
23. Brook I, Yocum P, Foote PA Jr. Changes in the core tonsillar bacteriology of recurrent tonsillitis: 1977–1993. *Clin Infect Dis*. 1995;21:171–6.
24. Skinner LJ, Winter DC, Curran AJ, Barnes C, Kennedy S, Maquire AJ, et al. *Helicobacter pylori* and tonsillectomy. *Clin Otolaryngol Allied Sci*. 2001;26:505–9.
25. Ogata SK, Kawakami E, Patricio FR, Pedroso MZ, Santos AM. Evaluation of invasive and non-invasive methods for the diagnosis of *Helicobacter pylori* infection in symptomatic children and adolescents. *Sao Paulo Med J*. 2001;119:67–71.
26. Chomvarin C, Namwat W, Chaicumpar K, Mairiang P, Sangchan A, Sripan B, et al. Prevalence of *Helicobacter pylori* vacA, cagA, cagE, iceA and babA2 genotypes in Thai dyspeptic patients. *Int J Infect Dis*. 2008;12:30–6.
27. Hatakeyama M. SagA of CagA in *Helicobacter pylori* pathogenesis. *Curr Opin Microbiol*. 2008;11:30–7.