

## Angioleiomyoma of the nasal septum

Carlos Roberto Ribeiro Navarro Júnior<sup>1</sup>, Adriano Santana Fonseca<sup>2</sup>, José Rodrigo Lordello de Mattos<sup>3</sup>,  
Nilvano Alves de Andrade<sup>4</sup>

**Keywords:** leiomyoma, nose neoplasms, nasal septum.

### INTRODUCTION

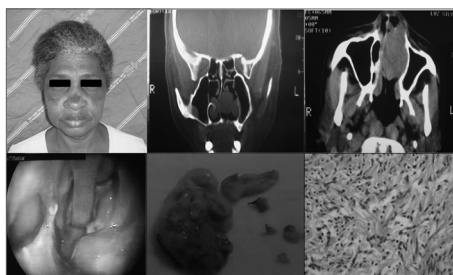
Leiomyoma is a benign smooth muscle tumor, more commonly found in the uterus (95%), skin (3%), nutritional and gastrointestinal tracts (1.5%)<sup>1</sup>. It was initially described in the nasal cavity by Maesaka et al. in 1966<sup>2</sup>.

The goal was to describe a case with clinical manifestations and histopathology findings of angioleiomyoma of the nasal septum, a rare benign neoplasia which represents less than 1% of all the leiomyomas in the human body<sup>3</sup>.

### CASE PRESENTATION

M.F.L.S., 62 years, female, African-descendant, she came to our ENT service complaining of a tumor in her left nasal cavity with six years of evolution. In the three initial years it had a progressive growth, associated with low volume epistaxis episodes. After such period, she developed nasal obstruction on the left side and facial pain. Upon physical exam and fibroscopy we noticed a brown, smooth, pedicled lesion on the left-side septum, well outlined, measuring approximately 4 x 2cm, completely occluding the left nasal cavity and pushing the nasal septum. CT scan of the paranasal sinuses showed a well-outlined soft tissue mass, pushing

the septum and the lateral wall. Biopsy reported leiomyoma. Later on, the tumor was endoscopically resected, with a 1cm margin, considered adequate according to anatomical and pathological criteria. Microscopy showed polypoid fragments, coated by a single layer of cylindrical hair cells, typical pseudostratified, showing in the stroma, typical leiomyoma bundles around the thick walls of vessels. (Fig. 1)



**Figure 1.** Set of photographs from this patient, CT scan, late post-op, macroscopy and microscopy of the lesion.

### DISCUSSION AND FINAL REMARKS

This is a slow growth tumor. The most common symptoms are: nasal obstruction, epistaxis, facial pain and headaches. He most frequent treatment for nasal septum angioleiomyoma is endoscopic resection with macroscopic margin, and this was the treatment option for this case - excision with macroscopic and microscop-

pic free margins. Vascular leiomyomas are bundles of smooth muscle cells, relatively organized, and permeated by thick wall vessels<sup>4</sup>.

The nasal septum vascular leiomyoma is an extremely rare tumor, of uncertain origin<sup>5</sup>. Resection is the procedure of choice and it bears a high cure rate. The endoscopic procedure is a good option for small to moderate size tumors<sup>6</sup>.

### REFERENCES

1. Ardekian L, Samet N, Talmi YP, Roth Y, Bendet E, Kronenberg J. Vascular leiomyoma of the nasal septum. *Otolaryngol Head Neck Surg.* 1996;114(6):798-800.
2. Barr GD, More IAR, Path FRC, McCallum HM, Path FRC. Leiomyoma of the nasal septum. *J Laryngol Otol.* 1990;104:891-3.
3. Bloom DC, Finley JC Jr, Broberg TG, Cueva RA. Leiomyoma of the nasal septum. *Rhinology.* 2001;39(4):233-5.
4. Campelo VES, Neves MC, Nakanishi M, Voegels RL. Angioleiomioma de cavidade nasal: relato de um caso e revisão de literatura. *Braz J Otorhinolaryngol.* 2008;74 (1):147-150.
5. Singh R, Hazarika P, Balakrishnan R, Gangwar N, Pujary P. Leiomyoma of the nasal septum. *Indian J Cancer.* 2008;45:173-5
6. Timirlyaleev MKH. Angioleiomyoma of the nasal septum. *Vestnik Otorinolaringol.* 1973;35:106-10.

<sup>1</sup> MD. Resident Physician in ENT and HNS - Santa Casa de Misericórdia da Bahia.

<sup>2</sup> MD. ENT and Maxillo-facial surgeon. Preceptor at the ENT Residency Program - Santa Casa de Misericórdia da Bahia.

<sup>3</sup> MD. ENT and Maxillo-facial surgeon. Preceptor at the ENT Residency Program - Santa Casa de Misericórdia da Bahia.

<sup>4</sup> PhD in Surgery - USP, Head of the ENT Residency Program - Santa Casa de Misericórdia da Bahia.

Send correspondence to: Praça Conselheiro Almeida Couto 500 Nazaré Salvador BA 40050-410.

Paper submitted to the BJORL-SGP (Publishing Management System – Brazilian Journal of Otorhinolaryngology) on October 16, 2009; and accepted on December 15, 2010. cod. 6714