



ORIGINAL ARTICLE

## Balloon laryngoplasty for acquired subglottic stenosis in children: predictive factors for success<sup>☆,☆☆</sup>



Rebecca Maunsell<sup>a</sup>, Melissa A.G. Avelino<sup>b,c,d,\*</sup>

<sup>a</sup> Hospital de Sumaré, Universidade Estadual de Campinas (UNICAMP), Campinas, SP, Brazil

<sup>b</sup> Pontifícia Universidade Católica de Goiás (PUC-GO), Goiânia, GO, Brazil

<sup>c</sup> Hospital da Criança de Goiânia, Goiânia, GO, Brazil

<sup>d</sup> Universidade Federal de Goiás (UFG), Goiânia, GO, Brazil

Received 11 December 2013; accepted 24 May 2014

Available online 23 July 2014

### KEYWORDS

Laryngostenosis;  
Laryngoplasty;  
Dilatation;  
Child

### Abstract

**Introduction:** The treatment of subglottic stenosis in children remains a challenge for the otorhinolaryngologist, and may involve both endoscopic and open surgery.

**Objective:** To report the experience of two tertiary facilities in the treatment of acquired subglottic stenosis in children with balloon laryngoplasty, and to identify predictive factors for success of the technique and its complications.

**Methods:** Descriptive, prospective study of children diagnosed with acquired subglottic stenosis and submitted to balloon laryngoplasty as primary treatment.

**Results:** Balloon laryngoplasty was performed in 37 children with an average age of 22.5 months; 24 presented chronic subglottic stenosis and 13 acute subglottic stenosis. Success rates were 100% for acute subglottic stenosis and 32% for chronic subglottic stenosis. Success was significantly associated with acute stenosis, initial grade of stenosis, children of a smaller age, and the absence of tracheostomy. Transitory dysphagia was the only complication observed in three children.

**Conclusion:** Balloon laryngoplasty may be considered the first line of treatment for acquired subglottic stenosis. In acute cases, the success rate is 100%, and although the results are less promising in chronic cases, complications are not significant and the possibility of open surgery remains without prejudice.

© 2014 Associação Brasileira de Otorrinolaringologia e Cirurgia Cérvico-Facial. Published by Elsevier Editora Ltda. All rights reserved.

<sup>☆</sup> Please cite this article as: Maunsell R, Avelino MA. Balloon laryngoplasty for acquired subglottic stenosis in children: predictive factors for success. Braz J Otorhinolaryngol. 2014;80:409–15.

<sup>☆☆</sup> Institution: Universidade Federal de Goiás (UFG), Goiânia, GO, Brazil.

\* Corresponding author.

E-mail: [melissa.avelino@uol.com.br](mailto:melissa.avelino@uol.com.br) (M.A.G. Avelino).

**PALAVRAS-CHAVE**

Laringoestenose;  
Laringoplastia;  
Dilatação;  
Criança

## Laringoplastia com balão para estenose sub-glótica adquirida na infância: fatores preditivos de sucesso

**Resumo**

**Introdução:** O tratamento das estenoses subglóticas em crianças ainda representa um desafio para o otorrinolaringologista, e pode envolver tanto procedimentos endoscópicos quanto cirurgias reconstrutivas abertas.

**Objetivo:** Apresentar a experiência de dois serviços terciários no manejo das estenoses subglóticas adquiridas em crianças, através da laringoplastia com balão e identificar fatores preditivos de sucesso e as complicações.

**Método:** Estudo descritivo prospectivo de crianças com estenose subglótica adquirida submetidas à laringoplastia com balão como tratamento primário.

**Resultados:** Foram incluídas 37 crianças (média de idade 22,5 meses): 24 crianças portadoras de estenose subglótica crônica e 13 de estenose subglótica aguda. A taxa de sucesso do tratamento foi de 100% para os casos agudos e 32% para os casos crônicos. O sucesso do tratamento teve correlação significativa com: tempo de evolução da estenose, grau inicial da estenose, menor idade das crianças e a ausência de traqueostomia prévia. Disfagia transitória foi a única complicação observada em três pacientes.

**Conclusão:** A laringoplastia com balão pode ser considerada como primeira linha de tratamento nas estenoses subglóticas. Nos casos agudos a taxa de sucesso é de 100% e o ganho, mesmo que parcial nos casos crônicos, é isento de complicações significativas e não traz prejuízo para cirurgias reconstrutivas posteriores.

© 2014 Associação Brasileira de Otorrinolaringologia e Cirurgia Cérvico-Facial. Publicado por Elsevier Editora Ltda. Todos os direitos reservados.

**Introduction**

In recent years, there has been a reduction of mortality in neonatal intensive care units (ICUs) due to the impact of recent technological advances in the perinatal area.<sup>1</sup> As a consequence, prolonged orotracheal intubation increased in frequency, and in contrast to adults, in whom tracheostomy is a well established procedure for these cases, in the pediatric age group this indication is complex.<sup>2</sup>

Thus, an increase in acquired subglottic stenosis (SGS) has been observed in children. SGS is a narrowing of endolarynx, representing one of the most common causes of stridor and respiratory distress in children. The pediatric population is the most commonly affected, because this is the narrowest region of the airway at this age. SGS may be congenital or acquired. The acquired form is responsible for 90% of cases of subglottic narrowing in children and is usually secondary to prolonged tracheal intubation.

The treatment of acquired stenosis may involve endoscopic procedures, both in the acute phase and the chronic phase. Within the arsenal of endoscopic procedures, the use of balloon dilatation or balloon laryngoplasty is becoming popular across the world as a primary therapeutic option.<sup>3</sup> In the acute phase, one of the therapeutic options is tracheostomy. Despite the immediate resolution of respiratory failure, the necessary care, mainly in the case of suckling infants with tracheostomy, is considerable, causing much anguish, fear, and social limitation for caregivers and for the child. The risk of obstruction of the tracheostomy tube inside and especially outside the hospital setting cannot be ignored, nor the risk of death. Furthermore, the tracheostomy itself can

create additional complications to the airway, such as collapse, stenosis, and persistent tracheal granulation tissue.<sup>4</sup>

It must also be considered that tracheostomy does not solve the problem of healing of the inflammatory process already embedded in the subglottic region, and often children with tracheostomy after an intubation for laryngitis evolve to SGS that is only diagnosed later.

In chronic SGS, open surgeries for laryngeal reconstruction, when carefully planned, exhibit high rates of resolution. However, these procedures require the coordination of an experienced team for postoperative care, involving sedation weaning and the management of unstable airways. Moreover, these operations involve risks of graft infection, dehiscence, sepsis, and restenosis, which should not be underestimated. Thus, the management of these patients remains a *bona fide* challenge to the otorhinolaryngologist.

Balloon dilatation has been used to treat laryngeal or tracheal stenosis in children as early as the 1980s, with encouraging results.<sup>5</sup> The main advantage of this technique, in comparison with other methods of endoscopic dilatation with tracheal tubes and dilators, is the possibility to promote an outward expansion, even in the presence of very reduced lumen. It is speculated that its use, in comparison with other methods of dilatation, promotes less tissue injury and, thus, less scar formation.

In a systematic review and meta-analysis in 2013 on balloon laryngoplasty in cases of pediatric SGS, Lang and Brietzke<sup>3</sup> concluded that this treatment has a good short-term success rate, with rare complications; and that failures were related to more severe stenoses.

The objective of the present study was to demonstrate the experience of two tertiary services in the management of SGS secondary to tracheal intubation in children, with balloon laryngoplasty as a primary treatment, and to relate the predictors of technical failure and its complications.

## Methods

This was a prospective, descriptive study of children diagnosed with acquired SGS after tracheal intubation, undergoing balloon laryngoplasty as a primary treatment from August of 2011 to September of 2013 in two departments of otorhinolaryngology in tertiary hospitals. The procedures were performed in each of the services by the same surgeons, with training and experience in pediatric airway management.

Patients older than 14 years, with less than three months of follow-up, undergoing other previous laryngeal procedures, with congenital laryngeal stenosis, and those whose parents or guardians refused to sign the informed consent were excluded.

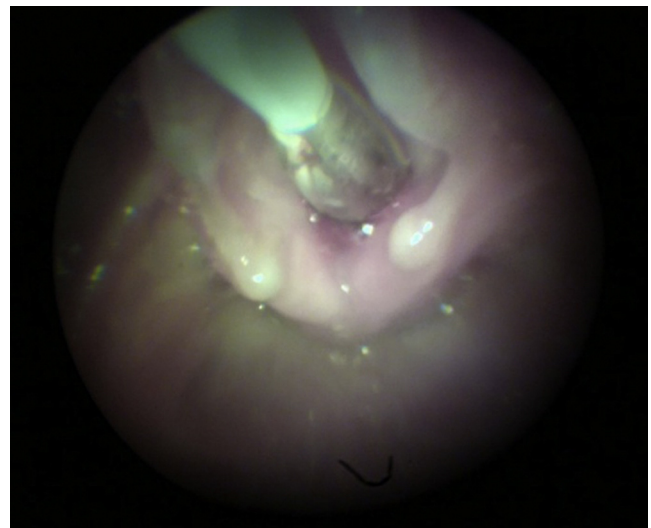This study was approved by the ethics committees of each department under numbers 002/2011 and 001/2011. After being informed about the procedure and its risks, all parents or guardians signed an informed consent.

All enrolled patients were evaluated for age, length of stenosis, number of dilatations, degree of initial subglottic stenosis, and presence of tracheostomy.

The children were further divided into two groups: the group of chronic SGS, i.e., children under dilatation of SGS in a period >30 days from the onset of symptoms of SGS and/or from diagnosis, and the group of acute SGS, i.e., those children dilated in the period  $\leq$ 30 days from the onset of symptoms or from diagnosis of SGS.

The degree of subglottic stenosis was determined using the classification of Myer and Cotton,<sup>6</sup> which was obtained after bronchoscopy using a 0-degree rigid endoscope with a diameter ranging from 2.7 mm to 4 mm. Retrograde endoscopy with Machida® 3.2 mm flexible fiber endoscope was also performed in patients undergoing tracheostomy when it was not possible to pass the rigid endoscope through the stricture, thus allowing a better staging of the degree of acquired SGS.

The dilatations were always performed with the patient under general anesthesia, spontaneous ventilation, and intermittent apnea during balloon inflation, as needed. Vascular balloons of three different brands (Acclarent®, Boston®, and E. Tamussino®) were used, always with a length of 20–30 mm. The diameters of the balloons varied according to the child's age. Generally, the outside diameter of the most suitable endotracheal tube was considered for each child, adding approximately 2 mm to determine the diameter of the balloon. The time and number of inflations varied according to size of the airway, as well as the pulmonary reserve of the child and/or the perception of supraglottic/glottic edema secondary to dilatation. Generally, the maintenance time of the inflated balloon did not exceed 1.5 min, and the inflations were repeated three times. The inflation pressure of the balloons ranged from 3 to 15 mmHg with a progressive tendency for the use of higher pressures in the last year, after analyzing reports and personal



**Figure 1** Balloon during dilatation. Child during balloon laryngoplasty.

communications from other colleagues with renowned experience in the subject, especially in the most extensive and chronic stenoses. The time elapsed between dilatation procedures ranged from 15 to 60 days, due to availability of surgical time and possible clinical complications, or the lack of favorable conditions for general anesthesia.

All pre- and post-dilatation endoscopies were documented, as well as a detailed description in the medical record regarding the post-procedural outcomes and the occurrence of complications.

Treatment was considered successful in patients who, in the study period, were decannulated and/or had no further signs or symptoms of discomfort, even in the face of residual stenosis.

To correlate the predictors of successful outcomes, a statistical analysis was performed using nonparametric Mann–Whitney *U* and Fisher's exact tests, with a significance level set at 0.05.

## Results

A total of 37 children who underwent balloon laryngoplasty (Fig. 1) were included in the study; 24 had chronic SGS (Fig. 2) and 13 had acute SGS (Fig. 3). The mean age was 22.5 months (range: 1 month to 11 years) (Table 1). Two of 24 patients with chronic SGS and 10 of 13 patients with acute SGS were not tracheostomized. As to the degree of SGS, two patients had grade I, five had grade II, and 30 had grade III. The number of dilatations ranged from one to five, with a mean of 2.5 procedures per patient. Three patients had dysphagia as a complication immediately after the procedure; the dysphagia was transient, resolving in less than 24 h in two cases; in one case, it was persistent, requiring the use of a nasoenteric tube for a period of three weeks.

In the group of chronic stenoses, the mean duration of the stenosis was 22 months (minimum of three months, and maximum of ten years and nine months).

**Table 1** Description of cases with data regarding age, duration of the disease, presence of tracheostomy, degree of stenosis, number of dilatations, and therapeutic success.

Age (months)	Progression time	Tracheostomy	SGS grade	Dilatations (n)	Success
18	Chronic	Yes	III	5	Yes
56	Chronic	Yes	III	2	No
18	Chronic	Yes	III	2	No
37	Chronic	Yes	III	3	No
31	Chronic	Yes	III	3	No
29	Chronic	Yes	III	2	Yes
132	Chronic	No	III	3	Yes
36	Chronic	Yes	III	3	Yes
26	Chronic	Yes	III	3	No
14	Chronic	Yes	III	3	No
16	Chronic	Yes	II	1	Yes
17	Chronic	Yes	III	2	No
40	Chronic	Yes	III	2	No
22	Chronic	Yes	III	1	No
16	Chronic	Yes	I	2	Yes
28	Chronic	Yes	III	2	No
17	Chronic	Yes	III	2	No
36	Chronic	Yes	II	2	Yes
31	Chronic	No	III	1	Yes
33	Chronic	Yes	III	2	No
60	Chronic	Yes	III	5	No
6	Chronic	Yes	II	5	Yes
36	Chronic	Yes	III	4	No
3	Chronic	Yes	III	3	No
17	Chronic	Yes	III	1	No
2	Acute	No	I	1	Yes
1.5	Acute	No	II	2	Yes
2.5	Acute	No	III	2	Yes
15	Acute	No	III	2	Yes
8	Acute	Yes	III	3	Yes
2	Acute	No	II	2	Yes
1	Acute	Yes	III	5	Yes
1.5	Acute	No	II	1	Yes
16	Acute	Yes	II	2	Yes
3	Acute	No	III	3	Yes
1	Acute	No	II	2	Yes
6	Acute	No	III	3	Yes

The success rate was 100% and 32% for acute and chronic stenoses, respectively (Fig. 4).

The minimum follow-up time was three months, with a maximum of 12 months.

Correlating the patient's age with the success of the balloon laryngoplasty technique, it was observed that the younger the child, the higher the success rate (Fig. 5).

Correlating the presence of tracheostomy at the time of the procedure with procedural success, it was observed that non-tracheostomized patients had higher chances of success with the procedure (Fig. 6).

Correlating the degree of subglottic stenosis and procedural success, it was observed that the higher the degree of the stenosis, the greater the chances of failure (Fig. 7).

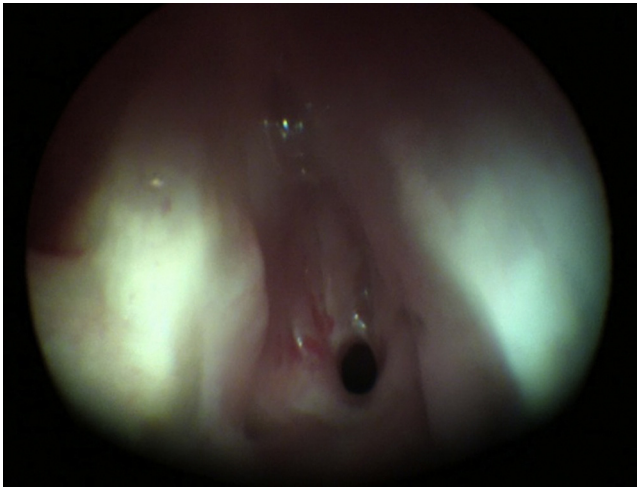
Correlating the number of dilatations and the success of the technique, no statistically significant correlation was observed (Fig. 8).

Correlating the progression time of subglottic stenosis in both groups, it was found that group 1 (children >30 days of stenosis [chronic SGS]) had higher chances of failure (Fig. 4).

In the group of chronic stenoses, no correlation between progression, time of the stenosis, and success rate was observed.

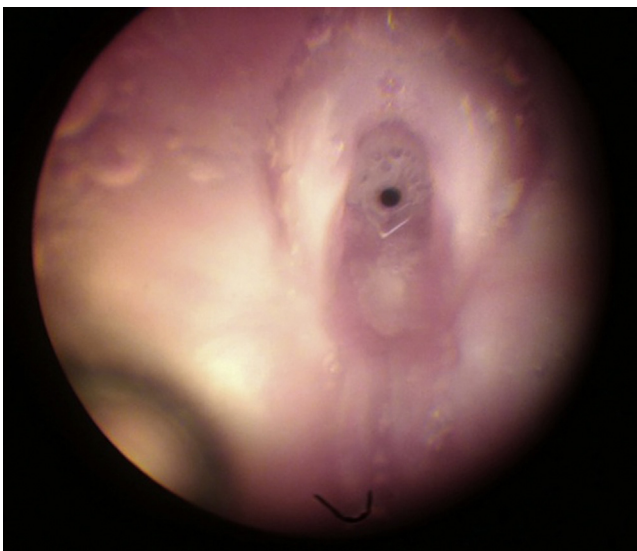
## Discussion

Usually, the treatment of acquired SGS in pediatric patients is a distressing and painful event both for patients and their relatives. In acute cases, the patient is hospitalized and intubated, failing successively in attempts for extubation; or sometimes the child is extubated, but in a state of respiratory failure. In chronic cases, the child already has a tracheostomy or is being treated for recurrent episodes

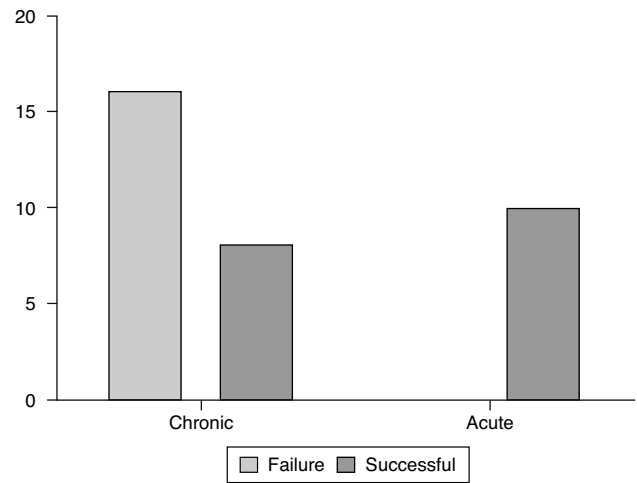


**Figure 2** Chronic subglottic stenosis. Child with chronic grade III SGS, pre-dilatation.

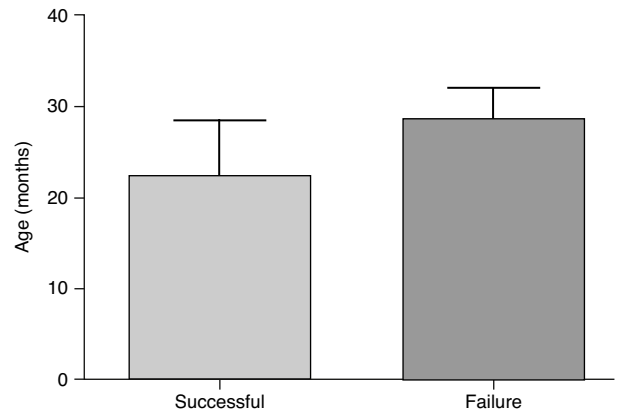
of laryngitis or asthma. These are children who repeatedly seek health services, often without receiving information or referral to a professional in a position to make a diagnosis and establish a sound treatment. The presence of the otorhinolaryngologist trained in the evaluation of pediatric airways and working next to pediatric and neonatal ICUs is critical to change this scenario. Thus, it will be possible to establish early diagnoses and procedures aimed at preventing the occurrence of acquired SGS. The success of dilatation for acute stenoses, as shown in this and other studies,<sup>7-9</sup> confirms this need. Unfortunately, the procedure of tracheostomy has been the only alternative for these cases, in the absence of a proper evaluation. Despite the immediate resolution of respiratory failure, the necessary care, mainly in the case of suckling infants with tracheostomy, is considerable, causing much anguish, fear, and social limitation both for caregivers and for the child. However, the risk of tracheostomy tube obstruction and of



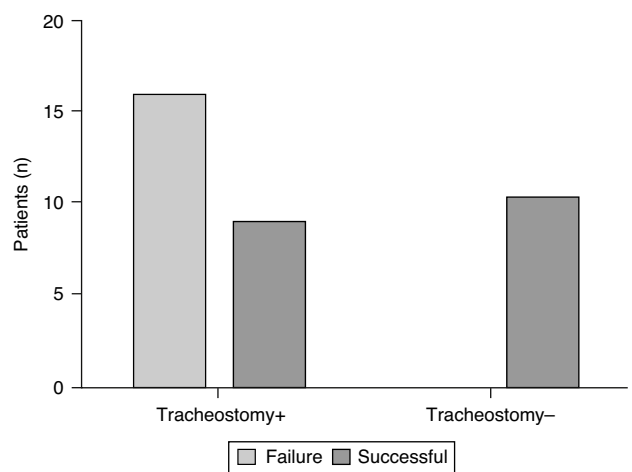**Figure 3** Acute subglottic stenosis. Child with acute grade III SGS, pre-dilatation.



**Figure 4** Correlation of patients in group 1 (chronic) and group 2 (acute) with the chances of success with balloon laryngoplasty.

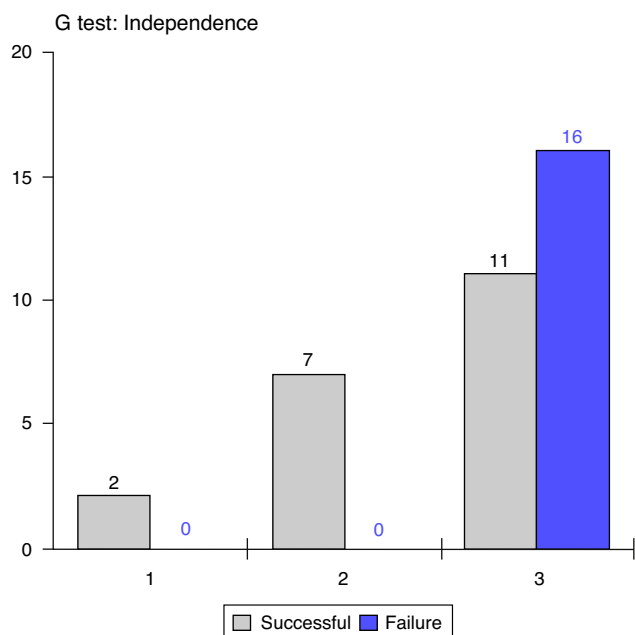


**Figure 5** Correlation between patient age and success of balloon laryngoplasty.



**Figure 6** Correlation between the presence of tracheostomy and successful balloon laryngoplasty ( $p = 0.0005$ ).

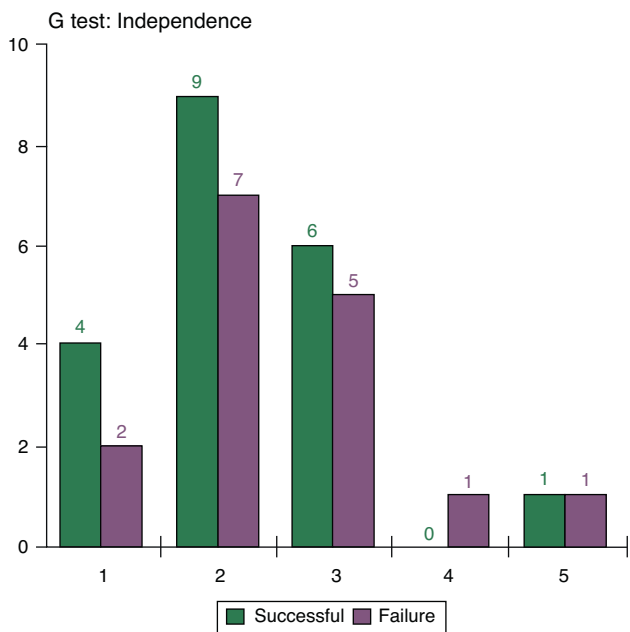




**Figure 7** Correlation between the degree of stenosis according to Myer-Cotton and failures of balloon laryngoplasty ( $p=0.0015$ ).

death cannot be ignored – inside and especially outside the hospital. Thus, as was demonstrated in this study, balloon laryngoplasty, besides being an excellent option for children with acute SGS, could prevent a large number of tracheostomies which are unfortunately performed in the pediatric population, particularly during and after hospitalizations in ICUs.

Even after performing a tracheotomy, the inflammation generated by the tracheal tube will heal, and considering that the respiratory condition was stabilized by the



**Figure 8** Correlation between the number of dilatations and balloon laryngoplasty success. No statistical significance.

tracheostomy, often the resulting scarring or stenosis will be ignored for weeks, months, or even years. In such cases, the stenosis will be diagnosed late. In these chronic cases, the therapeutic alternatives may involve endoscopic procedures or external surgeries. In the present study, it was found that even in chronic cases, the subglottic stenoses may be amenable to relatively less invasive treatments, such as balloon dilatation, although in this study the success rate in children with chronic SGS was only 32%. The results reported in the literature for balloon laryngoplasty do not discriminate among chronic and acute cases, but some authors<sup>8</sup> suggest that the results would not be good. According to the present results, in chronic stenosis cases there seems to be a relationship between time of stenosis progression and therapeutic success with balloon laryngoplasty. This seems to be more related to the degree of stenosis and to the characteristics of the scar. These data differ somewhat from those reported by Whigham et al.<sup>10</sup> In 2012, these authors<sup>10</sup> suggested that failure in the primary treatment of stenoses with balloon dilatation is related to other comorbidities in the airways, and found no relationship between therapeutic success and age of their children, degree of stenosis, and its characteristics (soft or fibrous), diverging from the findings of the present study, which observed better success rates for younger children and those with lower degrees of stenosis. Thin or laminar scars appear to be more prone to good results with balloon dilatation. This makes sense, since the thick and fibrotic cartilaginous framework of the larynx cannot be dilated. However, this is only an impression of the authors, and this finding has not been measured in the present study. In this study, the absence of prior tracheostomy had significant correlation with the success of the procedure. This finding may reflect the general health state of these children who, despite showing severe stenosis, had no significant comorbidities, in agreement with literature reports.<sup>10</sup>

Although in this study the failure of balloon dilatation occurred in 68% of children treated for chronic SGS, it is believed that even in cases where there is no possibility of stenosis and decannulation, the increase of the subglottic diameter at the cost of mucosal scar tissue dilatation often allows vocalization. The possibility of vocal emission and communication significantly impact the quality of life of the patient and of their relatives, who often must wait for the control of comorbidities – which can take months and sometimes years – for programming an open reconstruction surgery.

The principal attractive feature of balloon laryngoplasty is the relative ease of its implementation and the possibility of its use even in severe stenosis, considering the diminutive diameter of the balloon, which differentiates it from other forms of dilatation. This technique also does not exclude the possibility of an external reconstructive surgery in the case of failure; nor was it shown to cause an increase in the scarred area, hindering subsequent treatments that were performed in five children in this group. The success rates of balloon laryngoplasty for primary treatment of acquired SGS varies between 60%<sup>10</sup> and 100%<sup>11</sup> in the literature.<sup>8,12–14</sup> Recently, the group of Blanchard et al.<sup>13</sup> suggested even the primary treatment of congenital subglottic stenoses with this method.

However, the dilatation of non-tracheostomized children should be treated with care.<sup>15</sup> Spontaneous breathing

with the glottis obstructed by a balloon can lead to serious complications, such as pulmonary edema. Therefore, it is essential to involve the surgical team with the anesthesia team, so that spontaneous breathing and apneas are coordinated during the procedure – especially in non-tracheostomized children. Some children have extremely reactive airways, and edema of the supraglottic region may result in transient cough and dysphagia as clinical implications. Obstructive conditions, secondary to dilatation, were not found in this group, even among non-tracheostomized children. Transient dysphagia was observed in only three children, representing an 8% incidence of complications. This was considered a minor complication, as these were transient episodes. There were no other events or complications related to balloon laryngoplasty.

Currently, the main difficulties in laryngoplasty balloon procedures relate principally to the lack of standardization, mainly with regard to the number of dilatations. In the literature, there is no standardization with respect to dilatation pressure, dilatation time, interval between dilatations, and use of molds and of topical or injectable medications. The authors' impression is that the inflation pressure and the duration of balloon inflation should be adjusted to each patient, depending on the observation of reactive edema. The balloons used have an indication of maximum diameter with respect to a certain pressure; therefore, to exceed the prescribed pressure does not increase the expansion of the airway, but only increases the risk of balloon breakage, rendering new inflations impossible. Usually, the authors agree that the balloon should be inflated at least twice in each procedure.

An extremely interesting finding observed in this series was the lack of correlation between success rate and number of dilatations. Considerable common sense is called for in order to avoid performing unnecessary procedures and the creation of false expectations of therapeutic success for the child and his/her family. Video documentation and serial calibration of the airway with tracheal tubes at the beginning and end of each procedure provide a little more objectivity to the follow-up of these cases. Furthermore, they allow the surgeon to actually materialize the benefits of intervention, and to determine when to stop this treatment and elect the reconstructive surgery most appropriate for the case.

## Conclusion

Balloon laryngoplasty can be considered as a first-line treatment in SGS, both acute and chronic. In acute cases, this procedure was 100% successful. In chronic cases the benefits, even partial, were free of significant complications, without prejudice to future reconstructive surgeries.

The predictive factors of success in this study were: presence of acute stenosis, dilatation at an early age, dilatation

in the absence of prior tracheostomy, and less severe (grade I and II) stenoses.

## Conflicts of interest

The authors declare no conflicts of interest.

## References

- Gould JB, Benitz WE, Liu H. Mortality and time to death in very low birth weight infants: California, 1987 and 1993. *Pediatrics*. 2000;105:E37.
- Fraga JC, de Souza JCK, Krueel J. Pediatric tracheostomy. *J Pediatr (Rio J)*. 2009;85:97–103.
- Lang M, Brietzke SE. A systematic review and meta-analysis of endoscopic balloon dilation of pediatric subglottic stenosis. *Otolaryngol Head Neck Surg*. 2014;150:174–9.
- Monnier P, editor. *Pediatric airway surgery*. Heidelberg: Springer; 2010.
- Hebra A, Powell DD, Smith CD, Othersen HB. Balloon tracheoplasty in children: results of a 15-year experience. *J Pediatr Surg*. 1991;26:95761.
- Myer CM, O'Connor DM, Cotton RT. Proposed grading system for subglottic stenosis based on endotracheal tube sizes. *Ann Otol Rhinol Laryngol*. 1994;103:319–23.
- Schweiger C, Smith MM, Kuhl G, Manica D, Marostica PJC. Balloon laryngoplasty in children with acute subglottic stenosis: experience of a tertiary-care hospital. *Braz J Otorhinolaryngol*. 2011;77:711–5.
- Durden F, Sobol SE. Balloon laryngoplasty as a primary treatment for subglottic stenosis. *Arch Otolaryngol Head Neck Surg*. 2007;133:772–5.
- Avelino M, Fernandes E. Balloon laryngoplasty for subglottic stenosis caused by orotracheal intubation at a tertiary care pediatric hospital. *Int Arch Otorhinolaryngol*. 2013 [Epub ahead of print].
- Whigham AS, Howell R, Choi S, Peña M, Zalzal G, Preciado D. Outcomes of balloon dilation in pediatric subglottic stenosis. *Ann Otol Rhinol Laryngol*. 2012;121:442–8.
- Guarisco JL, Yang CJ. Balloon dilation in the management of severe airway stenosis in children and adolescents. *J Pediatr Surg*. 2013;48:1676–81.
- Hautefort C, Teissier N, Viala P, Van Den Abbeele T. Balloon dilation laryngoplasty for subglottic stenosis in children: eight years' experience. *Arch Otolaryngol Head Neck Surg*. 2012;138:235–40.
- Blanchard M, Leboulanger N, Thierry B, Blancal J-P, Glynn F, Denoyelle F, et al. Management specificities of congenital laryngeal stenosis: external and endoscopic approaches. *Laryngoscope*. 2013 [Epub ahead of print].
- Collins WO, Kalantar N, Rohrs HB, Silva RC. The effects of balloon dilation laryngoplasty in children with congenital heart disease. *Arch Otolaryngol Head Neck Surg*. 2012;138:1136–40.
- Gungor A. Balloon dilation of the pediatric airway: potential for disaster. *Am J Otolaryngol*. 2012;33:147–9.